This is a digital copy of a book that was preserved for generations on library shelves before it was carefully scanned by Google as part of a project to make the world's books discoverable online.

It has survived long enough for the copyright to expire and the book to enter the public domain. A public domain book is one that was never subject to copyright or whose legal copyright term has expired. Whether a book is in the public domain may vary country to country. Public domain books are our gateways to the past, representing a wealth of history, culture and knowledge that's often difficult to discover.

Marks, notations and other marginalia present in the original volume will appear in this file - a reminder of this book's long journey from the publisher to a library and finally to you.

Usage guidelines

Google is proud to partner with libraries to digitize public domain materials and make them widely accessible. Public domain books belong to the public and we are merely their custodians. Nevertheless, this work is expensive, so in order to keep providing this resource, we have taken steps to prevent abuse by commercial parties, including placing technical restrictions on automated querying.

We also ask that you:

+ *Make non-commercial use of the files* We designed Google Book Search for use by individuals, and we request that you use these files for personal, non-commercial purposes.
+ *Refrain from automated querying* Do not send automated queries of any sort to Google's system: If you are conducting research on machine translation, optical character recognition or other areas where access to a large amount of text is helpful, please contact us. We encourage the use of public domain materials for these purposes and may be able to help.
+ *Maintain attribution* The Google "watermark" you see on each file is essential for informing people about this project and helping them find additional materials through Google Book Search. Please do not remove it.
+ *Keep it legal* Whatever your use, remember that you are responsible for ensuring that what you are doing is legal. Do not assume that just because we believe a book is in the public domain for users in the United States, that the work is also in the public domain for users in other countries. Whether a book is still in copyright varies from country to country, and we can't offer guidance on whether any specific use of any specific book is allowed. Please do not assume that a book's appearance in Google Book Search means it can be used in any manner anywhere in the world. Copyright infringement liability can be quite severe.

About Google Book Search

Google's mission is to organize the world's information and to make it universally accessible and useful. Google Book Search helps readers discover the world's books while helping authors and publishers reach new audiences. You can search through the full text of this book on the web at `http://books.google.com/`

SIG · SOC · OD
1859


1837
ARTES
VERITAS
SCIENTIA
LIBRARY OF THE
UNIVERSITY OF MICHIGAN
E PLURIBUS UNUM
TUEBOR
SI QUAERIS PENINSULAM AMOENAM
CIRCUMSPICE

610,5
0142
S8

OBSTETRICAL TRANSACTIONS.

VOL. XXXVIII.

TRANSACTIONS

OF THE

OBSTETRICAL SOCIETY

OF

LONDON.

VOL. XXXVIII.

FOR THE YEAR 1896.

WITH A LIST OF OFFICERS, FELLOWS, ETC.



EDITED BY
W. R. DAKIN, M.D., SENIOR SECRETARY,
AND
PERCY BOULTON, M.D.

LONDON:
LONGMANS, GREEN, AND CO.
1897.

PRINTED BY ADLARD AND SON, BARTHOLOMEW CLOSE, E.C.

OBSTETRICAL SOCIETY OF LONDON.

OFFICERS FOR 1897.

PRESIDENT.	CULLINGWORTH, CHARLES JAMES, M.D.
VICE-PRESIDENTS.	DUNCAN, WILLIAM, M.D. GALTON, JOHN H., M.D. HURRY, JAMIESON BOYD, M.A., M.D. (Reading). NESHAM, THOMAS CARGILL, M.D. (Newcastle-on-Tyne).
TREASURER.	POTTER, JOHN BAPTISTE, M.D.
CHAIRMAN OF THE BOARD FOR THE EXAMINATION OF MIDWIVES.	BOULTON, PERCY, M.D.
HONORARY SECRETARIES.	DAKIN, WILLIAM RADFORD, M.D. PHILLIPS, JOHN, M.A., M.D.
HONORARY LIBRARIAN.	GRIFFITH, WALTER S. A., M.D.
EX-OFFICIO MEMBERS OF COUNCIL.	OLDHAM, HENRY, M.D. (*Trustee*). BARNES, ROBERT, M.D. (*Trustee*). HICKS, JOHN BRAXTON, M.D., F.R.S. PRIESTLEY, SIR WILLIAM O., M.D. WEST, CHARLES, M.D. PLAYFAIR, WILLIAM S., M.D. GERVIS, HENRY, M.D. CHAMPNEYS, FRANCIS HENRY, M.A., M.D.
OTHER MEMBERS OF COUNCIL.	ADAMS, THOMAS RUTHERFORD, M.D. (Croydon). DES VŒUX, HAROLD A., M.D. EDEN, THOMAS WATTS, M.D. FRASER, ANGUS, M.D. (Aberdeen). GANDY, WILLIAM. HANDFIELD-JONES, MONTAGU, M.D. KANTHACK, ALFREDO ANTUNES, M.D. KISCH, ALBERT. McCANN, FREDERICK JOHN, M.B., C.M. NICHOLSON, ARTHUR, M.B. (Brighton). PEDLER, GEORGE HENRY. PINHORN, RICHARD (Dover). POLLOCK, WILLIAM RIVERS, M.B., B.C. ROBERTS, CHARLES HUBERT, M.D. ROUTH, AMAND, M.D. TATE, WALTER W. H., M.D. THOMPSON, JOSEPH (Nottingham). WALTERS, JOHN, M.B. (Reigate).

LIST OF PAST PRESIDENTS OF THE SOCIETY.

1859 EDWARD RIGBY, M.D.
1861 WILLIAM TYLER SMITH, M.D.
1863 HENRY OLDHAM, M.D.
1865 ROBERT BARNES, M.D.
1867 JOHN HALL DAVIS, M.D.
1869 GRAILY HEWITT, M.D.
1871 JOHN BRAXTON HICKS, M.D., F.R.S.
1873 EDWARD JOHN TILT, M.D.
1875 SIR WILLIAM OVEREND PRIESTLEY, M.D.
1877 CHARLES WEST, M.D.
1879 WILLIAM S. PLAYFAIR, M.D.
1881 J. MATTHEWS DUNCAN, M.D., F.R.S.
1883 HENRY GERVIS, M.D.
1885 JOHN BAPTISTE POTTER, M.D.
1887 JOHN WILLIAMS, M.D.
1889 ALFRED LEWIS GALABIN, M.D.
1891 JAMES WATT BLACK, M.D.
1893 G. ERNEST HERMAN, M.B.
1895 F. H. CHAMPNEYS, M.A., M.D.

REFEREES OF PAPERS FOR THE YEAR 1897

APPOINTED BY THE COUNCIL.

BLACK, J. WATT, M.D.
BOULTON, PERCY, M.D.
CHAMPNEYS, F. H., M.A., M.D.
DORAN, ALBAN.
DUNCAN, W., M.D.
GALABIN, ALFRED LEWIS, M.A., M.D.
GERVIS, HENRY, M.D.
HERMAN, G. ERNEST, M.B
HORROCKS, PETER, M.D.
LAWRENCE, A. E. AUST, M.D., Bristol.
MALINS, EDWARD, M.D., Birmingham.
MEREDITH, W. A., M.B., C.M.
POTTER, JOHN BAPTISTE, M.D.
PRIESTLEY, SIR WILLIAM O., M.D.
STEPHENSON, WILLIAM, M.D., Aberdeen.
SPENCER, H. R., M.D.
SUTTON, J. BLAND.
WILLIAMS, SIR JOHN, BART., M.D.

STANDING COMMITTEES.

BOARD FOR THE EXAMINATION OF MIDWIVES.

CHAIRMAN. BOULTON, PERCY, M.D.

SPENCER, H. R., M.D.
LEWERS, ARTHUR H. N., M.D.
REMFRY, LEONARD, M.D.

EX-OFFICIO.
- CULLINGWORTH, CHAS. JAMES, M.D., — *President.*
- DAKIN, W. R., M.D., — *Hon. Secs.*
- PHILLIPS, J., M.A., M.D. — *Hon. Secs.*

LIBRARY COMMITTEE.

DORAN, ALBAN.
HERMAN, G. ERNEST, M.B.
TAIT, EDWARD S., M.D.

EX-OFFICIO.
- CULLINGWORTH, CHAS. JAMES, M.D., — *President.*
- POTTER, JOHN B., M.D., *Treasurer.*
- DAKIN, W. R., M.D., — *Hon. Secs.*
- PHILLIPS, J., M.A., M.D. — *Hon. Secs.*
- GRIFFITH, W. S. A., M.D., *Hon. Lib.*

PUBLICATION COMMITTEE.

BLACK, J. WATT, M.D.
CHAMPNEYS, FRANCIS HENRY, M.A., M.D.
HERMAN, G. ERNEST, M.B.
PLAYFAIR, WILLIAM S., M.D.
POTTER, JOHN BAPTISTE, M.D.
WILLIAMS, SIR JOHN, BART., M.D.

EX-OFFICIO.
- CULLINGWORTH, CHAS. JAMES, M.D., — *President.*
- BOULTON, PERCY, M.D., *Editor.*
- DAKIN, W. R., M.D., — *Hon. Secs.*
- PHILLIPS, J., M.A., M.D., — *Hon. Secs.*

HONORARY LOCAL SECRETARIES.

JONES, EVAN	Aberdare.
GOSS, T. BIDDULPH	Bath.
SHARPIN, HENRY W.	Bedford.
MALINS, EDWARD, M.D.	Birmingham.
FURNER, WILLOUGHBY	Brighton.
RIGDEN, GEORGE	Canterbury.
LAWRENCE, A. E. AUST, M.D.	Clifton.
BRAITHWAITE, JAMES, M.D.	Leeds.
THOMPSON, JOSEPH	Nottingham.
WALKER, THOMAS JAMES, M.D.	Peterborough.
WALTERS, JAMES HOPKINS	Reading.
KEELING, JAMES HURD, M.D.	Sheffield.
BURD, EDWARD, M.D., C.M.	Shrewsbury.
BRANFOOT, ARTHUR MUDGE, M.B.	Madras.
PERRIGO, JAMES, M.D.	Montreal, Canada.
TAKAKI, KANAHEIRO	Japan.

OBSTETRICAL SOCIETY OF LONDON.

TRUSTEES OF THE SOCIETY'S PROPERTY.

HENRY OLDHAM, M.D.
ROBERT BARNES, M.D.

HONORARY FELLOWS.

BRITISH SUBJECTS.

Elected

1892 LISTER, The Right Honorable LORD, F.R.S., LL.D., 12, Park crescent, Portland place, W.

1892 TURNER, SIR WILLIAM, F.R.S., Professor of Anatomy, University of Edinburgh ; 6, Eton terrace, Edinburgh.

1870 WEST, CHARLES, M.D., F.R.C.P., Foreign Associate of the Academy of Medicine of Paris ; 4, Evelyn mansions, Carlisle place, Victoria street, S.W. *Pres.* 1877-8.

1896 HICKS, JOHN BRAXTON, M.D., F.R.C.P., F.R.S., Consulting Obstetric Physician to Guy's and St. Mary's Hospitals ; The Brackens, Lymington, Hants. *Council*, 1861-2, 1869. *Hon. Sec.* 1863-5. *Vice-Pres.* 1866-8. *Treas.* 1870. *Pres.* 1871-2. *Trans.* 40.

FOREIGN SUBJECTS.

1895 GUSSEROW, Professor, Berlin.

1866 LAZAREWITCH, J., M.D., Professor Emeritus and Physician to the Maximilian Hospital ; Spaskaja, 2, St. Petersburg. *Trans.* 3.

Elected

1862 LUSK, WILLIAM THOMPSON, M.D., Professor of Obstetrics, Bellevue Hospital Medical College, New York.

1891 TARNIER, STÉPHANE, M.D., Professor of Obstetrics, Faculté de Médecine de Paris; 15, Rue Duphot, Paris.

1872 THOMAS, T. GAILLARD, M.D., Professor of Obstetrics in the College of Physicians and Surgeons; 600, Madison avenue, New York.

1862 VIRCHOW, RUDOLF, M.D., Professor of Pathological Anatomy in the University of Berlin.

1895 VON WINCKEL, Professor, Sonnenstrasse 16A, Munich.

CORRESPONDING FELLOWS.

1873 MARTIN, A. E., M.D., Berlin. *Trans.* 1.

1876 BUDIN, P., M.D., 129, Boulevard St. Germain, Paris. *Trans.* 1.

1876 CHADWICK, JAMES R., M.A., M.D., Physician for Diseases of Women, Boston City Hospital; Clarendon street, Boston, Massachusetts, U.S.

ORDINARY FELLOWS.

1897.

Those marked thus (*) have paid the Composition Fee in lieu of further annual subscriptions.

Those marked thus (†) reside beyond the London Postal District.

The letters O.F. are prefixed to the names of the "Original Fellows" of the Society.

Elected

1890† ACKERLEY, RICHARD, M.B., B.S.Oxon., Croft House, The Hill, Surbiton.

1891 ADAMS, CHARLES EDMUND, 227, Gipsy road, West Norwood, S.E.

1884† ADAMS, THOMAS RUTHERFORD, M.D., 119, North End, West Croydon. *Council*, 1894-7.

1890 ADDINSELL, AUGUSTUS W., M.B., C.M.Edin., 30, Ashburn place, South Kensington, S.W.

1895† ALBRECHT, JOHN ADOLPH, L.R.C.P. & S.Edin., 343, The Cliff, Lower Broughton road, Manchester.

1893† ALCOCK, RICHARD, M.B., Burlington crescent, Goole.

1883*†ALLAN, ROBERT JOHN, L.R.C.P.Ed., The Bungalow, Dulwich hill, Sydney, New South Wales.

1890† ALLAN, THOMAS S., L.R.C.P. & S.Ed., 13, Queen's road, Coventry.

1873† ALLEN, HENRY MARCUS, F.R.C.P.Ed., 20, Regency square, Brighton.

1887 AMBROSE, ROBERT, B.A., L.R.C.P. & S.Ed., 1, Mount place, Whitechapel road, E.

1875 ANDERSON, JOHN FORD, M.D., C.M., 41, Belsize park, N.W. *Council*, 1882.

1859 ANDREWS, JAMES, M.D., 1, Prince Arthur road, Hampstead, N.W. *Council*, 1881.

1870*†APPLETON, ROBERT CARLISLE, The Bar House, Beverley.

1884 APPLETON, THOMAS A., 46, Britannia road, Fulham, S.W.

1883† ARCHIBALD, JOHN, M.D., 2, The Avenue, Beckenham.

Elected

1871 ARGLES, FRANK, L.R.C.P.Ed., Hermon Lodge, Wanstead, Essex, E. *Council*, 1886-7.

1888† ARMSTRONG, JAMES, M.B. Edin., 84, Rodney street, Liverpool.

1895 ARNOLD, EDWIN GILBERT EMERSON, L.R.C.P.Lond., 5, Normand Mansions, Normand road, West Kensington, W.

1886 ASHE, WILLIAM PERCY, L.R.C.P. Lond., 23, Cadogan gardens, S.W.

1892† ASHWORTH, JAMES HENRY, M.D. St. And., Halstead, Essex.

1887 BAILEY, HENRY FREDERICK, The Hollies, Lee terrace, Lee, S.E.

1887 BAKER, OSWALD, L.R.C.P. & S. Ed., Surgeon-Major, 57, Welbeck street, W.

1880† BALLS-HEADLEY, WALTER, M.D., F.R.C.P., 4, Collins street east, Melbourne, Victoria.

1869* BANTOCK, GEORGE GRANVILLE, M.D., Surgeon to the Samaritan Free Hospital; 12, Granville place, Portman square, W. *Council*, 1874-6. *Trans.* 2.

1893† BARBER, RICHARD HENRY, L.R.C.P. & S.Edin., 505, Williams avenue, Albina, Portland, Oregon, U.S.A.

1886*†BARBOUR, A. H. FREELAND, M.D.Edin., 4, Charlotte square, Edinburgh.

O.F.* BARNES, ROBERT, M.D., F.R.C.P., Consulting Obstetric Physician to St. George's Hospital; 7, Queen Anne street, Cavendish square, W. *Vice-Pres.* 1859-60. *Council*, 1861-2, 1867. *Treas.* 1863-4. *Pres.* 1865-6. *Trans.* 32. *Trustee.*

1884† BARRACLOUGH, ROBERT W. S., M.D., Cleveland, Beer Alston, South Devon.

1896 BARRETT, SIDNEY EDWARD, M.B., B.C.Cantab., 100, Bethune road, Stamford hill, N.

1886† BARRINGTON, FOURNESS, M.B. Edin., F.R.C.S. Eng., 30, Bayswater road, Sydney, New South Wales.

Elected

1894† BARTLETT, HEDLEY C., L.R.C.P.Lond., High street, Saffron Walden.

1891 BARTON, EDWIN ALFRED, L.R.C.P.Lond., 35, Cheniston Gardens, Kensington, W.

1887 BARTON, HENRY THOMAS, 61, Harford street, E.

1887† BARTON, WILLIAM EDWIN, L.R.C.P. Lond., Staunton-on-Wye, near Hereford.

1861*†BARTRUM, JOHN S., F.R.C.S., Surgeon to the Bath General Hospital; 13, Gay street, Bath. *Council*, 1877-9.

1893† BATCHELOR, FERDINAND CAMPION, M.D. Durh., Dunedin, New Zealand.

1873 BATE, GEORGE PADDOCK, M.D., 412, Bethnal Green road, N.E.; and 2, Northumberland Houses, King Edward road, Hackney. *Council*, 1882-4.

1895† BEACHCROFT, FRANCIS SEWARD, L.R.C.P.Lond., 5, London street, New Swindon, Wilts.

1871 BEADLES, ARTHUR, Park House, Dartmouth Park, Forest hill, S.E.

1892 BEAUCHAMP, SYDNEY, M.B., B.C.Cantab., 146, Cromwell road, S.W.

1896 BELBEN, FRANK, M.B., F.R.C.S., St. Bartholomew's Hospital, E.C.

1866*†BELCHER, HENRY, M.D., 28, Cromwell road, West Brighton.

1871*†BELL, ROBERT, M.D. Glasg., 29, Lynedoch street, Glasgow.

1893† BENJAFIELD, WILLIAM BARNETT, M.B., C.M.Edin., Bletchenden, Lower Edmonton.

1889† BENSON, MATTHEW, M.D.Brux., 35, Dicconson street, Wigan.

1894 BERKELEY, GEORGE A. H. C., B.A., M.B., B.C.Cantab., 72, Belgrave road, S.W.

1893† BERRIDGE, WILLIAM ALFRED, Oakfield, Redhill.

1883† BERTOLACCI, J. HEWETSON, Beaufort House, Knaphill, Surrey.

1889† BEST, WILLIAM JAMES, 1, Cambridge terrace, Dover.

Elected

1893*†BETENSON, WILLIAM BETENSON, L.R.C.P.Lond., Bungay, Suffolk.

1894* BETENSON, WOODLEY DANIEL, L.R.C.P.Lond., 26, Caversham road, N.W.

1891† BEVILLE, FREDERICK WELLS, L.R.C.P.Lond., The Firs, Palace road, East Molesey.

1887*†BIDEN, CHARLES WALTER, L.R.C.P.Lond., Laxfield, Framlingham.

1879 BIGGS, J. M., Hillside, Child's hill, N.W.

1889† BISSHOPP, FRANCIS ROBERT BRYANT, M.A., M.B., B.C.Cantab., Belvedere, Mount Pleasant, Tunbridge Wells.

1890† BLACK, GEORGE, M.B., B.S.Lond., Hurstpierpoint, Hassocks, Sussex.

1868* BLACK, JAMES WATT, M.A., M.D., F.R.C.P., Obstetric Physician to the Charing Cross Hospital; 15, Clarges street, Piccadilly, W. *Council*, 1872-4. *Vice-Pres.* 1885-6. *Chairman, Board Exam. Midwives*, 1887-90. *Pres.* 1891-2.

1893 BLACKER, GEORGE FRANCIS, M.D., B.S.Lond., F.R.C.S., Assistant Obstetric Physician to University College Hospital; 20, Weymouth street, W. *Trans.* 1.

1861*†BLAKE, THOMAS WILLIAM, M.D.St.And., Hurstbourne, Bournemouth, Hants.

1872*†BLAND, GEORGE, Consulting Surgeon to the Macclesfield Infirmary; Pottergate Lodge, Lincoln.

1894 BODILLY, REGINALD THOMAS H., L.R.C.P.Lond., Woodbury, High road, South Woodford.

1892 BOND, WILLIAM ARTHUR, M.A., M.D., B.S.Cantab., 10, Gray's Inn place, Gray's Inn, W.C.

1883 BONNEY, WILLIAM AUGUSTUS, M.D., 100, Elm park gardens, Chelsea, S.W.

1894† BORCHERDS, WALTER MEENT, M.R.C.S., L.R.C.P., Worcester, Cape Colony.

Elected

1893† BOSWELL, HENRY ST. GEORGE, M.B. Edin., High street, Saffron Walden.

1866* BOULTON, PERCY, M.D., Physician to the Samaritan Free Hospital; 15, Seymour street, Portman square, W. *Council*, 1878-80, 1885, 1896. *Hon. Lib.* 1886. *Hon. Sec.* 1886-9. *Vice-Pres.* 1890-2. *Board Exam. Midwives*, 1890-1. *Chairman*, 1897. *Editor*, 1894-7. *Trans.* 4.

1886† BOUSTEAD, ROBINSON, M.D., B.C. Cantab., Surgeon-Lieutenant-Colonel, Indian Army; c/o Messrs. H. S. King and Co., 45, Pall Mall, S.W.

1877 BOWKETT, THOMAS EDWARD, 145, East India road, Poplar, E. *Council*, 1890.

1884* BOXALL, ROBERT, M.D.Cantab., Assistant Obstetric Physician to, and Lecturer on Practical Midwifery at, the Middlesex Hospital; 29, Weymouth street, Portland place, W. *Council*, 1888-90, 1894-5. *Board Exam. Midwives*, 1891-3. *Trans.* 11.

1884† BOYS, ARTHUR HENRY, L.R.C.P.Ed., Chequer Lawn, St. Albans.

1894 BRABANT, ROBERT HERBERT W. HUGHES, L.R.C.P.Lond., 137, High road, Lee, S.E.

1886† BRADBURY, HARVEY K., 181, Horninglow street, Burton-on-Trent.

1894† BRADFORD, ANDREW, M.D., C.M., Toronto, Lanark, Ontario, Canada.

1877† BRADLEY, MICHAEL MCWILLIAMS, M.B., Jarrow-on-Tyne.

1873† BRAITHWAITE, JAMES, M.D., Obstetric Physician to the Leeds General Infirmary; Lecturer on Diseases of Women and Children at the Leeds School of Medicine; Little Woodhouse, Leeds. *Vice-Pres.* 1877-9. *Trans.* 6. *Hon. Loc. Sec.*

1880† BRANFOOT, ARTHUR MUDGE, M.B., Superintendent of the Government Lying-in Hospital, Madras, and Professor of Midwifery and Diseases of Women and Children in the Madras Medical College, Pantheon road, Madras. *Hon. Loc. Sec.* [care of Messrs. Woodhead & Co., 44, Charing Cross, S.W.]

Elected

1887 BRIDGER, ADOLPHUS EDWARD, M.D.Ed., 18, Portland place, W.

1888*†BRIGGS, HENRY, M.B., F.R.C.S., Surgeon to the Hospital for Women, and Hon. Med. Officer to the Lying-in Hospital, Liverpool; 3, Rodney street, Liverpool.

1864 BRIGHT, JOHN MEABURN, M.D., Alvaston, Park hill, Forest hill, S.E. *Council*, 1873-4.

1894 BRINTON, ROLAND DANVERS, B.A., M.D.Cantab., 8, Queen's Gate terrace, S.W.

1869 BRISBANE, JAMES, M.D., 16, St. John's Wood road, N.W.

1885† BRISCOE, JOHN FREDERICK, Westbrooke House, Alton, Hants.

1887† BRODIE, FREDERICK CARDEN, M.B., Westmount, Sandown, Isle of Wight.

1866 BRODIE, GEORGE B., M.D., Consulting Physician-Accoucheur to Queen Charlotte's Lying-in Hospital; 3, Chesterfield street, Mayfair, W. *Council*, 1873-5. *Vice-Pres.*, 1889.

1892 BRODIE, WILLIAM HAIG, M.D., C.M.Edin., F.R.C.S.Eng., Battle, Sussex.

1876 BROOKHOUSE, CHARLES TURING, M.D., 43, Manor road, Brockley, S.E.

1889† BROWN, ALFRED, M.A., M.D., C.M. Aber., Claremont, Higher Broughton, Manchester.

1868 BROWN, ANDREW, M.D. St. And., 1, Bartholomew road, Kentish town, N.W. *Council*, 1893-4. *Trans.* 1.

1894 BROWN, DAVID, M.D.Lond., Hamdon, Taunton.

1865* BROWN, D. DYCE, M.D., 29, Seymour street, Portman square, W.

1896 BROWN, JOHN LEWIS, M.B., C.M.Edin., 86, Windsor road, Forest gate, E.

1889*†BROWN, WILLIAM CARNEGIE, M.D. Aber., Penang, China.

1876 BRUNJES, MARTIN, 33A, Gloucester place, Portman square, W.

Elected

1895† BUCKLEY, SAMUEL, M.D.Lond., F.R.C.S.Eng., 2, Ebor villas, Broughton park, Manchester.

1883 BUKSH, RAHEEM, The Hall, Plaistow, E.

1885*†BUNNY, J. BRICE, L.R.C.P. Ed., Warre House, Bishops Lydeard, Taunton.

1877† BURD, EDWARD, M.D., M.C., Senior Physician to the Salop Infirmary; Newport House, Shrewsbury. *Council*, 1886-7. *Hon. Loc. Sec.*

1891† BURGESS, EDWARD ARTHUR, Thorncombe, near Chard.

1894 BURT, ROBERT FRANCIS, M.B., C.M.Edin., 124, Stroud Green road, N.

1888 BURTON, HERBERT CAMPBELL, L.R.C.P. Lond., Lee Park Lodge, Blackheath, S.E.

1878 BUTLER-SMYTHE, ALBERT CHARLES, L.R.C.P.Ed., 76, Brook street, Grosvenor square, W. *Council*, 1889-91.

1887* BUXTON, DUDLEY W., M.D. Lond., 82, Mortimer street, Cavendish square, W.

1886† BYERS, JOHN W., M.D., Professor of Midwifery and Diseases of Women and Children at Queen's College, and Physician for Diseases of Women to the Royal Hospital, Belfast; Lower crescent, Belfast.

1891† CALTHROP, LIONEL C. EVERARD, M.B. Durh., 11, Ellison place, Newcastle-on-Tyne.

1887† CAMERON, JAMES CHALMERS, M.D., Professor of Midwifery and Diseases of Infancy, McGill University; 941, Dorchester street, Montreal.

1887† CAMERON, MURDOCH, M.D.Glas., Regius Professor of Midwifery in the University of Glasgow, 7, Newton terrace, Charing Cross, Glasgow.

1894† CAMPBELL, JOHN, M.A., M.D.Dubl., F.R.C.S., 21, Great Victoria street, Belfast.

1892 CAMPBELL, JOHN WILLIAM, B.A., M.B., B.Ch.Cantab., Highclere, Oakleigh park, Whetstone, N. (*Winter*, Casa Rossa, Mentone.)

Elected

1888*†CAMPBELL, WILLIAM MACFIE, M.D. Edin., 1, Princes gate East, Liverpool.

1886† CARPENTER, ARTHUR BRISTOWE, M.A., M.B. Oxon., Wykeham House, Bedford park, Croydon.

1896 CARRÉ, LOUIS J. E., M.D., 16, Bryanston street, Portman square, W.

1872 CARTER, CHARLES HENRY, M.D., Physician to the Hospital for Women, Soho square; 45, Great Cumberland place, Hyde park, W. *Council*, 1880-2. *Trans.* 4.

1890 CARTER, ROBERT JAMES, M.B.Lond., 57, Acacia road, N.W.

1887† CASE, WILLIAM, Denmark house, Caister-on-Sea, Norfolk.

1863† CAYZER, THOMAS, Surgeon-Lieutenant-Colonel, Mayfield, 9, Aigburth road, Liverpool.

1875† CHAFFERS, EDWARD, F.R.C.S., Broomfield, Keighley, Yorkshire.

1894 CHALDECOTT, JOHN HENRY, L.R.C.P.Lond., 401, Old Kent road, S.E.

1876* CHAMPNEYS, FRANCIS HENRY, M.A., M.D. Oxon., F.R.C.P., Physician-Accoucheur to, and Lecturer on Midwifery at, St. Bartholomew's Hospital; 42, Upper Brook street, W. *Council*, 1880-1. *Hon. Lib.* 1882-3. *Hon. Sec.* 1884-7. *Vice-Pres.* 1888-90. *Board Exam. Midwives*, 1883, 1888-90; *Chairman*, 1891-5. *Editor*, 1888-93. *Pres.* 1895-6. *Trans.* 16.

1867*†CHARLES, T. EDMONDSTOUNE, M.D., F.R.C.P., 72, Via di San Niccolò da Tolentino, Rome. *Council*, 1882-4.

1874*†CHARLESWORTH, JAMES, M.D., Physician to the North Staffordshire Infirmary; 25, Birch terrace, Hanley, Staffordshire.

1886† CHARPENTIER, AMBROSE E. L., M.D.Durh., Rathmines House, Uxbridge.

1892† CHEPMELL, CHARLES WILLIAM JAMES, M.D. Brux., 87, Buckingham road, Brighton.

Elected

1890† CHILDE, CHARLES PLUMLEY, B.A., F.R.C.S., Cranleigh, Kent road, Southsea.

1863*†CHISHOLM, EDWIN, M.D., Abergeldie, Ashfield, near Sydney, New South Wales. [Per Messrs. Turner and Henderson, care of Messrs. W. Dawson, 121, Cannon street, E.C.]

1896 CHITTENDEN, T. HILLIER, L.R.C.P.Lond., 32, Ovington square, S.W.

1883 CLAPHAM, EDWARD, M.D., 29, Lingfield road, Wimbledon. *Council*, 1892-4.

1859 CLAREMONT, CLAUDE CLARKE, Millbrook House, 1, Hampstead road, N.W. *Council*, 1896.

1897 CLARK, WILLIAM GLADSTONE, M.A.Cantab., St. Bartholomew's Hospital, E.C.

1879 CLARKE, REGINALD, South Lodge, Lee park, Lee, S.E.

1893 CLARKE, W. BRUCE, F.R.C.S., 46, Harley street, W.

1889 CLEMOW, ARTHUR HENRY WEISS, M.D., C.M. Edin., 101, Earl's Court road, Kensington, W.

O.F. CLEVELAND, WILLIAM FREDERICK, M.D., Stuart villa, 199, Maida vale, W. *Council*, 1863-4. *Vice-Pres.* 1875-7, 1887-9. *Trans.* 1.

1865*†COATES, CHARLES, M.D., Physician to the Bath General and Royal United Hospitals; 10, Circus, Bath.

1882† COATES, FREDERICK WILLIAM, M.D., Auckland, New Zealand. *Council*, 1891-3.

1875 COFFIN, RICHARD JAS. MAITLAND, F.R.C.P. Ed., 3, Westgate terrace, Redcliffe square, S.W.

1878 COFFIN, THOMAS WALKER, 22, Upper Park road, Haverstock hill, N.W.

1875*†COLE, RICHARD BEVERLY, M.D. Jefferson Coll. Philad., 218, Post street, San Francisco, California, U.S.

1895† COLES, ALFRED CHARLES, M.D., C.M.Edin., Rivoli, Grosvenor road, Bournemouth.

Elected

1895 COLLIER, SAMUEL RUDDELL, M.D., 13, Hartfield road, Wimbledon.

1888† COLLINS, EDWARD TENISON, 12, Windsor place, Cardiff.

1877 COLMAN, WALTER TAWELL (travelling).

1866† COOMBS, JAMES, M.D., Bedford.

1888 COOPER, PETER, L.R.C.P.Lond., Stainton Lodge, 35, Shooter's Hill road, Blackheath, S.E.

1890 COPELAND, WILLIAM HENRY LAURENCE, M.B.Cantab., 59, Warwick road, Earl's Court, S.W.

1888† CORBY, HENRY, B.A., M.D., 19, St. Patrick's place, Cork.

1875*†CORDES, AUG., M.D., M.R.C.P., Consulting Accoucheur to the "Miséricorde;" Privat Docent for Midwifery at the University of Geneva; 12, Rue Bellot, Geneva. *Trans.* 1.

1883 CORNER, CURSHAM, 113, Mile End road, E.

1888† CORNISH, CHARLES NEWTON, L.R.C.P. Ed., 4, Southwick place, Hyde park, W.

1875 CORY, ROBERT, M.D., Assistant Obstetric Physician to St. Thomas's Hospital; 73, Lambeth Palace road, S.E. *Council*, 1879-81, 1884-5. *Vice-Pres.* 1887-88. *Trans.* 1.

1886† COX, JOSHUA JOHN, M.D. Ed., St. Ronan's, Clarendon road, Eccles, Manchester.

1869† COX, RICHARD, M.D. St. And., Theale, near Reading. *Trans.* 1.

1877 CRAWFORD, JAMES, M.D. Durh., Grosvenor Mansions, 80, Victoria street, S.W.

1881† CREASY, JAMES GIDEON, West House, Wrotham, Kent.

1896† CREASY, ROLF, L.R.C.P. Lond., Windlesham, Surrey.

1876† CREW, JOHN, Manor House, Higham Ferrers, Northamptonshire.

1893 CRIPPS, WILLIAM HARRISON, F.R.C.S., 2, Stratford place, W. *Trans.* 1.

Elected

1889† CROFT, EDWARD OCTAVIUS, L.R.C.P. Lond., 8, Clarendon road, Leeds.

1881*†CRONK, HERBERT GEORGE, M.B. Cantab., Repton, near Burton-on-Trent.

1893 CROSBY, HERBERT THOMAS, M.A., M.B., B.C.Cantab., 19, Gordon square, W.C.

1895 CROSS, ERNEST, L.R.C.P.Lond., St. Bartholomew's Hospital, E.C.

1886*†CROSS, WILLIAM JOSEPH, M.B., Horsham, Victoria, Australia.

1889† CROUCH, EDWARD THOMAS, Stoke House, Gosport.

1875* CULLINGWORTH, CHARLES JAMES, M.D., D.C.L., F.R.C.P., Obstetric Physician to, and Lecturer on Obstetric Medicine at, St. Thomas's Hospital; 14, Manchester square, W. *Council*, 1883-5, 1891-3. *Vice-Pres.* 1886-8. *Board Exam. Midwives*, 1889-91. *Chairman*, 1895-6. *Pres.* 1897. *Trans.* 12.

1889*†CURSETJI, JEHÁNGIR J., M.D. Brux., 94, Chundunwádi, Bombay.

1894 CUTLER, LENNARD, L.R.C.P.Lond., 8, Gloucester road, S.W. *Trans.* 1.

1885 DAKIN, WILLIAM RADFORD, M.D., B.S., F.R.C.P., Obstetric Physician to, and Lecturer on Midwifery at, St. George's Hospital; 18, Grosvenor street, W. *Council*, 1889-91. *Hon. Lib.* 1892-3. *Hon. Sec.* 1894-7. *Trans.* 3.

1868 DALY, FREDERICK HENRY, M.D., 185, Amhurst road, Hackney Downs, N.E. *Council*, 1877-9. *Vice-Pres.* 1883-5. *Trans.* 2.

1882† DAMBRILL-DAVIES, WILLIAM R., Alderley Edge, Cheshire.

1893 DAUBER, JOHN HENRY, M.A. Oxon., L.R.C.P. Lond., 29, Charles street, Berkeley square, W.

1889 DAVIES, FREDERICK HENRY, M.B., C.M.Edin., 30, Camberwell green, S.E.

Elected

1884 DAVIES, JOHN, 87, Cambridge gardens, Ladbroke grove, W.

1892† DAVIS, ROBERT, Darrickwood, Orpington, Kent.

1895 DAVOREN, JOHN, L.R.C.P.I., C.M., 1, Wilmington square, W.C.

1877 DAVSON, SMITH HOUSTON, M.D., Campden villa, 203, Maida vale, W. *Council*, 1889-91.

1891 DAWSON, ERNEST, L.R.C.P.Lond., Linden House, High road, Leyton, E.

1889 DES VŒUX, HAROLD A., M.D.Brux., 4, Ashley gardens, Victoria street, S.W. *Council*, 1896-7.

1894 DICKINSON, THOMAS VINCENT, M.D. Lond., 33, Sloane street, S.W.

1894 DICKINSON, WILLIAM GILBERT, L.R.C.P. Lond., Thanet Lodge, Southfields, Wandsworth, S.W.

1894 DICKSON JOHN WILLIAM, B.A., M.B., B.C. Cantab., 3, Hertford street, W.

1895 DODGSON, GEORGE STANLEY, B.A., M.B., B.C.Cantab., Middlesex Hospital, W.

1886† DONALD, ARCHIBALD, M.D. Edin., M.R.C.P., Obstetric Physician to the Royal Infirmary, Manchester; Honorary Surgeon to St. Mary's Hospital for Women, Manchester; Platt Abbey, Rusholme, Manchester. *Council*, 1893-5. *Trans.* 1.

1879* DORAN, ALBAN H. G., F.R.C.S., Surgeon to the Samaritan Free Hospital; 9, Granville place, Portman square, W. *Council*, 1883-5. *Hon. Lib.* 1886-7. *Hon. Sec.* 1888-91. *Vice-Pres.* 1892-4. *Trans.* 16.

1890† DOUTY, EDWARD HENRY, M.A., M.B., B.C. Cantab., 69, Bridge street, Cambridge.

1887 DOVASTON, MILWARD EDMUND.

1896 DOWNES, J. LOCKHART, M.B., C.M. Edin., 27, Romford road, E.

1884† DOYLE, E. A. GAYNES, L.R.C.P., Colonial Hospital, Port of Spain, Trinidad.

Elected

1871† DRAKE-BROCKMAN, EDWARD FORSTER, F.R.C.S., L.R.C.P. Lond., Brigade-Surgeon; c/o Messrs. Richardson and Co., East India Army Agency, 25, Suffolk street, Pall Mall, S.W.]

1884 DRAKE, CHARLES HENRY, 204, Brixton hill, S.W.

1894† DREW, HENRY WILLIAM, F.R.C.S., Eastgate, East Croydon.

1883 DUNCAN, ALEXANDER GEORGE, M.B., 25, Amhurst park, Stamford hill, N.

O.F. DUNCAN, JAMES, M.B., 8, Henrietta street, Covent garden, W.C. *Council*, 1873-4. *Vice-Pres.* 1895.

1882 DUNCAN, WILLIAM, M.D., Obstetric Physician to, and Lecturer on Obstetric Medicine at, the Middlesex Hospital; 6, Harley street, W. *Council*, 1885-6, 1888-9. *Hon. Lib.* 1890-1. *Hon. Sec.* 1892-5. *Vice-Pres.* 1896-7. *Trans.* 2.

1893† DUNN, PHILIP HENRY, L.R.C.P. Lond., Stevenage, Herts.

1871* EASTES, GEORGE, M.B., F.R.C.S., 35, Gloucester place, Hyde park, W. *Council*, 1878-80.

1896 EASTON, FRANK EDWARD, L.R.C.P. Lond., 12, Devonport street, Hyde park, W.

1883† ECCLES, F. RICHARD, M.D., Professor of Gynæcology, Western University; 1, Ellwood place, Queen's avenue, London, Ontario, Canada.

1892 ECCLES, WILLIAM MCADAM, M.B., B.S.Lond., 10, Welbeck street, Cavendish square, W.

1893 EDEN, THOMAS WATTS, M.D., M.R.C.P. Edin., 6, Manchester square, W. *Council*, 1897. *Trans.* 3.

1890† EHRMANN, ALBERT, L.R.C.P.Lond., Bitterne, near Southampton.

1879† ELDER, GEORGE, M.D., C.M., Surgeon to the Samaritan Hospital for Women, Nottingham; 17, Regent street, Nottingham.

1878† ELLERY, RICHARD, L.R.C.P. Ed., Plympton, Devon.

Elected

1894 ELLIS, ROBERT KINGDON, M.B., B.Ch.Oxon., Westgate, Peterborough.

1873*†ENGELMANN, GEORGE JULIUS, A.M., M.D., 336, Beacon street, Boston, Mass., U.S.A.

1897 EVANS, EVAN LAMING, M.B., B.C.Cantab., 11, Gloucester terrace, Hyde park, W.

1892† EVANS, JOHN MORGAN, L.R.C.P.Lond., Llandrindod Wells, Radnorshire.

1875† EWART, JOHN HENRY, Eastney, Devonshire place, Eastbourne.

1894 FAIRWEATHER, DAVID, M.A., M.B., C.M.Edin., 2, Nightingale road, Wood Green, N.

1876† FARNCOMBE, RICHARD, 40, Belgrave street, Balsall heath, Birmingham.

1869 FARQUHAR, WILLIAM, M.D., Deputy Surgeon-General, 40, Westbourne gardens, Bayswater, W.

1861 FARR, GEO. F., L.R.C.P. Ed., Slade House, 175, Kennington road, S.E. *Council*, 1885.

1882† FARRAR, JOSEPH, M.D., Gainsborough. *Trans.* 1.

1894† FAZAN, CHARLES HERBERT, L.R.C.P. Lond., Belmont, Wadhurst, Sussex.

1868* FEGAN, RICHARD, M.D., Westcombe park, Blackheath, S.E.

1886 FENNELL, DAVID, L.K.Q.C.P.I., 20, Dalston lane, N.E.

1883 FENTON, HUGH, M.D., 27, George street, Hanover square, W.

1893 FERGUSON, GEORGE GUNNIS, M.B., C.M.Glas., 62, Holmdale road, West Hampstead, N.W.

1893† FINLEY, HARRY, M.D.Lond., Wimborne Minster, Dorset.

1892† FINNY, W. EVELYN ST. LAWRENCE, M.B. Dubl., Kenlis, Queen's road, Kingston hill.

1882† FITZGERALD, CHARLES EGERTON, M.D., West terrace, Folkestone.

1877*†FONMARTIN, HENRY DE, M.D., 26, Newberry terrace, Lower Bullar street, Nichols Town, Southampton.

Elected

1884† FORD, ALEXANDER, L.R.C.P. Ed., 9, Beresford street, Waterford.

1877*†FORD, JAMES, M.D., Rillside, Exmouth, Devon.

1884 FOURACRE, ROBERT PERRIMAN, 20, Tollington park, N.

1886† FOWLER, CHARLES OWEN, M.D., Cotford House, Thornton heath.

1875*†FRASER, ANGUS, M.D., Physician and Lecturer on Clinical Medicine to the Aberdeen Royal Infirmary; 232, Union street, Aberdeen. *Council*, 1897.

1888† FRASER, JAMES ALEXANDER, L.R.C.P. Lond., Western Lodge, Romford.

1867† FREEMAN, HENRY W., 24, Circus, Bath. *Council*, 1891-3.

1883 FULLER, HENRY ROXBURGH, M.D. Cantab., 45, Curzon street, Mayfair, W. *Council*, 1893. *Trans.* 1.

1886† FURNER, WILLOUGHBY, F.R.C.S., 13, Brunswick square, Brighton. *Council*, 1894-6. *Hon. Loc. Sec.*

1874* GALABIN, ALFRED LEWIS, M.A., M.D., F.R.C.P., Obstetric Physician to, and Lecturer on Midwifery at, Guy's Hospital; 49, Wimpole street, Cavendish square, W. *Council*, 1876-8. *Hon. Lib.* 1879. *Hon. Sec.* 1880-3. *Vice-Pres.* 1884. *Treas.* 1885-8. *Pres.* 1889-90. *Trans.* 12.

1888 GALLOWAY, ARTHUR WILTON, L.R.C.P. Lond., 79, New North road, N.

1863* GALTON, JOHN H., M.D., Chunam, Sylvan road, Upper Norwood, S.E. *Council*, 1874-6, 1891-2. *Vice-Pres.* 1895-7.

1881 GANDY, WILLIAM, Hill Top, Central hill, Norwood, S.E. *Council*, 1897.

1886† GARDE, HENRY CROKER, F.R.C.S. Edin., Maryborough, Queensland.

1887 GARDINER, BRUCE H. J., L.R.C.P. Ed., Gloucester House, Barry road, East Dulwich, S.E.

1894 GARDNER, H. BELLAMY, M.R.C.S., L.R.C.P.Lond., 11A, Welbeck street, W.

1879† GARDNER, JOHN TWINAME, Northfield House, Ilfracombe.

Elected

1872† GARDNER, WILLIAM, M.A., M.D., Professor of Gynæcology, McGill University; Gynæcologist to the Montreal General Hospital; 109, Union avenue, Montreal, Canada.

1892† GARDNER, WILLIAM, M.B., C.M.Glas., 5, Collins street, Melbourne.

1876† GARNER, JOHN, 21, Easy row, Birmingham.

1891† GARRETT, ARTHUR EDWARD, L.R.C.S., & L.M.Ed., The Limes, Rickmansworth.

1873*†GARTON, WILLIAM, M.D., F.R.C.S., Inglewood, Aughton, near Ormskirk.

1889* GELL, HENRY WILLINGHAM, M.A., M.B. Oxon., 43, Albion street, Hyde park, W.

1859* GERVIS, HENRY, M.D., F.R.C.P., Consulting Obstetric Physician to St. Thomas's Hospital; 40, Harley street, Cavendish square. *Council*, 1864-6, 1889-91, 1893. *Hon. Sec.* 1867-70. *Vice-Pres.* 1871-3. *Treas.* 1878-81. *Pres.* 1883-4. *Trans.* 8.

1866* GERVIS, FREDERICK HEUDEBOURCK, 1, Fellows road, Haverstock hill, N.W. *Council*, 1877-9. *Vice-Pres.* 1892. *Trans.* 1.

1884† GIBB, CHARLES JOHN, M.D., Westgate House, Newcastle-on-Tyne.

1875 GIBBINGS, ALFRED THOMAS, M.D., 93, Richmond road, Dalston, N.E. *Council*, 1885-6, 1888.

1883 GIBBONS, ROBERT ALEXANDER, M.D., Physician to the Grosvenor Hospital for Women and Children; 29, Cadogan place, S.W. *Council*, 1889-90. *Trans.* 1.

1894 GIBSON, HENRY WILKES, L.R.C.P. Lond., 11, College crescent, South Hampstead, N.W.

1874† GIBSON, JAMES EDWARD, Hillside, West Cowes, Isle of Wight.

1892 GILES, ARTHUR EDWARD, M.D. Lond., M.R.C.P., Physician to Out-patients, Chelsea Hospital for Women; 58, Harley street, Cavendish square, W. *Trans.* 5.

1869 GILL, WILLIAM, L.R.C.P. Lond., 11, Russell square, W.C.

1891 GIMBLETT, WILLIAM HENRY, L.R.C.P.I., 1, Pembury road, Clapton, N.E.

Elected

1891† GLEDDEN, ALFRED MAITLAND, M.D., c/o L. Bruck, 13, Castlereagh street, Sydney, N.S.W.

1894† GODDARD, CHARLES ERNEST, L.R.C.P. Lond., Wembley, Harrow.

1871 GODDARD, EUGENE, M.D. Durh., North Lynne, 106, Highbury New Park, N. *Trans.* 1.

1871 *GODSON, CLEMENT, M.D., C.M.; 9, Grosvenor street, W. *Council*, 1876-7. *Hon. Sec.* 1878-81. *Vice-Pres.* 1882-4. *Board Exam. Midwives*, 1877, 1882-86. *Trans.* 5.

1893† GOODMAN, ROGER NEVILLE, M.A., M.B.Cantab., Elmside, Kingston-on-Thames.

1893† GORDON, FREDERICK WILLIAM, L.R.C.P.Lond., Manukau road, Auckland, New Zealand.

1883 GORDON, JOHN, M.D., 20, Wickham road, Brockley, S.E.

1869† GOSS, TREGENNA BIDDULPH, 1, The Circus, Bath. *Hon. Loc. Sec.*

1891† GOSTLING, WILLIAM AYTON, M.D., B.S.Lond., Barningham, West Worthing.

1889 GOULLET, CHARLES ARTHUR, L.R.C.P.Lond., 2, Finchley road, N.W.

1890 GOW, WILLIAM JOHN, M.D.Lond., Physician-Accoucheur in charge of Out-patients, St. Mary's Hospital; 27, Weymouth street, W. *Council*, 1893-5. *Trans.* 2.

1893† GOWAN, BOWIE CAMPBELL, L.R.C.P.Lond., Raven Dene, Great Stanmore.

1893 GRANT, LEONARD, M.D.Edin., 9, Western villas, New Southgate, N.

1890† GRAY, HARRY ST. CLAIR, M.D. Glas., 25, Lynedoch street, Glasgow.

1875† GRAY, JAMES, M.D., 15, Newton terrace, Glasgow.

1890 GREEN, CHARLES DAVID, M.D.Lond., Addison House, Upper Edmonton.

Elected

1894† GREEN, CHARLES ROBERT MORTIMER, Surgeon-Captain, The Eden Hospital, Calcutta.

1887 GREENWOOD, EDWIN CLIMSON, L.R.C.P., 19, St. John's wood park, N.W.

1863 *GRIFFITH, G. DE GORREQUER, 34, St. George's square, S.W. *Trans.* 2.

1879* GRIFFITH, WALTER SPENCER ANDERSON, M.D. Cantab., F.R.C.S., F.R.C.P., Assistant Physician-Accoucheur to St. Bartholomew's Hospital; 96, Harley street, W. *Council*, 1886-8, 1893-5. *Hon. Lib.*, 1896-7. *Board Exam. Midwives*, 1887-9. *Trans.* 8.

1870 *GRIGG, WILLIAM CHAPMAN, M.D., Physician to the In-patients, Queen Charlotte's Lying-in Hospital; 27, Curzon street, Mayfair. *Council*, 1875-7. *Board Exam. Midwives*, 1878-9.

1888*†GRIMSDALE, THOMAS BABINGTON, B.A., M.B. Cantab., 50, Rodney street, Liverpool.

1882† GRIPPER, WALTER, M.B. Cantab., The Poplars, Wallington, Surrey.

1880 GROGONO, WALTER ATKINS, Berwick House, Broadway, Stratford, E.

1896† GROVES, ERNEST W., L.R.C.P. Lond., Ketley Bank, Oakengates, Salop.

1892 GUBB, ALFRED SAMUEL, M.D. Paris, 29, Gower street, W.C.

1887† HACKNEY, JOHN, M.D. St. And., Oaklands, Hythe.

1881† HAIR, JAMES, M.D., Brinklow, Coventry.

1889 HALE, CHARLES D. B., M.D., 3, Sussex place, Hyde park, W.

1880 HAMES, GEORGE HENRY, F.R.C.S., 29, Hertford street, Park lane, W.

1894 HAMILTON, BRUCE, L.R.C.P. Lond., "Falklands," 9, Frognal, N.W.

1894† HAMILTON, DAVID LIVINGSTON, L.R.C.P. Edin., 260, Oxford road, Manchester.

Elected

1887† HAMILTON, JOHN, F.R.C.S.Ed., Beechhurst House, Swadlincote, Burton-on-Trent.

1883 HANDFIELD-JONES, MONTAGU, M.D. Lond., M.R.C.P., Physician-Accoucheur to, and Lecturer on Midwifery and Diseases of Women at, St. Mary's Hospital; 35, Cavendish square, W. *Council*, 1887-9, 1896-7. *Board Exam. Midwives*, 1894-6. *Trans.* 1.

1889† HARDWICK, ARTHUR, M.D. Durh., Newquay, Cornwall.

1886† HARDY, HENRY L. P., Holly Lodge, Richmond road, Kingston-on-Thames.

1892 HAROLD, JOHN, L.R.C.P.Lond., 91, Harley street, W.

1889 HARPER, CHARLES JOHN, L.R.C.P. Lond., Church end, Finchley, N.

1877 HARPER, GERALD S., M.B.Aber., 40, Curzon street, Mayfair, W. *Council*, 1894-5.

1878† HARRIES, THOMAS DAVIES, F.R.C.S., Grosvenor House, Aberystwith, Cardiganshire.

1867* HARRIS, WILLIAM H., M.D., 32, Cambridge gardens, W.

1880* HARRISON, RICHARD CHARLTON, 19, Uxbridge road, Ealing, W.

1890† HART, DAVID BERRY, M.D.Edin., 29, Charlotte square, Edinburgh.

1886† HARTLEY, HORACE, L.R.C.P. Ed., Stone, Staffordshire.

1886 HARTLEY, REGINALD, M.D. Durh., F.R.C.S.Ed., 112, Westbourne grove, W.

1894 HARTZHORNE, BERNARD FRED., M.R.C.S., Blenheim Lodge, High road, Chiswick.

1893† HARVEY, JOHN JORDAN, L.R.C.P.&S.Edin.

1880 HARVEY, JOHN STEPHENSON SELWYN, M.D.Durh., M.R.C.P., 1, Astwood road, Cromwell road, S.W.

1865† HARVEY, ROBERT, M.D., Abbottabad, Punjab. [Per Messrs. Cochran and Macpherson, 152, Union street, Aberdeen.] *Trans.* 1.

Elected

1886 HARVEY, SIDNEY FRED., L.R.C.P.Lond., 117A, Queen's Gate, S.W.

1892† HAWKINS-AMBLER, GEORGE ARTHUR, F.R.C.S.Ed., 35, Rodney street, Liverpool.

1888† HAYCOCK, HENRY EDWARD, L.R.C.P.Ed., Ironville House, Alfreton, Derbyshire.

1893† HAYDON, THOMAS HORATIO, M.B., B.C. Cantab., 22, High street, Marlborough.

1873 HAYES, THOMAS CRAWFORD, M.A., M.D., F.R.C.P., Obstetric Physician to King's College Hospital, and Lecturer on Practical Midwifery at King's College; 17, Clarges street, Piccadilly, W. *Council*, 1876-8. *Vice-Pres.* 1890-1.

1880 HEATH, WILLIAM LENTON, M.D., 90, Cromwell road, Queen's gate, S.W. *Council*, 1891. *Trans.* 1.

1894 HELBY, ERNEST H., L.R.C.P. Lond., The Borough Hospital, Croydon.

1892† HELLIER, JOHN BENJAMIN, M.D.Lond., Lecturer on Diseases of Women and Children, Yorkshire College; Surgeon to the Hospital for Women and Children, Leeds; 1, De Grey terrace, Leeds.

1890† HELME, T. ARTHUR, M.D.Edin., 258, Oxford road, Manchester.

1867† HEMBROUGH, JOHN WILLIAM, M.D., The Moot Hall, Newcastle-on-Tyne.

1876* HERMAN, GEORGE ERNEST, M.B., F.R.C.P., Obstetric Physician to, and Lecturer on Midwifery at, the London Hospital; 20, Harley street, Cavendish square, W. *Council*, 1878-9. *Hon. Lib.* 1880-1. *Hon. Sec.* 1882-5. *Vice-Pres.* 1886-7. *Board Exam. Midwives*, 1886-8. *Treas.* 1889-92. *Pres.* 1893-4. *Trans.* 29.

1892† HILLS, THOMAS HYDE, L.R.C.P. Lond., 7, St. Peter's terrace, Cambridge.

1886† HODGES, HERBERT CHAMNEY, L.R.C.P.Lond., Watton, Herts. *Trans.* 1.

Elected

1886† HOLBERTON, HENRY NELSON, L.R.C.P. Lond., East Molesey.

1875 HOLLINGS, EDWIN, M.D., 25, Endsleigh gardens, N.W. *Council*, 1888-90. *Vice-Pres.* 1893-4.

1859 HOLMAN, CONSTANTINE, M.D., 26, Gloucester place, Portman square, W. *Council*, 1867-9, 1895-6. *Vice-Pres.* 1870-1.

1891† HOLMAN, ROBERT COLGATE, Whithorne House, Midhurst, Sussex.

1864* HOOD, WHARTON PETER, M.D., 11, Seymour street, Portman square, W.

1896† HOPKINS, GEORGE HERBERT, F.R.C.S., 3, North Quay, Brisbane, Queensland.

1884 HOPKINS, JOHN, L.R.C.P. Ed., Glencoe, Gheneldon road, Streatham, S.W.

1894† HORNE, EDWARD, M.R.C.S., St. Mary's street, Wallingford.

1883* HORROCKS, PETER, M.D., F.R.C.P. Lond., Assistant Obstetric Physician to, and Demonstrator of Practical Obstetrics at, Guy's Hospital; 26, St. Thomas's street, S.E. *Council*, 1886-7. *Hon. Lib.* 1888-9. *Hon. Sec.* 1890-3. *Vice-Pres.* 1894-6. *Trans.* 2.

1876 HORSMAN, GODFREY CHARLES, 22, King street, Portman square, W.

1893† HOSKER, JAMES ATKINSON, Kirkleatham, Boscombe, Bournemouth.

1883 HOSKIN, THEOPHILUS, L.R.C.P. Lond., 1, Amhurst park, N.

1883 HOUCHIN, EDMUND KING, L.R.C.P. Ed., 23, High street, Stepney, E.

1884† HOUGH, CHARLES HENRY, Full street, Derby.

1877 HOWELL, HORACE SYDNEY, M.D., East Grove House, 18, Boundary road, St. John's Wood, N.W.

1879† HUBBARD, THOMAS WELLS, Barming place, Maidstone.

1889† HUMPHRYS, CHARLES BEYER, L.R.C.P. & S. Edin., Eagle House, Blandford, Dorset.

Elected

1884*†HURRY, JAMIESON BOYD, M.D. Cantab., 43, Castle street, Reading. *Council*, 1887-9. *Vice.-Pres.* 1897. *Trans.* 2.

1878† HUSBAND, WALTER EDWARD, Ebor Lodge, Higher Broughton, Manchester.

1895 HUXLEY, HENRY, L.R.C.P.Lond., 2, Queensborough terrace, W.

1894† ILOTT, HERBERT JAMES, M.D. Aber., 57, High street, Bromley, Kent.

1883† INMAN, ROBERT EDWARD, Gadshill Cottage, Higham, Kent.

1884† IRWIN, JOHN ARTHUR, M.A., M.D., 14, West Twenty-ninth street, New York.

1883† JACKSON, GEORGE HENRY, Ashburton, Carew road, Eastbourne.

1873† JAKINS, WILLIAM VOSPER, L.R.C.P. Ed., 14, Collins street East, Melbourne.

1872† JALLAND, ROBERT, Horncastle, Lincolnshire. *Trans.* 1.

1890† JAMES, CHARLES HENRY, L.R.C.P.Lond., Surg. Indian Army; Lahore, India.

1895† JAMES, STANLAKE, Violet hill, Simla, India.

1886 JAMISON, ARTHUR ANDREW, M.D. Glas., 18, Lowndes street, S.W.

1883*†JENKINS, EDWARD JOHNSTONE, M.D. Oxon., 213, Macquarie street, Sydney.

1877† JENKS, EDWARD W., M.D., 84, Lafayette avenue, Detroit, Michigan, U.S.

1882 JENNINGS, CHARLES EGERTON, M.D. Durh., F.R.C.S. Eng., Assistant Surgeon to the North-West London Hospital; 48, Seymour street, Portman square, W.

1877† JOHNSON, SAMUEL, M.D., 5, Hill street, Stoke-upon-Trent.

1881 JOHNSTON, JOSEPH, M.D., 24, St. John's Wood park, N.W. *Council*, 1891-2.

1894 JOHNSTONE, R. W., M.D., B.Ch., 1, Walton place, S.W.

1868† JONES, EVAN, Ty-Mawr, Aberdare, Glamorganshire. *Council*, 1886-8. *Vice.-Pres.* 1890-1. *Hon. Loc. Sec.*

1894 JONES, EVAN, L.R.C.P. Lond., 89, Goswell road, E.C.

Elected

1895† JONES, GEORGE HORATIO, Deddington, Oxon.

1878 JONES, H. MACNAUGHTON, M.D., F.R.C.S.I. and Edin., 141, Harley street, Cavendish square, W.

1881† JONES, JAMES ROBERT, M.B., 247, Donald street, Winnipeg, Manitoba, Canada.

1894† JONES, JOHN ARNALLT, L.R.C.P. Lond., Heathmont, Aberavon, Port Talbot, Glamorganshire.

1887† JONES, J. TALFOURD, M.B. Lond., Consulting Physician to the Breconshire Infirmary, Rose Bank, South terrace, Eastbourne.

1886 JONES, LEWIS, M.D., Oakmead, Balham, S.W.

1885† JONES, P. SYDNEY, M.D., 16, College street, Hyde park, Sydney. [Per Messrs. D. Jones and Co., 122 and 124, Wool Exchange, Basinghall street, E.C.]

1873† JONES, PHILIP W., River House, Enfield.

1886† JONES, WILLIAM OWEN, The Downs, Bowdon, Manchester.

1879† JOUBERT, CHARLES HENRY, M.B. Lond., F.R.C.S. Eng., Surgeon-Major, Bengal Medical Department; Obstetric Physician to Eden Hospital, and Professor of Midwifery and Diseases of Women and Children, Calcutta Medical College; 6, Harington street, Calcutta.

1878† JUDSON, THOMAS ROBERT, L.R.C.P. Lond., 44, Mill lane, West Derby, Liverpool.

1890 KANTHACK, ALFREDO ANTUNES, M.D. Lond., St. Bartholomew's Hospital, E.C. *Council*, 1897.

1884 KEATES, WILLIAM COOPER, L.R.C.P., 22, East Dulwich road, S.E.

1880† KEBBELL, ALFRED, Flaxton, York.

1883† KEELING, JAMES HURD, M.D., 267, Glossop road, Sheffield. *Hon. Loc. Sec.*

1896 KEEP, ARTHUR CORRIE, M.D., C.M.Edin., 2, Manchester square, W.

1890 KEITH, SKENE, M.B., C.M.Edin., 42, Charles street, Berkeley Square, W.

Elected

1894 KELLETT, ALFRED FEATHERSTONE, M.B., B.C.Cantab., 142, Lewisham road, S.E.

1874* KEMPSTER, WILLIAM HENRY, M.D., Chesterfield, Clapham common, North side, S.W.

1886 KENNEDY, ALFRED EDMUND, L.R.C.P. Ed., Chesterton House, Plaistow, E.

1879 KER, HUGH RICHARD, L.R.C.P.Ed., Tintern, 2, Balham hill, S.W.

1895† KERR, JOHN MARTIN MUNRO, M.B., C.M.Glasg., 28, Berkeley terrace, Glasgow.

1872 KERR, NORMAN S., M.D., F.L.S., 42, Grove road, Regent's park, N.W.

1877*†KERSWILL, JOHN BEDFORD, M.R.C.P. Ed., Fairfield, St. German's, Cornwall.

1878† KHORY, RUSTONJEE NASERWANJEE, M.D., M.R.C.P., Medical Syndic, Bombay University; Honorary Physician, Bai Motlibai Obstetric and Gynæcological Hospital; Hormazd Villa, Khumballa hill, Bombay.

O.F.* KIALLMARK, HENRY WALTER, 5, Pembridge gardens, Bayswater. *Council*, 1879-80.

1895† KING, ARTHUR, M.B., C.M., Station road, Watford.

1892† KINGSCOTE, ERNEST, M.B., C.M.Edin., The Hall, Salisbury.

1872* KISCH, ALBERT, 61, Portsdown road, W. *Council*, 1896-7.

1876† KNOTT, CHARLES, M.R.C.P. Ed., Liz Ville, Elm grove, Southsea.

1889 LAKE, GEORGE ROBERT, 177, Gloucester terrace, Hyde park, W.

1867* LANGFORD, CHARLES P., Sunnyside, Hornsey lane, N.

1883 LANGLEY, AARON, L.R.C.P. Ed., 149, Walworth road, S.E.

1887 LAW, WILLIAM THOMAS, M.D. Edin., 9, Norfolk crescent, W.

1875† LAWRENCE, ALFRED EDWARD AUST, M.D., Physician-Accoucheur to the Bristol General Hospital; 19, Richmond hill, Clifton, Bristol. *Council*, 1885-6, 1888. *Vice-Pres.*, 1889-90. *Hon. Loc. Sec. Trans.* 1.

Elected

1894† LEA, ARNOLD W. W., M.D., B.S.Lond., F.R.C.S., 274, Oxford road, Manchester.

1894† LEAHY, ALBERT WILLIAM DENIS, M.D. Durh., F.R.C.S., 6, Elysium road, Calcutta.

1884*†LEDIARD, HENRY AMBROSE, M.D., 35, Lowther street, Carlisle. *Council*, 1890-2. *Trans.* 1.

1894† LEE, SIDNEY HERBERT, B.A., M.B., B.C.Cantab., The Moat, Thame, Oxon.

1885 LEWERS, ARTHUR H. N., M.D. Lond., M.R.C.P., Obstetric Physician to the London Hospital; 72, Harley street, W. *Council*, 1887-9, 1893. *Board Exam. Midwives* 1895-7. *Trans.* 9.

1877† LEWIS, JOHN RIGGS MILLER, M.D., Deputy Surgeon-General, Markham Lodge, Liverpool road, Kingston hill, Surrey.

1885† LIDIARD, SYDNEY ROBERT, L.R.C.P. Ed., Park View House, Falmouth.

1875† LIEBMAN, CARLO, M.D. Vienna, Principal Surgeon, Trieste Civil Hospital, Trieste, Austria. *Trans.* 1.

1894 LIVERMORE, WILLIAM LEPPINGWELL, L.R.C.P. Lond., 52, Stapleton Hall road, Stroud green, N.

1872*†LOCK, JOHN GRIFFITH, M.A., 2, Rock terrace, Tenby.

1893† LOGAN, RODERIC ROBERT WALTER, Church street, Ashby-de-la-Zouch.

1859† LOMBE, THOMAS ROBERT, M.D., Bemerton, Torquay.

1894† LOOS, WILLIAM CHRISTOPHER, L.R.C.P. Lond., c/o Union Steamship Co., Ltd., Southampton.

1890 LOW, HAROLD, M.B.Cantab., 10, Evelyn gardens, South Kensington.

1893† LOWE, WALTER GEORGE, M.D. Lond., F.R.C.S., Burton-on-Trent.

1878*†LYCETT, JOHN ALLAN, M.D., Gatcombe, Surgeon to the Wolverhampton and District Hospital for Women, Wolverhampton.

1896† LYONS, A., M.B., Thames Ditton.

Elected

1871† McCallum, Duncan Campbell, M.D., Emeritus Professor, McGill University; 45, Union avenue, Montreal, Canada. *Trans.* 4.

1890 McCann, Frederick John, M.B., C.M.Edin., M.R.C.P., Physician to Out-patients at the Samaritan Hospital; 5, Curzon street, Mayfair, W. *Council*, 1897. *Trans.* 3.

1894† McCausland, Albert Stanley, M.D. Brux., Church Hill House, Swanage.

1890 McCaw, John Dysart, M.D., F.R.C.S., Ivy House, Lincoln road, East Finchley, N.

1894† McDonnell, Æneas John, M.D., Ch.M. Sydney, Toowoomba, Queensland.

1896 McDonnell, W. Campbell, L.R.C.P.Lond., Park house, Park lane, Stoke Newington, N.

1896 Macgregor, Patrick Fraser, M.B., 24, Addison gardens, W.

1892† McKay, M. Stewart, M.B., M.Ch. Sydney, Australian Club, Macquarie street, Sydney, N.S.W.

1879† Mackeough, George T., M.D., Chatham, Ontario, Canada.

1894† McKisack, Henry Lawrence, M.D.Dubl., 15, College square east, Belfast.

1893 Maclean, Ewen John, M.D., C.M. Edin., 51, Linden gardens, Kensington, W.

1886 McMullen, William, L.K.Q.C.P.I., 319a, Brixton road, S.W.

1894† McOscar, John, L.R.C.P. Lond., Stoneleigh, Watlington, Oxon.

1895† Maidlow, William Harvey, M.D.Durh., F.R.C.S.Eng., Elm Lodge, Park Hill Rise, Croydon.

1884 Malcolm, John D., M.B., C.M., Surgeon to the Samaritan Free Hospital; 13, Portman street, W. *Council*, 1894-6.

1871† Malins, Edward, M.D., Obstetric Physician to the General Hospital, Professor of Midwifery at Mason College, Birmingham; 50, Newhall street, Birmingham. *Council*, 1881-3. *Vice-Pres.* 1884-6. *Hon. Loc. Sec.*

Elected

1868*†MARCH, HENRY COLLEY, M.D., Portisham, Dorchester. *Council*, 1890-2.

1887 MARK, LEONARD P., L.R.C.P. Lond., 61, Cambridge street, Hyde-park square, W.

1860† MARLEY, HENRY FREDERICK, The Nook, Padstow, Cornwall.

1862*†MARRIOTT, ROBERT BUCHANAN, Swaffham, Norfolk.

1887† MARSH, O. E. BULWER, L.R.C.P. Ed., Parkdale, Clytha park, Newport, Monmouthshire.

1890† MARTIN, CHRISTOPHER, M.B., C.M.Edin., 22, Broad street, Birmingham. *Trans.* 1.

1884 MASSEY, HUGH HOLLAND, 3, North terrace, Camberwell, S.E.

1883† MAURICE, OLIVER CALLEY, 75, London street, Reading. *Council*, 1888-90.

1890 MAY, CHICHESTER GOULD, M.A., M.D.Cantab., Assistant Physician to the Grosvenor Hospital for Women and Children; 26, Walton street, Pont street, S.W.

1884† MAYNARD, EDWARD CHARLES, L.R.C.P.Ed., Leslie villa, The Vineyard, Richmond.

1891† MAYNER, ALFRED EDGAR, M.D.Montreal, 87, Hanover street, Kingston, Jamaica.

1885† MELLER, CHARLES BOOTH, L.R.C.P. Ed., Cowbridge, Glamorganshire.

1886 MENNELL, ZEBULON, 1, Royal crescent, Notting hill, W.

1882 MEREDITH, WILLIAM APPLETON, M.B., C.M., Surgeon to the Samaritan Free Hospital for Women and Children; 21, Manchester Square, W. *Council*, 1886-8. *Vice-Pres.* 1891-3. *Trans.* 3.

1893 MESQUITA, S. BUENO DE, M.D., B.S.Lond., 1, Highbury New park, N.

1893† MICHIE, HARRY, M.B. Aber., 27, Regent street, Nottingham.

Elected

1875*†MILES, ABIJAH J., M.D., Professor of Diseases of Women and Children in the Cincinnati College of Medicine, Cincinnati, Ohio, U.S.

1895† MILLER, JAMES THOMAS ROGER, Castlegate House, Malton, Yorkshire.

1876* MILLMAN, THOMAS, M.D., 59, Yonge street, Toronto, Ontario, Canada.

1880† MILLS, ROBERT JAMES, M.B., M.C., 35, Surrey street, Norwich.

1876 MILSON, RICHARD HENRY, M.D., 88, Finchley road, South Hampstead, N.W. *Council*, 1890.

1892† MILTON, HERBERT M. NELSON, Kasr-el-Aini Hospital, Cairo, Egypt.

1869*†MINNS, PEMBROKE R. J. B., M.D., Thetford, Norfolk.

1867* MITCHELL, ROBERT NATHAL, M.D., 27, Fitzjohn's Avenue, N.W.

1894† MONDELET, WILLIAM HENRY, M.D., 1, Gladstone terrace, Brighton.

1893† MONTBRUN, D. ANTONIO DE, L.R.C.P. Lond., Port of Spain, Trinidad, W.I.

1877 MOON, FREDERICK, M.B., Bexley house, Greenwich, S.E.

1859† MOORHEAD, JOHN, M.D., Surgeon to the Weymouth Infirmary and Dispensary; Weymouth, Dorset.

1888 MORISON, ALEXANDER, M.D. Ed., 14, Upper Berkeley street, Portman square, W.

1895 MORISON, HENRY BANNERMANN, M.B.Durh., 18, Holland park avenue, W.

1890 MORRIS, CHARLES ARTHUR, M.A., M.B., B.C.Cantab., F.R.C.S., 29, Eccleston street, Eaton square, S.W.

1883 MORRIS, CLARKE KELLY, Gordon Lodge, Charlton road, Blackheath, S.E.

1893 MORRISON, JAMES, L.R.C.P. Lond., St. Bartholomew's Hospital, E.C.

Elected

1893† MORSE, THOMAS HERBERT, F.R.C.S., 10, Upper Surrey street, Norwich. *Trans.* 1.

1891 MORTLOCK, CHARLES, L.R.C.P.Lond., 27, Oxford square, Hyde park, W.

1886† MORTON, SHADFORTH, M.D. Durham, 24, Wellesley road, Croydon.

1896 MUGFORD, SIDNEY ARTHUR, L.R.C.P., 135, Kennington park road, S.E.

1893 MUIR, ROBERT DOUGLAS, L.R.C.P.Lond., 286, New Cross road, S.E.

1896† MURPHY, JAMES KEOGH, L.R.C.P., Glencairn, Kilgobbin, co. Dublin.

1885 MURRAY, CHARLES STORMONT, L.R.C.S. and L.M. Ed., 85, Gloucester place, Portman square, W.

1893† MURRAY, ROBERT MILNE, M.B. Edin., 11, Chester street, Edinburgh.

O.F. MUSGRAVE, JOHNSON THOMAS, L.R.C.P. Ed., 10, College terrace, Belsize park, N.W. *Council*, 1859-60. *Trans.* 1.

1888 MYDDELTON-GAVEY, EDWARD HERBERT, 94, Wimpole street, W.

1893† NAIRNE, JOHN STUART, F.R.C.S. Ed., 141, Hill street, Garnethill, Glasgow.

1887 NAPIER, A. D. LEITH, M.D. Aber., M.R.C.P. Lond., F.R.S. Edin., Physician to the Royal Maternity Charity; 67, Grosvenor street, W. *Trans.* 2.

1896† NARIMAN, R. T., M.D.Brux., Parsi Lying-in Hospital, Bombay.

1892† NASH, W. GIFFORD, F.R.C.S., 36, St. Peter's, Bedford.

1859† NEAL, JAMES, M.D., Parterre, Sandown, Isle of Wight.

1882† NESHAM, THOMAS CARGILL, M.D., Lecturer on Midwifery in the University of Durham College of Medicine at Newcastle-on-Tyne; 12, Ellison place, Newcastle-on-Tyne. *Council*, 1889-91. *Vice-Pres.* 1895-7.

Elected

1859*†NEWMAN, WILLIAM, M.D., Surgeon to the Stamford and Rutland Infirmary; Barn Hill House, Stamford, Lincolnshire. *Council*, 1873-5. *Vice-Pres.* 1876-7. *Trans.* 5.

1889† NEWNHAM, WILLIAM HARRY CHRISTOPHER, M.A., M.B.Cantab., Chandos Villa, Queen's road, Clifton, Bristol.

1895† NEWSTEAD, JAMES, 9, York place, Clifton, Bristol.

1893† NICHOL, FRANK EDWARD, M.A., M.B., B.C.Cantab., 11, Ethelbert Terrace, Margate.

1873† NICHOLSON, ARTHUR, M.B. Lond., 30, Brunswick square, Brighton. *Council*, 1897.

1894 NICHOLSON, EDGAR, M.R.C.S., 42, Portland road, Notting hill, W.

1879† NICHOLSON, EMILIUS ROWLEY, M.D., 19, Cornwallis gardens, Hastings.

1894 NICOLL, THOMAS VERE, L.R.C.P., M.R.C.S., 147, Cromwell road, South Kensington.

1876* NIX, EDWARD JAMES, M.D., 11, Weymouth street, W. *Council*, 1889-90.

1882† NORMAN, JOHN EDWARD, Lismore House, Hebburn-on-Tyne.

1880† OAKLEY, JOHN, Holly House, Ward's end, Halifax, Yorkshire.

1894 O'CALLAGHAN, ROBERT THOMAS ALEXANDER, F.R.C.S.I., 137, Harley street, W.

1886 OGLE, ARTHUR WESLEY, L.R.C.P. Lond., 90, Cannon street, E.C.

1895† OGLE, JOHN GILBERT, M.D.Oxon., Reigate, Surrey.

O.F.† OLDHAM, HENRY, M.D., F.R.C.P., Consulting Obstetric Physician to Guy's Hospital; Cannington, Boscombe, Bournemouth. *Vice-Pres.* 1859. *Council*, 1860, 1865-6. *Treas.* 1861-2. *Pres.* 1863-4. *Trans.* 1. *Trustee.*

Elected

1888 OLIVER, FRANKLIN HEWITT, L.R.C.P. Lond., 2, Kingsland road, N.E.

1889 OLIVER, JAMES, M.D., F.R.S. Edin., F.L.S., Physician to the Hospital for Women, Soho square; 18, Gordon square, W.C.

1890† OSBURN, HAROLD BURGESS, L.R.C.P., Bagshot, Surrey.

1877† OSTERLOH, PAUL RUDOLPH, M.D. Leipzic, Physician for Diseases of Women, Diaconissen Hospital; 16, Sidonienstr., Dresden.

1892 OWEN, SAMUEL WALSHE, L.R.C.P.Lond., 10, Shepherd's Bush road, W.

1889* PAGE, HARRY MARMADUKE, M.D.Brux., F.R.C.S., 107, London wall, E.C.

1891† PAGE, HERBERT MARKANT, M.D.Brux., 16, Prospect hill, Redditch.

1883 PALMER, JOHN IRWIN, 132, Harley street, Cavendish square, W.

1877* PARAMORE, RICHARD, M.D., 2, Gordon square, W.C.

1867*†PARKS, JOHN, Bank House, Manchester road, Bury, Lancashire.

1887 PARSONS, JOHN INGLIS, M.D.Durh., M.R.C.P., Physician to Out Patients, Chelsea Hospital for Women, 3, Queen street, Mayfair, W. *Trans.* 2.

1880 PARSONS, SIDNEY, 78, Kensington Park road, W.

1889 PARSONS, THOMAS EDWARD, Paddock House, Ridgeway, Wimbledon.

1865*†PATERSON, JAMES, M.D., Hayburn Bank, Partick, Glasgow.

1882* PEACEY, WILLIAM, M.D., Rydal Mount, St. John's road, Eastbourne.

1894 PEAKE, SOLOMON, M.R.C.S., 118, Percy road, Shepherd's Bush, W.

1864 PEARSON, DAVID RITCHIE, M.D., 23, Upper Phillimore place, Kensington, W. *Council*, 1895.

Elected

1871 PEDLER, GEORGE HENRY, 6, Trevor terrace, Rutland gate, S.W. *Council*, 1897.

1880*†PEDLEY, THOMAS FRANKLIN, M.D., Rangoon, India. *Trans.* 1.

1881† PERIGAL, ARTHUR, M.D., New Barnet, Herts. *Council*, 1892–3.

1893 PERKINS, GEORGE C. STEELE, M.D., 85, Wimpole street, W.

1871† PERRIGO, JAMES, M.D., 826, Sherbrooke street, Montreal, Canada. *Hon. Loc. Sec.*

1879*†PESIKAKA, HORMASJI DOSABHAI, 23, Hornby row, Bombay.

1883 PETTIFER, EDMUND HENRY, 32, Stoke Newington green, N.

1894 PETTY, DAVID, M.B., C.M., Edin., 6, High road, South Tottenham, N.E.

1879 PHILLIPS, GEORGE RICHARD TURNER, 28, Palace court, Bayswater hill, W. *Council*, 1891.

1882 PHILLIPS, JOHN, M.A., M.D. Cantab., F.R.C.P., Assistant Obstetric Physician to King's College Hospital; 68, Brook street, W. *Council*, 1887-9, 1893. *Hon. Lib.* 1894-5. *Hon. Sec.* 1896-7. *Board Exam. Midwives*, 1892-4. *Trans.* 9.

1897 PHILLIPS, LLEWELLYN C. P., M.B., B.C.Cantab., St. Bartholomew's Hospital, E.C.

1878 PHILPOT, JOSEPH HENRY, M.D., 61, Chester square, S.W. *Council*, 1891.

1889† PINHORN, RICHARD, L.R.C.P. Lond., 5, Cambridge terrace, Dover. *Council*, 1897.

1889† PLAYFAIR, DAVID THOMSON, M.D., C.M. Edin., Redwood House, Bromley, Kent.

1893 PLAYFAIR, HUGH JAMES MOON, M.D. Lond., 9, Cliveden place, Eaton square, S.W.

1864* PLAYFAIR, W. S., M.D., LL.D., F.R.C.P., Physician-Accoucheur to H.I. & R.H. the Duchess of Edinburgh; Professor of Obstetric Medicine in King's College, and Obstetric Physician to King's College Hospital, 38, Grosvenor street, W. *Council*, 1867, 1883-5. *Hon. Librarian*, 1868-9. *Hon. Sec.* 1870-72. *Vice-Pres.* 1873-5. *Pres.* 1879-80. *Trans.* 15.

Elected

1880 POCOCK, FREDERICK ERNEST, M.D., The Limes, St. Mark's road, Notting hill, W.

1891 POLLOCK, WILLIAM RIVERS, M.B., B.C.Cantab., Assistant Obstetric Physician to the Westminster Hospital, 56, Park street, Grosvenor square, W. *Council*, 1895-7.

1876 POPE, H. CAMPBELL, M.D., F.R.C.S., Broomsgrove Villa, 280, Goldhawk road, Shepherd's Bush, W.

1891† POPE, HENRY SHARLAND, M.B., B.C.Cantab., Castle Bailey, Bridgwater.

1888 POPHAM, ROBERT BROOKS, M.R.C.P.Edin., L.R.C.P.Lond., 67, Bartholomew road, Camden road, N.W.

1864* POTTER, JOHN BAPTISTE, M.D., F.R.C.P., Obstetric Physician to, and Lecturer on Midwifery and Diseases of Women at, the Westminster Hospital; 20, George street, Hanover square, W. *Council*, 1872-6, 1890-2. *Hon. Lib.* 1877-8. *Vice-Pres.* 1879-81. *Treas.* 1882-4, 1893-7. *Board Exam. Midwives*, 1883-4. *Pres.* 1885-6. *Trans.* 1.

1894† POUND, CLEMENT, L.R.C.P. Lond., High street, Odiham, Hants.

1893 POWELL, HERBERT EDWARD, Glenarm House, Upper Clapton, N.E.

1884† POWELL, JOHN JAMES, L.R.C.P. Lond., Norwood Lodge, Weybridge.

1885† PRAEGER, EMIL ARNOLD, Rooms 56—57, Potomac Block, Broadway, Los Angeles, Cal.

1886 PRANGLEY, HENRY JOHN, L.R.C.P. Lond., Tudor House, 197, Anerley road, Anerley, S.E.

1893† PRATT, WILLIAM SUTTON, M.D., Alma House, Rugby.

1880* PRICKETT, MARMADUKE, M.A.Cantab., M.D., Physician to the Samaritan Hospital; 27, Oxford square, W. *Council*, 1892.

1895 PRIESTLEY, R. C., M.A., M.B.Cantab., 81, Linden gardens, Bayswater, W.

Elected

O.F.* PRIESTLEY, SIR WILLIAM O., M.D., LL.D., F.R.C.P., Consulting Obstetric Physician to King's College Hospital; 17, Hertford street, Mayfair, W. *Council*, 1859-61, 1865-6. *Vice-Pres.* 1867-9. *Pres.* 1875-6. *Trans.* 6.

1893 PROBYN-WILLIAMS, ROBERT JAMES, M.D.Durh., 22, Duke street, Portland place. *Trans.* 1.

1876*†QUIRKE, JOSEPH, L.R.C.P. Ed., The Oaklands, Hunter's road, Handsworth, Birmingham.

1896 RANKIN, GUTHRIE, M.D. Glas., 4, Chesham street, S.W.

1878† RAWLINGS, JOHN ADAMS, M.R.C.P.Ed., Preswylfa, Swansea.

1897 RAWLINGS, J. D., M.B.Lond., 184, Belsize road, Hampstead, N.W.

1870* RAY, EDWARD REYNOLDS, Dulwich, S.E.

1894† RAYNER, HERBERT EDWARD, F.R.C.S., Harcourt House, Camberley, Surrey.

1860* RAYNER, JOHN, M.D., Swaledale House, Highbury quadrant, N.

1879 READ, THOMAS LAURENCE, 11, Petersham terrace, Queen's gate, S.W. *Council*, 1892.

1879† REID, WILLIAM LOUDON, M.D., Professor of Midwifery and Diseases of Women and Children, Anderson's College; Physician to the Glasgow Maternity Hospital; 7, Royal crescent, Glasgow.

1889 REMFRY, LEONARD, M.A., M.D., B.C. Cantab., Assistant Obstetric Physician to, and Assistant Lecturer on Obstetric Medicine at, St. George's Hospital; 60, Great Cumberland place, Hyde park, W. *Council*, 1894-6. *Board Exam. Midwives*, 1897. *Trans.* 4.

1893† RENSHAW, ISRAEL JAMES EDWARD, F.R.C.S.Edin., Gorse Lea, Sale, near Manchester.

1875*†REY, EUGENIO, M.D., 39, Via Cavour, Turin.

1890 REYNOLDS, JOHN, M.D.Brux., 11, Brixton hill, S.W.

Elected

1872† RICHARDSON, WILLIAM L., M.D., A.M., Professor of Obstetrics in Harvard University; Physician to the Boston Lying-in Hospital; 225, Commonwealth avenue, Boston, Massachusetts, U.S.

1889† RICHMOND, THOMAS, L.R.C.P. Ed., 2, West garden street, Glasgow.

1872† RIGDEN, GEORGE, Surgeon to the Canterbury Dispensary; 60, Burgate street, Canterbury. *Trans.* 1. *Hon. Loc. Sec.*

1871* RIGDEN, WALTER, M.D. St. And., 16, Thurloe place, S.W. *Council*, 1882-3. *Trans.* 1.

1892 ROBERTS, CHARLES HUBERT, M.B.Lond., F.R.C.S. Eng., M.R.C.P., 21, Welbeck street, Cavendish square, W. *Council*, 1897. *Trans.* 1.

O.F.*† ROBERTS, DAVID LLOYD, M.D., F.R.C.P., F.R.S. Edin., Obstetric Physician to the Manchester Royal Infirmary; and Lecturer on Clinical Midwifery and the Diseases of Women in Owens College; 11, St. John street, Deansgate, Manchester. *Council*, 1868-70, 1880-2. *Vice-Pres.* 1871-2. *Trans.* 5.

1867* ROBERTS, DAVID W., M.D., 56, Manchester street, Manchester square, W.

1890† ROBERTS, HUGH JONES, Sea View, Penygroes, R.S.O., N. Wales.

1883 ROBERTS, JOHN CORYTON, L.R.C.P. Ed., 71, Peckham rye, S.E.

1895† ROBERTS, J. PRICHARD, L.R.C.P.I., East Parade, Harrogate.

1893 ROBERTS, THOMAS, 95, Tredegar road, Bow, E.

1874 ROBERTSON, WILLIAM BORWICK, M.D., St. Anne's, Thurlow park road, West Dulwich, S.E.

1892 ROBINSON, GEORGE H. DRUMMOND, M.D., B.S. Lond., 84, Park street, Grosvenor square, W. *Trans.* 1.

1887 ROBINSON, HUGH SHAPTER, L.R.C.P. Ed., Talfourd House, Camberwell, S.E.

Elected

1884† ROBINSON, LUKE, M.R.C.P. Lond., 533, Sutter street, San Francisco, California.

1895† ROBSON, ALFRED WILLIAM, L.R.C.P. & S.Edin., Kempstow House, 111, Park road, Aston, Birmingham.

1890† ROBSON, A. W. MAYO, F.R.C.S., 7, Park square, Leeds.

1876† ROE, JOHN WITHINGTON, M.D., Ellesmere, Salop.

1874† ROOTS, WILLIAM HENRY, Canbury House, Kingston-on-Thames.

1874 ROPER, ARTHUR, M.D.St.And., Colby, Lewisham hill, S.E. *Council*, 1886-8.

1865*†ROPER, GEORGE, M.D., Consulting Physician to the Royal Maternity Charity; Oulton Lodge, Aylsham, Norfolk. *Council*, 1875-7, 1883-5. *Vice-Pres.* 1879-81, 1889, *Board Exam. Midwives*, 1880-1, 1883-5. *Trans.* 10.

1859 ROSE, HENRY COOPER, M.D., 16, Warwick road, Maida hill, W. *Council*, 1875-7. *Trans.* 4.

1893† ROSENAU, ALBERT, M.D., Hôtel Victoria, Kissingen, Bavaria. (*Winter*, Avenue la Costa, Monte Carlo.)

1884† ROSSITER, GEORGE FREDERICK, M.B., Surgeon to the Weston-super-Mare Hospital; Cairo Lodge, Weston-super-Mare.

1884† ROUGHTON, WALTER, F.R.C.S., Cranborne House, New Barnet.

1882* ROUTH, AMAND, M.D., B.S., Assistant Obstetric Physician to, and Teacher of Practical Obstetrics and Gynæcology at, Charing Cross Hospital; 14A, Manchester square, W. *Council*, 1886-8, 1896-7. *Board Exam. Midwives*, 1893-5. *Trans.* 3.

O.F.* ROUTH, CHARLES HENRY FELIX, M.D., Consulting Physician to the Samaritan Free Hospital for Women and Children; 52, Montagu square, W. *Council*, 1859-61. *Vice-Pres.* 1874-6. *Trans.* 13.

1887*†ROWE, ARTHUR WALTON, M.D. Dur., 1, Cecil street, Margate.

1881† ROWORTH, ALFRED THOMAS, Grays, Essex.

Elected

1886 RUSHWORTH, FRANK, M.D. Lond., 1A, Goldhurst terrace, South Hampstead, N.W.

1888† RUSHWORTH, NORMAN, L.R.C.P. Lond., Beechfield, Walton-on-Thames.

1886† RUTHERFOORD, HENRY TROTTER, M.A., M.D. Cantab., Salisbury House, Taunton. *Council*, 1892-3. *Trans.* 1.

1895† RUTHERFORD, GEORGE JAMES, L.R.C.P.Lond.; Hastings, St. Leonard's, and East Sussex Hospital, Hastings.

1866*†SABOIA, Baron V. de, M.D., Director of the School of Medicine, Rio de Janeiro; 7, Rua dom Affonso, Petropolis, Rio Janeiro. *Trans.* 2.

1864*†SALTER, JOHN H., D'Arcy House, Tolleshunt d'Arcy, Kelvedon, Essex. *Council*, 1894-6.

1868* SAMS, JOHN SUTTON, St. Peter's Lodge, Eltham road, Lee, S.E. *Council*, 1892.

1886† SANDERSON, ROBERT, M.B. Oxon., 98, Montpellier road, Brighton.

1872 SANGSTER, CHARLES, 148, Lambeth road, S.E.

1891† SAUNDERS, FREDERICK WILLIAM, M.B., B.C.Cantab., Chieveley House, near Newbury.

1872† SAVAGE, THOMAS, M.D., Surgeon to the Birmingham and Midland Hospital for Women; 133, Edmund street, Birmingham. *Council*, 1878-80.

1877 SAVORY, CHARLES TOZER, M.D., 6, Douglas road, Canonbury, N. *Trans.* 1.

1894† SAVORY, HORACE, M.A., M.B., B.C. Cantab., Haileybury College, Hertford.

1890 SCHACHT, FRANK FREDERICK, B.A., M.D.Cantab., 168, Earl's Court road, S.W.

1870† SCOTT, JOHN, M.D., Cramond House, Sandwich.

1888 SCOTT, PATRICK CUMIN, B.A., M.B. Cantab., 38, Shooter's Hill road, Blackheath, S.E.

1866 SEQUEIRA, JAMES SCOTT, 68, Leman street, Goodman's fields, E., and Crescent House, Cassland crescent, Cassland road, South Hackney, N.E.

Elected

1882 SERJEANT, DAVID MAURICE, M.D., 1, The Terrace, Camberwell, S.E.

1875 SETON, DAVID ELPHINSTONE, M.D., 1, Emperor's gate, S.W. *Council*, 1884.

1896† SHARMAN, MARK, M.B., C.M.Glas., Rickmansworth.

1894† SHARPIN, ARCHDALE LLOYD, L.R.C.P. Lond., 23, Kimbolton road, Bedford.

O.F.† SHARPIN, HENRY WILSON, F.R.C.S., Consulting Surgeon to the Bedford General Infirmary; 1, St. Paul's square, Bedford. *Council*, 1871-3. *Trans.* 1. *Hon. Loc. Sec.*

1887 SHAW, JOHN, M.D. Lond., Obstetric Physician to the North West London Hospital; 34, Queen Anne street, Cavendish square, W. *Trans.* 3.

1891 SHAW-MACKENZIE, JOHN ALEXANDER, M.D.Lond., 24, Savile row, W.

1896† SHEPPARD, WALTER SIDNEY, B.A, M.B., B.Ch.Cantab., Charing Cross Hospital, W.

1874† SINCLAIR, ALEXANDER DOULL, M.D., Consulting Physician to the Boston Lying-in Hospital; 35, Newbury street, Boston, Massachusetts, U.S.

1888† SINCLAIR, WILLIAM JAPP, M.D. Aber., Honorary Physician to the Southern Hospital for Women and Children and Maternity Hospital, Manchester; and Professor of Obstetrics and Gynæcology, Owens College, Manchester; 250, Oxford road, Manchester.

1881† SLOAN, ARCHIBALD, M.B., 21, Elmbank street, Glasgow.

1876† SLOAN, SAMUEL, M.D., C.M., 5, Somerset place, Sauchiehall street west, Glasgow.

1890† SLOMAN, FREDERICK, 18, Montpellier road, Brighton.

1861 SLYMAN, WILLIAM DANIEL, 26, Caversham road, Kentish Town, N.W. *Council*, 1881.

1867* SMITH, HEYWOOD, M.D., 18, Harley street, Cavendish square, W. *Council*, 1872-5. *Board Exam. Midwives*, 1874-6. *Trans.* 6.

1894 SMITH, HUGH ROUBILIAC, M.B.Lond., 7, Gordon street, Gordon square, W.C.

Elected

1875 SMITH, RICHARD THOMAS, M.D., Physician to the Hospital for Women, Soho square; 117, Haverstock hill, N.W.

1886† SMITH, SAMUEL PARSONS, L.K.Q.C.P.I., Park Hyrst, Addiscombe road, Croydon.

1882† SMITH, STEPHEN MABERLY, L.R.C.P. Ed., Keerie Kara, Ryrie Street, Geelong, Melbourne.

1895 SODEN, WILFRED NEWELL, M.B.Lond., 186, Amhurst road, Hackney, N.E.

1895 SPARKS, CHARLES EDWARD, M.B., B.C., B.A.Cantab., Cassland House, South Hackney, N.E.

1868* SPAULL, BARNARD E., 1, Stanwick road, West Kensington, W.

1888* SPENCER, HERBERT R., M.D., B.S.Lond., Professor of Midwifery in University College, London, and Obstetric Physician to University College Hospital; 10, Mansfield street, Cavendish square, W. *Council*, 1890-92. *Board Exam. Midwives*, 1896-7. *Trans.* 4.

1876† SPENCER, LIONEL DIXON, M.D., Brigade-Surgeon, I.M.S., Bengal Establishment [care of Messrs. Grindlay and Co., 55, Parliament street, S.W.].

1882 SPOONER, FREDERICK HENRY, M.D., Maitland Lodge, Maitland place, Clapton, N.E.

1876† SPURGIN, HERBERT BRANWHITE, 82, Abington street, Northampton.

1893 STACK, E. H. EDWARDS, M.B., B.C. Cantab., St. Bartholomew's Hospital, E.C.

1894 STEER, ADAM WILLIAM THORBURN, M.R.C.S., L.R.C.P. Eng., The Cheal, Hornsey lane, N.

1894 STEVENS, THOMAS GEORGE, M.D., B.S. Lond., 8, St. Thomas's street, S.E. *Trans.* 2.

1884† STEVENSON, EDMOND SINCLAIR, F.R.C.S. Ed., Strathallan House, Rondebosch, Cape of Good Hope. *Trans.* 2.

1877† STEPHENSON, WILLIAM, M.D., Professor of Midwifery, University of Aberdeen; 3, Rubislaw terrace, Aberdeen. *Council*, 1881-3. *Vice-Pres.*, 1887-9. *Trans.* 2.

Elected

1875*†STEWART, WILLIAM, F.R.C.P. Ed., 26, Lethbridge road, Southport.

1884† STIVEN, EDWARD W. F., M.D., The Manor Lodge, Harrow-on-the-Hill.

1884 STIVENS, BERTRAM H. LYNE, M.D.Brux., 107, Park street, Grosvenor square, W.

1883 STOCKS, FREDERICK, 421, Wandsworth road, S.W.

1894† STOTT, WILLIAM ATKINSON, M.R.C.S., L.R.C.P. Lond., 1, Grove terrace, Leeds.

1866* STRANGE, WILLIAM HEATH, M.D., 2, Belsize avenue, Belsize park, N.W. *Council*, 1882-4.

1895 STUCK, SIDNEY JOSEPH, L.R.C.P.Lond., 18, Madeley road, Ealing, W.

1884 SUNDERLAND, SEPTIMUS, M.D., 11, Cavendish place, Cavendish square, W.

1883* SUTHERLAND, HENRY, M.A., M.D. Oxon., M.R.C.P., 6, Richmond terrace, Whitehall, S.W.

1888 SUTTON, JOHN BLAND, F.R.C.S., 48, Queen Anne street, Cavendish square, W. *Council*, 1894-5. *Trans.* 2.

1894 SWALLOW, ALLAN JAMES, M.B., B.S. Durh., 5, Mount Edgecumbe gardens, Clapham rise, S.W.

1896 SWAN, CHARLES ATKIN, M.B., B.Ch.Oxon., 4, Devonport street, Gloucester square, W.

1893 SWAYNE, FRANCIS GRIFFITHS, M.A., M.B., B.C.Cantab., 4, Belvedere road, Upper Norwood, S.E.

1859*†SWAYNE, JOSEPH GRIFFITHS, M.D., Physician-Accoucheur to the Bristol General Hospital; Harewood House, 74, Pembroke road, Clifton, Bristol. *Council*, 1860-1, *Vice-Pres.* 1862-4. *Trans.* 9.

1892† SWAYNE, WALTER CARLESS, M.B. Lond., 3, Leicester villas, St. Paul's road, Clifton.

1888* SWORN, HENRY GEORGE, L.K.Q.C.P. & L.M., 5, Highbury crescent, N.

1883 TAIT, EDWARD SABINE, M.D., 48, Highbury park, N. *Council*, 1892-4. *Trans.* 1.

1879 TAIT, EDWARD W., 48, Highbury park, N. *Council*, 1886-7.

Elected

1871*†TAIT, LAWSON, F.R.C.S., Surgeon to the Birmingham and Midland Hospital for Women; 7, The Crescent, Birmingham. *Trans.* 15.

1880*†TAKAKI, KANAHEIRO, F.R.C.S., 10, Nishi-Konyachō, Kiōbashika, Tokio, Japan. *Hon. Loc. Sec.*

1859 TAPSON, ALFRED JOSEPH, M.B. Lond., 36, Gloucester gardens, Westbourne terrace, W. *Council,* 1862-4. *Vice-Pres.* 1891.

1891 TARGETT, JAMES HENRY, M.B., M.S. Lond., F.R.C.S., 6, St. Thomas's street, S.E. *Council,* 1895.

1892 TATE, WALTER WILLIAM HUNT, M.D.Lond., 57, Queen Anne street, Cavendish square, W. *Council,* 1895-7.

1871 TAYLER, FRANCIS T., B.A. Lond., M.B., Claremont villa, 224, Lewisham High road, S.E.

1869† TAYLOR, JOHN, Earl's Colne, Halstead, Essex.

1890*†TAYLOR, JOHN WILLIAM, F.R.C.S., Surgeon to the Birmingham and Midland Hospital for Women; Consulting Surgeon to the Wolverhampton Hospital for Women; 22, Newhall street, Birmingham. *Trans.* 1.

1892 TAYLOR, WILLIAM BRAMLEY, 145, Denmark hill, S.E.

1885† TAYLOR, WILLIAM CHARLES EVERLEY, M.R.C.P. Edin., 34, Queen street, Scarborough.

1894† TENCH, MONTAGUE, M.D. Brux., L.R.C.P. Lond., Great Dunmow, Essex.

1890† THOMAS, BENJAMIN WILFRED, L.R.C.P. Lond., Welwyn.

1887† THOMAS, WILLIAM EDMUND, L.R.C.P.Ed., 2, Station hill, Bridgend, Glamorganshire.

1867*†THOMPSON, JOSEPH, L.R.C.P. Lond., 1, Oxford street, Nottingham. *Trans.* 1. *Hon. Loc. Sec. Council,* 1896-7.

1878 THOMSON, DAVID, M.D., 33, Lowndes street, Belgrave square, S.W.

1879 THORNTON, J. KNOWSLEY, M.B., C.M., Surgeon to the Samaritan Free Hospital for Women and Children, 49, Montagu square, W. *Council,* 1882-3. *Hon. Lib.* 1884-5. *Hon. Sec.* 1886. *Vice-Pres.* 1888, 1893. *Trans.* 6.

Elected

1873* TICEHURST, CHARLES SAGE, Petersfield, Hants.

1866 TILLEY, SAMUEL, 32, West Kensington gardens, W.

1887† TINLEY, THOMAS, M.D. Durh., Hildegard House, Whitby.

1895† TINLEY, WILLIAM EDWIN FALKINGRIDGE, M.B., B.S. Durh., Hildegard House, Whitby.

1879† TIVY, WILLIAM JAMES, F.R.C.S. Ed., 8, Lansdown place, Clifton, Bristol.

1872† TOTOTSCHINOFF, N., M.D., Charkoff, Russia.

1884 TRAVERS, WILLIAM, M.D., 2, Phillimore gardens, W.

1893† TRETHOWAN, WILLIAM, M.B., C.M. Aber., care of Dr. MacWilliams, Perth, Western Australia.

1886† TUCKETT, WALTER REGINALD, Woodhouse Eaves, near Loughborough.

1865* TURNER, JOHN SIDNEY, Stanton House, 81, Anerley road, Upper Norwood, S.E. *Council*, 1893-4.

1891 TURNER, PHILIP DYMOCK, M.D.Lond., 44, Welbeck street, W.

1881† TUTHILL, PHINEAS BARRETT, M.D., Station Hospital, Gibraltar.

1861 TWEED, JOHN JAMES, F.R.C.S., 14, Upper Brook street, W. *Council*, 1896.

1890 TYRRELL, WALTER, L.R.C.P.Lond., 104, Cromwell road, S.W.

1893 UMNEY, WILLIAM FRANCIS, M.D.Lond., Heatherbell, 15, Crystal Palace park road, Sydenham, S.E.

1874* VENN, ALBERT JOHN, M.D., 70A, Grosvenor street, W.

1873* VERLEY, REGINALD LOUIS, F.R.C.P. Ed., St. George's Club, Hanover square, W.

1892† VERRALL, THOMAS JENNER, L.R.C.P.Lond., 97, Montpellier road, Brighton.

1879† WADE, GEORGE HERBERT, Ivy Lodge, Chislehurst, Kent. *Council*, 1892-3.

1894† WAGSTAFF, FRANK ALEX., L.R.C.P. Lond., Saffron Walden, Essex.

1860† WALES, THOMAS GARNEYS, Downham Market, Norfolk.

Elected

1894 WALKER, THOMAS ALFRED, L.R.C.P. Edin., Greville Lodge, Willesden park, N.W.

1866† WALKER, THOMAS JAMES, M.D., Surgeon to the General Infirmary, Peterborough; 33, Westgate, Peterborough. *Council*, 1878-80. *Hon. Loc. Sec.*

1889 WALLACE, ABRAHAM, M.D. Edin., 39, Harley street, W.

1870 WALLACE, FREDERICK, Foulden Lodge, Upper Clapton, N.E. *Council*, 1880-2.

1872*†WALLACE, JOHN, M.D., Assistant-Physician to the Liverpool Lying-in Hospital; 1, Gambier terrace, Liverpool. *Council*, 1883-5.

1883 WALLACE, RICHARD UNTHANK, M.B., Cravenhurst, Craven park, Stamford hill, N.

1893† WALLS, WILLLAM KAY, M.B. Lond., St. Mary's Hospital, Manchester.

1879*†WALTER, WILLIAM, M.A., M.D., Surgeon to St. Mary's Hospital, Manchester; 20, St. John street, Manchester.

1867*†WALTERS, JAMES HOPKINS, Surgeon to the Royal Berkshire Hospital; 15, Friar street, Reading, Berks. *Council*, 1884-6. *Trans.* 1. *Hon. Loc. Sec.*

1873† WALTERS, JOHN, M.B., Church street, Reigate, Surrey. *Council*, 1896-7.

1895 WARNER, FREDERICK ASHTON, L.R.C.P., 10, Brechin place, South Kensington, S.W.

1884† WAUGH, ALEXANDER, L.R.C.P. Lond., Midsomer-Norton, Bath.

O.F.† WEBB, HARRY SPEAKMAN, New place, Welwyn, Herts. *Council*, 1889-91. *Vice.-Pres.* 1892-4.

1893† WEBB, JAMES RAMSAY, M.B., B.S.Melbourne, 82, St. Vincent place south, Albert park, Melbourne.

1894† WEBB, JOHN CURTIS, M.A., M.B., B.C. Cantab., 16, Canning street, Liverpool.

1886† WEBBER, WILLIAM W., L.R.C.P. Ed., Crewkerne.

1893† WEBSTER, THOMAS JAMES, Brynglâs, Merthyr Tydvil.

1887† WELLS, ALBERT PRIMROSE, M.A., L.R.C.P. & S., L.M. 16, Albemarle road, Beckenham.

Elected

1876† WELLS, FRANK, M.D., 178, Devonshire street, Boston, Massachusetts.

1886† WEST, CHARLES J., L.R.C.P. Lond., The Grove, Fulbeck, Grantham.

1888† WESTON, JOSEPH THEOPHILUS, M.D.Brux., Civil Surgeon, Hissar, Punjab (care of Messrs. Thacker, Spink, and Co., booksellers and publishers, Government place, Calcutta).

1886 WHARRY, ROBERT, M.D. Aber., 6, Gordon square, W.C.

1890 WHEATON, SAMUEL W., M.D.Lond., Physician to the Royal Hospital for Children and Women; 52, The Chase, Clapham common, S.W.

1889† WHITCOMBE, CHARLES HENRY, F.R.C.S. Edin., 281, Queen's road, Halifax.

1890 WHITE, CHARLES PERCIVAL, M.A., M.B., B.C.Cantab., 144, Sloane street, S.W.

1890 WHITE, EDWIN FRANCIS, F.R.C.S., Westlands, 280, Upper Richmond road, Putney, S.W.

1882 WHOLEY, THOMAS, M.B. Durh., Winchester House, 50, Old Broad street, E.C.

1879† WILLANS, WILLIAM BLUNDELL, F.R.C.P. Ed., Much Hadham, Herts.

1894† WILLIAMS, JOHN D., M.D. Ed., B.Sc., 20, Windsor place, Cardiff.

1872 WILLIAMS, Sir JOHN, Bart., M.D., F.R.C.P., Physician-Accoucheur to H.R.H. Princess Beatrice, Princess Henry of Battenberg; Consulting Obstetric Physician to University College Hospital; 63, Brook street, Grosvenor square, W. *Council*, 1875-6, 1892, 1894. *Hon. Sec.* 1877-9. *Vice-Pres.* 1880-2. *Board Exam. Midwives*, 1881-2; *Chairman*, 1884-6. *Pres.* 1887-8. *Trans.* 12.

1890 WILLIAMS, REGINALD MUZIO, M.D.Lond., 95, St. Mark's road, N. Kensington, W.

Elected

1881 WILLIS, JULIAN, M.R.C.P. Ed., 64, Sutherland avenue, Maida vale, W.

1892† WILSON, THOMAS, M.D., B.S.Lond., F.R.C.S., Assistant Obstetric Physician at the General Hospital, Birmingham; 33, Paradise street, Birmingham.

1886† WINTERBOTTOM, ARTHUR THOMAS, L.R.C.P. Ed., Lark hill, Swinton, Manchester.

1896† WINTER, JOHN BRADBURY, L.R.C.P, 28, Montpelier road, Brighton.

1877 WINTLE, HENRY, M.B., Kingsdown, Church road, Forest hill, S.E.

1893 WISE, ROBERT, M.D.Edin., 5, Weston park, Crouch End, N.

1887† WITHERS, ROBERT, Stenteford Lodge, Spencer terrace, Lipson road, Plymouth.

1890 WORNUM, GEORGE PORTER, 6, College terrace, Belsize park, N.W.

1876† WORTS, EDWIN, 6, Trinity street, Colchester.

1887† WRIGHT, CHARLES JAMES, Senior Surgeon to the Hospital for Women and Children, Leeds; Professor of Midwifery to the Yorkshire College; Lynton Villa, Virginia road, Leeds.

1888*†WYATT-SMITH, FRANK, M.B., B.C.Cantab., British Hospital, Buenos Ayres.

1871 YARROW, GEORGE EUGENE, M.D., 26, Duncan terrace Islington, N. *Council*, 1881-3.

1882*†YOUNG, CHARLES GROVE, M.D., New Amsterdam, Berbice, British Guiana.

Number of Fellows . . 736

CONTENTS.

	PAGE
List of Officers for 1897	v
List of Presidents	vii
List of Referees of Papers for 1897	viii
Standing Committees	ix
List of Honorary Local Secretaries	x
Trustees of the Society's Property	xi
List of Honorary and Corresponding Fellows	xi, xii
List of Ordinary Fellows	xiii
Contents	lix
List of Plates and Illustrations	lxv
Advertisement	lxviii
Hours of Attendance at Library	lxviii

January 1st, 1896—

A Supposed Case of Tubo-ovarian Cyst, shown by Dr. CULLINGWORTH 1

Report on Dr. Cullingworth's Specimen of Supposed Tubo-ovarian Cyst 4

Placenta Velamentosa and an abnormally large Placenta, shown by Mr. A. F. STABB (for Dr. GRIFFITH) 4

Five Months' Fœtus and Placenta, from a Case of Twin Pregnancy in which the second child was delivered alive at or near full term along with the dead Fœtus, shown by Mr. G. G. GENGE (introduced by Dr. CULLINGWORTH) . . . 5

PAGE

Multiple Fibro-myomata of the Uterus, shown by Dr. CULLINGWORTH 6
Large Fibro-cystic Myoma growing from the Cervix Uteri, shown by Dr. CULLINGWORTH . . 8
Cancerous Uterus with Pyometra, shown by Dr. LEWERS 14
I. On the Influence of the Removal of the Ovaries on Metabolism in Connection with Osteomalacia, by Prof. J. E. CURATULO (communicated by Dr. GRIFFITH) 17
II. The Effects of Lactation on Menstruation and Impregnation, by Dr. LEONARD REMFRY . . 22

February 5th, 1896—
Annual Meeting 29
Solid Tumours, shown by Dr. LEITH NAPIER . 29
Report of Committee on Dr. Leith Napier's Specimen of Solid Ovarian Tumour 32
Slough forming a Complete Cast of the Vagina, from a Case of Enteric Fever, shown by Dr. W. S. PLAYFAIR 33
Ruptured Tubal Gestation, shown by Dr. W. S. PLAYFAIR 34
Unruptured Tubal Gestation, shown by Dr. DUNCAN 36
Large Double Tubo-ovarian Cysts, shown by Dr. DUNCAN 37
Intra-ligamentous Gestation retained for twenty-one years, shown by Dr. GALABIN . . . 38
Tubal Gestation ruptured at the sixth week, shown by Dr. GALABIN 39
III. Abdominal Hysterectomy with Intra-peritoneal Treatment of the Stump; with Notes of Eight Cases, by Mr. HARRISON CRIPPS . . . 41
Annual Meeting—The Audited Report of the Treasurer (Dr. POTTER) . . . 56, 57
—— Report of the Honorary Librarian for 1895 (Dr. PHILLIPS) 58
—— Report of the Chairman of the Board for the Examination of Midwives (Dr. CULLINGWORTH) . 59
—— Annual Address of the President (Dr. CHAMPNEYS) 60
—— Election of Officers and Council for the year 1896 84

PAGE

March 4th, 1896—

Report on Dr. Lewers' Specimen which was shown as a Tubal Mole on March 6th, 1895 . . 87

Report on Dr. A. L. Galabin's Specimen of Extra-uterine Gestation 88

Extra-uterine Fœtation not primarily Tubal, shown by Dr. GALABIN 91

Report on a Specimen of Fœtus Diprosopus Anencephalicus, shown by Dr. AMAND ROUTH in May, 1895 92

Fibroid Tumour and Cancer of the Uterus, shown by Dr. AMAND ROUTH 99

Independent Cancer of the Body and of the Cervix Uteri, shown by Dr. AMAND ROUTH . . 100

Ovarian Tumour containing Corpus Luteum, shown by Dr. GALABIN 101

Uterine Fibroid associated with Carcinoma, shown by Dr. GALABIN 102

Hydronephrosis of the Left Kidney, shown by Mr. J. SIDNEY TURNER 103

Deformed Fœtus with Cystic Tumour of Neck, shown by Dr. LEWERS 106

Chorionic Villi from a Tubal Mole removed by Abdominal Section, shown by Dr. LEWERS . . 106

Adjourned Discussion on Abdominal Hysterectomy . 107

April 1st, 1896—

A Speculum, shown by Dr. H. R. SPENCER . 117

Skiagram of a Sireniform Monster, shown by Dr. H. R. SPENCER 118

Sarcoma of Cervix Uteri, shown by Dr. GALABIN . 120

Myxo-sarcoma of Urethra in a child, shown by Dr. GALABIN 120

Microscopic Sections of Tissue removed from the Uterus, shown by Dr. GALABIN . . 121

Ruptured Tube and Three Weeks Embryo from the Sac of an old Pelvic Hæmatocele, shown by Dr. CULLINGWORTH 122

Notes of a Case of Malignant Disease of the Uterus with numerous deposits in the lungs, and death following an abortion, by Mr. MALCOLM . . 125

PAGE

IV. A Case of Deciduoma Malignum occurring in England, by Mr. J. RUTHERFORD MORISON . . 130
V. A Case of Deciduoma Malignum, by Dr. HERBERT R. SPENCER 135
VI. Deciduoma Malignum: a Criticism, by Dr. T. W. EDEN 149

May 6th, 1896—
Two Uteri removed by Vaginal Hysterectomy for Cancer of the Cervix, the disease being apparently at the same stage in each, shown by Dr. LEWERS . 164
Cystic Myoma of Uterus weighing over fifteen pounds, shown by Mr. ALBAN DORAN . . . 164
Placenta, Cord, Fœtus, and Membranes, shown by Dr. ROBERT WISE 166
Two Solid Ovarian Tumours, shown by Mr. MALCOLM 166
A Large Solid Ovarian Tumour, shown by Mr. MALCOLM 167
A Solid Ovarian Tumour, shown by Mr. MALCOLM . 167
A Simple Maieutic for the Induction of Miscarriage or Premature Labour, shown by Dr. HORROCKS . 168
Adjourned Discussion on Deciduoma Malignum . 171
Report of Committee on Mr. Rutherford Morison's and Dr. Spencer's Specimens of Deciduoma Malignum, and Mr. Malcolm's Specimen of Sarcoma of the Uterus 183

June 3rd, 1896—
Hydrosalpinx and Small Ovarian Cyst removed by Anterior Colpotomy, shown by Dr. AMAND ROUTH 185
VII. Cases of Fibroma of the Ovary and Ovarian Ligament removed by Operation; with a Series of After-histories of Cases reported in the 'Transactions' since 1879, by Mr. ALBAN DORAN . . 187
VIII. Anterior Colpotomy, by Dr. JOHN PHILLIPS . 213
IX. Case of Dermoid Ovarian Cyst impacted in the Pelvis which was removed by Abdominal Section during the Ninth Month of Pregnancy, by Mr. THOMAS H. MORSE 221

PAGE

July 1st, 1896—

Microscopical Sections of Uterus showing Chorionic Villi and Doubtful Sarcoma, shown by Dr. REMFRY 223

X. The Ætiology of Gonorrhœa, by Dr. J. McCANN . 225

XI. A Case of True Unilateral Hermaphroditism with Ovotestis occurring in Man, with a Summary and Criticism of the Recorded Cases of True Hermaphroditism, by Dr. G. F. BLACKER and Mr. T. W. P. LAWRENCE 265

October 7th, 1896—

Tubo-ovarian Abscess, shown by Dr. TATE . . 319

Fœtus Papyraceus, shown by Dr. W. RIVERS POLLOCK 320

Unreported Case of Primary Cancer of the Fallopian Tubes in 1847, with Notes on Primary Tubal Cancer, by Mr. ALBAN DORAN . . . 322

XII. Case of Double Uterus with Double Hæmatometra and Complete Absence of the Vagina, by Dr. LEWERS 327

November 3rd, 1896—

Five Specimens of Fibroid Tumour of the Uterus, removed by the Intra-peritoneal Method, shown by Dr. W. DUNCAN 345

Self-retaining Glass Retractors, shown by Dr. MACNAUGHTON-JONES 345

XIII. Case of completely Cleft Spine associated with an Unusual Visceral Malformation in an Anencephalic Fœtus, by Dr. T. G. STEVENS . . . 346

XIV. On the Structure of the Ripe Placenta, and the Changes which occur in Placentæ retained *in utero* after the Death of the Fœtus, by Dr. EDEN . 360

December 1st, 1896—

Tubo-ovarian Abscess, shown by Dr. TATE . . 380

Report of Committee on the above . . 380

Notes of a Case of Primary Epithelioma of Vagina, by Dr. C. HUBERT ROBERTS . . . 381

PAGE

Cast from the Uterus having all the Characters of the Decidual Membrane found in connection with Ectopic Gestation, together with a Small Ovarian Cyst from the same case, with Microscopic Sections of each, shown by Dr. DAKIN . . . 385

Entirely Detached Uterine Fibroid, shown by Dr. AMAND ROUTH 388

Monstrosity resulting from Amniotic Adhesion to Skull, shown by Dr. JOHN PHILLIPS . . 388

XV. Three Cases of Porro's Operation with Intra-peritoneal Treatment of the Stump, by Dr. H. R. SPENCER . 389

INDEX 425

ADDITIONS TO THE LIBRARY . . 443

PLATES.

PLATE		PAGE
I.	Notes of a case of Malignant Disease of the Uterus with numerous Deposits in the Lungs, and death following an abortion (Mr. JOHN D. MALCOLM):	
	Fig. 1.—Uterus	128
	Fig. 2.—Lung	128
II—V.	A case of Deciduoma Malignum (Dr. H. R. SPENCER)	148
VI.	A case of Circumscribed Sarcoma of the Uterus (Dr. LEWERS)	178
VII.	Decidual Tissue (Dr. GRIFFITH):	
	Fig. 1.—Normal Decidua . . .	184
	Fig. 2.—Section of Decidual Cast . .	184
VIII—XI.	True Unilateral Hermaphroditism (Dr. BLACKER and Mr. LAWRENCE):	
	Fig. 1.—From behind, very slightly larger than natural	270
	Fig. 2.—Left genital gland and appendages, from before, enlarged . . .	270
	Fig. 3.—Right genital gland (section parallel to long axis)	272
	Fig. 4.—Left genital gland (ovarian portion, section parallel to long axis) . .	272
	Fig. 5.—Left genital gland (ovarian portion, section parallel to long axis) . .	274
	Fig. 6.—Left genital gland (testicular portion, section parallel to long axis) . .	274
	Fig. 7.—Left genital gland (testicular portion, section parallel to long axis) . .	275
	Fig. 8.—Left genital gland (testicular portion, section transverse to long axis) . .	275
XII.	Primary Cancer of the Fallopian Tubes. Dr. Renaud, 1847 (Mr. ALBAN DORAN) . .	324

ILLUSTRATIONS.

PAGE

Report on a Specimen of Fœtus Diprosopus Anencephalicus, shown by Dr. AMAND ROUTH
- Fig. 1.—Fœtus Diprosopus Anencephalicus . 93
- Fig. 2.—Skull of Fœtus Diprosopus Anencephalicus (upper surface, natural size) . . . 95
- Fig. 3.—Ditto, ditto (under surface, natural size) . 96
- Fig. 4.—Spinal Columns and Pelvis of Fœtus Diprosopus Anencephalicus after Maceration (posterior surface, natural size) . . . 98

Skiagram of a Sireniform Monster (Dr. SPENCER) . . 119

A Case of Deciduoma malignum occurring in England (Mr. J. RUTHERFORD MORISON) 131

A Case of Deciduoma malignum (Dr. SPENCER)
- Fig. 1.—A section of the two Lungs placed side by side showing Secondary Growths, of which one is breaking down in the centre . . . 144
- Fig. 2.—The Uterus has been opened posteriorly, showing the Growths in the Body and Cervix: the lower part of the Body and the anterior wall of the Cervix are not affected by the growth . 144

A simple Maieutic for the Induction of Miscarriage or Premature Labour (Dr. HORROCKS)
- Fig. 1.—Smallest Maieutic, natural size) . . 168
- Fig. 2.—Maieutic fixed on the end of a Catheter . 168
- Fig. 3.—Maieutic in position with the tubing tied and cut short 169

A Case of completely cleft Spine associated with an unusual Visceral Malformation in an Anencephalic Fœtus (Dr. T. G. STEVENS)
- Fig. 1.—Anencephalic Fœtus . . . 347
- Fig. 2.—Outline drawing showing intestinal malformation 349
- Figs. 3 and 4.—Two views showing the cardiac malformation 352

On the Structure of the Ripe Placenta, and the changes which occur in Placentæ retained *in utero* after the death of the Fœtus (Dr. EDEN)

PAGE

Fig. 1.—Eight Months' Placenta, retained two to three weeks 366
Fig. 2.—Five Months' Placenta, retained about eight weeks 370
Fig. 3.—Another portion of the same Placenta as Fig. 1 372
Fig. 4.—Four Months' Placenta, probably retained for twelve weeks 373
Fig. 5.—From the same specimen as Figs. 1 and 2 . 373
Fig. 6.—From the same specimen . . . 373

Three Cases of Porro's Operation, with Intra-peritoneal Treatment of the Stump (Dr. HERBERT R. SPENCER)

Fig. 1.—Pelvis with several enchondromata, showing the relations of the Tumour and the Dilated Ureters 409
Fig. 2.—A sagittal section of the Pelvis and Tumour 409
Fig. 3.—Diagram (made carefully to measure, half size) showing the relation of the Tumour, Rectum, Uterus, and Bladder at the Pelvic Brim in Case 2 410

ADVERTISEMENT.

THE SOCIETY is not as a body responsible for the facts and opinions which are advanced in the following papers and communications read, nor for those contained in the abstracts of the discussions which have occurred at the meetings during the Session.

20, HANOVER SQUARE, W.

LIBRARY AND MUSEUM,

20, HANOVER SQUARE, W.

Hours of Attendance: Monday to Friday, 1.30 p.m. to 6 p.m.; Saturday, 9.30 a.m. to 2 p.m.; and in the Evenings on which the Society meets, from 7.15 p.m. to 7.45 p.m.

AGNES HANNAM,
Secretary and Librarian.

OBSTETRICAL SOCIETY

OF

LONDON.

SESSION 1896.

JANUARY 1st, 1896.

F. H. Champneys, M.A., M.D., President, in the Chair.

Present—24 Fellows and 5 visitors.

The Medical Society presented the volume of its 'Transactions' for 1895.

The following five gentlemen were elected Fellows :—John Lewis Brown, M.B., C.M.Edin.; Walter Sidney Sheppard, B.A., M.B., B.Ch.Cantab.; John Bradbury Winter, L.R.C.P.Lond. (Brighton); R. T. Nariman, M.D.Brux. (Bombay); Charles Atkin Swan, M.B., B.Ch.Oxon.

A SUPPOSED CASE OF TUBO-OVARIAN CYST.

Shown by Charles J. Cullingworth, M.D.

The specimen exhibited was removed by operation a week previously from a healthy-looking woman aged thirty-

one, and consisted of a unilocular cyst with which a Fallopian tube communicated by an opening large enough to admit a lead pencil. The cyst measured in its collapsed state 5 inches in diameter. On its inner surface were several wart-like projections, and a few smaller growths of a similar kind were seen on its exterior. Ovarian tissue, showing distinct Graafian follicles, was found flattened out on one portion of the cyst wall. The cyst contents consisted of 32 fl. oz. of a fairly clear greenish-yellow fluid, acid in reaction, of sp. gr. 1030, and containing a sufficient amount of albumen to cause it to become solid on being boiled. The Fallopian tube was dilated and elongated, its diameter varying from ½ inch to ⅝ inch. The walls were not thickened. The divided uterine end presented a normal appearance. The inner surface of the cyst had a distinctly red colour over an area, 1 inch in diameter, surrounding the aperture of communication with the tube. Projecting folds of mucous membrane radiated outwards from the opening over this area.

The patient had been thirteen years married, and had never been pregnant. Menstruation commenced at the age of twelve, and had been painful from the first. Since marriage the pain had been more severe than before. There was no history of any inflammatory attack or other acute illness. The abdomen had been noticed to be increasing in size for nearly twelve months, but a distinct swelling was only discovered two months ago. For some days there had been a dragging pain at the end of the act of micturition, but this symptom had not persisted. For the past few weeks the swelling itself had been the seat of an aching pain.

The cyst caused some prominence of the lower part of the abdomen, where it occupied a central position.

On bimanual examination the uterus was found much anteverted and pressed forwards by a tense cystic swelling, equal in size to a fœtal head, that occupied the posterior part of the pelvis, resting on and being adherent

to the posterior surface of the uterus. When upward pressure was made upon the cyst, it was felt to drag upon the right broad ligament.

A sound passed into the bladder met with immediate resistance in the middle line. It could be made to pass easily to the normal distance (4 inches) when the instrument was directed to the right. When directed to the left it passed little more than half that distance.

At the operation the cyst was found to be connected with the uterus by the right ovarian ligament and to be densely adherent to the anterior wall of Douglas's pouch. This adhesion was broad, thick, and so firm as to resemble a band of fascia. A portion of the Fallopian tube, dilated and flaccid, lay stretched over the surface of the tense cyst and was thought at first to be an adherent coil of small intestine. The bladder was dragged over to the right, owing apparently to the development of the cyst in appendages that were already bound down deeply behind the uterus by adhesions. The left appendages were adherent, but otherwise normal.

Dr. Cullingworth suggested that a small committee should be appointed to examine and report upon the specimen.

Mr. Alban Doran remarked that it was not easy to distinguish a tubo-ovarian cyst from a large hydrosalpinx at an operation. The surgeon could not be always sure that he had removed the ovary. In an old hydrosalpinx the outer part was bent on the uterine half of the tube. The former became so dilated that the plicæ were effaced by pressure. In the uterine half the plicæ remained perfect. At the point where it opened out into the dilated part the plicæ protruded as fimbriæ. Hence a false ostium was developed, but it was often taken for the true ostium, so that the dilated part of the tube was mistaken for a cystic ovary. Mr. Doran had demonstrated the usual, if not the only manner in which true tubo-ovarian cysts developed in 1887 ('Trans. Path. Soc.,' vol. xxxviii). An inflamed cystic ovary simply fused with a hydrosalpinx. Mr. Bland Sutton said in his 'Surgical Diseases of the Ovaries,' p. 121. "Ovarian hydroceles must not be confounded with tubo-ovarian cysts," But the error was common through a misconception of Mr. Sutton's theory on the rarer condition.

A sub-committee consisting of Messrs. A. Doran and J. Bland Sutton, with Drs. Griffith and Cullingworth, was appointed to examine and report upon this specimen.

Report on Dr. Cullingworth's Specimen of Supposed Tubo-ovarian Cyst.

THE tumour is a large dilated tube or hydrosalpinx. Tissue which appears to be ovarian is seen on the outer surface of the dilated portion.

The outer part of the tube is dilated so abruptly as to simulate an ovarian cyst communicating with the tubal canal.

W. S. A. GRIFFITH.
CHAS. J. CULLINGWORTH.
J. BLAND SUTTON.
ALBAN DORAN.

PLACENTA VELAMENTOSA AND AN ABNORMALLY LARGE PLACENTA.

Shown by A. F. STABB, Esq., for W. S. A. GRIFFITH, M.D.

1. *Placenta velamentosa* from a patient delivered in Queen Charlotte's Hospital. The specimen was of interest in showing the liability to hæmorrhage during labour of fœtal origin in such cases; there was none in the present instance, but the tear in the membranes extended right up to one of the large venous trunks. Labour was perfectly natural, and there was nothing abnormal in the placenta itself, or in the quantity of liquor amnii. The membranes had ruptured naturally twenty-four hours before admission to hospital. Mother and child both did quite well.

2. *Abnormally large placenta*, weighing 3 lbs., also from a patient delivered in Queen Charlotte's Hospital.

Patient had had six full-time children, and one stillborn six-months' fœtus sixteen months ago. No history of syphilis. When admitted she was seven months pregnant, had not felt fœtal movements for eight days, and had some œdema of legs with traces of albumen.

The liquor amnii was large in amount and dark-coloured, but was quite sweet.

The fœtus was peeling, discoloured, and with distension of abdomen by fluid and gas; it weighed 4 lbs. 12 oz. The placenta was expressed ten minutes after birth of the child. The loss was only about ℥x, cord very œdematous, placenta uniformly pale, very friable and œdematous. The membranes were normal.

The patient made a good recovery, and the albumen and swelling of legs disappeared within two days after delivery.

FIVE MONTHS' FŒTUS AND PLACENTA, FROM A CASE OF TWIN PREGNANCY IN WHICH THE SECOND CHILD WAS DELIVERED ALIVE AT OR NEAR FULL TERM ALONG WITH THE DEAD FŒTUS.

Shown by G. G. Genge (introduced by C. J. Cullingworth, M.D.).

Mr. Genge, Junior Obstetric House Physician at St. Thomas's Hospital, showed a specimen consisting of a female fœtus that had died about the end of the fifth month of gestation, and had been retained *in utero* until its twin brother had approached full term, or at least had reached a viable age. The dead fœtus had been compressed against the uterine wall. The arms, legs, and head were com-

pletely flattened. The compression having been lateral, the profile of the face was preserved, and the head had assumed the form of a shallow cup, the right side of the head forming the hollow of the cup and the left its outer surface.

The length of the fœtus was 10 inches. It lay in a separate amniotic sac, and had a separate umbilical cord. The placenta was common to the two fœtuses. The umbilical cord of the dead fœtus and the portion of placenta to which it was attached were thin and ill-developed.

The mother was twenty-eight years of age, and had been married four years. This was her first pregnancy. At the labour the thorax of the dead fœtus was the first part to come within reach of the examining finger. When the dead fœtus had been expelled by a process resembling that of spontaneous evolution, the bag of membranes containing the second child protruded. This child, a male, presented by the vertex, and delivery proceeded normally, the child, though measuring only 16½ inches in length, being alive and well formed, and the placenta and membranes being subsequently expelled in the usual manner.

The patient stated that during the three weeks preceding labour she had had a watery blood-stained discharge from the vagina. It seemed probable that this marked the date of rupture of the first bag of membranes.

MULTIPLE FIBRO-MYOMATA OF THE UTERUS.

Shown by C. J. Cullingworth, M.D.

The specimen consisted of a symmetrically enlarged uterus divided longitudinally, and showing in section from thirty to forty hard fibro-myomata in the muscular tissue.

The tumours varied in size from that of a pea to that of a hen's egg, and the surrounding muscular tissue was greatly hypertrophied. The uterine cavity was much dilated. At the lower part of the specimen (which had been removed above the vaginal insertion of the cervix on November 20th by abdominal hysterectomy) several tumours of about the size of a pigeon's egg were seen projecting from the outer surface of the main mass. These had been enucleated from between the folds of the broad ligaments and other pelvic tissues, into which they had burrowed. The mass measured 7 inches in length, 7 inches in width, and 4½ inches in depth antero-posteriorly. The length of the uterine canal was 5 inches. The weight of the mass was 5 lbs. A water-colour drawing of the specimen in its fresh state was exhibited with the preparation.

The patient was a lady aged 43, who had been married fifteen years, and had never been pregnant. She had menstruated profusely during the whole of her married life, and for the last seven years had been a confirmed invalid, spending at least five days of every month in bed on account of the excessive and increasing monthly loss. She was extremely anæmic, and her mental condition was unsatisfactory. Considering that some years must elapse before the menopause it was thought right to place before her the chance of cure by operation. The immediate risk was explained, and after consultation with her friends she decided to face it.

The operation was performed by what is known as Baer's method, and presented no special difficulties except such as were caused by the burrowing of outgrowths in the surrounding tissues.

Convalescence proceeded satisfactorily for five days and there seemed every prospect of a successful issue. But on the morning of the sixth day the patient became suddenly collapsed, and died in a few hours. At the post-mortem examination no cause for the collapse was discovered. There was no hæmorrhage, or peritonitis, or

evidence of septicæmia. The descending colon and rectum were collapsed and empty; the intestine above was slightly distended, but not sufficiently so to cause any marked fulness of the abdomen.

The result was extremely disappointing and difficult to account for.

The specimen was exhibited, however, not so much on account of the clinical as of the pathological interest of the case, it being unusual to find such a symmetrical enlargement of the uterus due to a number of small tumours.

Dr. Duncan asked what were the reasons in this particular case which made Dr. Cullingworth prefer the more serious operation of hysterectomy to removal of the appendages: were the appendages closely adherent to the uterus, so that their removal would have been very difficult, if not impossible? Otherwise Dr. Duncan considered that in the case of a tumour of the size shown, and where, as stated, some of the fibroids had penetrated into the broad ligaments, it was hardly justifiable to expose a patient to the increased risks attaching to hysterectomy.

LARGE FIBRO-CYSTIC MYOMA GROWING FROM THE CERVIX UTERI.

Shown by C. J. Cullingworth, M.D.

The specimen exhibited was a mounted spirit preparation. It consisted of a portion of a large fibro-cystic uterine myoma of unusual shape, removed by abdominal section along with the body of the uterus and the uterine appendages on September 19th, 1895. The tumour measured 10 inches in length, and when drained of most of its fluid weighed 6 lbs. 11½ oz. It filled the cavity of the pelvis, besides forming an abdominal tumour that reached to the ensiform cartilage. It sprang from the upper part of the posterior surface of the supra-vaginal

portion of the cervix, its attachment consisting of a transverse band of tissue just below the junction of body and cervix. The body of the uterus was of normal size, and with the appendages (which were healthy) lay in front of the tumour. The portion of the growth that extended downwards was solid, and formed a cast of the pelvic cavity, equal in size to an adult fist. It had distended the pouch of Douglas and displaced the body of the uterus upwards into the abdominal cavity. The upper part of the tumour, connected with the lower part by a constricted portion, was much the larger of the two. It extended upwards to the ensiform cartilage in the middle line, and almost to the costal margins laterally. On the anterior and upper surfaces there were a number of thin-walled cysts, containing serous fluid mixed with blood. The cysts varied in size from that of a hazel-nut to that of a hen's egg. On section of the mass cysts were found in the deeper portions of the tumour, but these were fewer in number and of smaller size than those near the surface.

The patient was a single woman aged 49, of dark complexion, short stature (five feet), and spare habit. She had commenced to menstruate at the age of eighteen, and had always been regular, with the exception of six months' amenorrhœa at the age of twenty-three. There had never been any increase in the quantity or duration of the flow. The catamenia appeared for the last time in March, 1895.

The patient's health had been excellent up to eighteen months ago, when she first began to suffer from abdominal pain and from piles. About twelve months ago she first discovered a lump, but she had not noticed any marked enlargement of the abdomen until the last six months, during which time its size had increased rapidly. During the same period there had been a good deal of pain in the umbilical region and about the rectum. There had been no pain or difficulty, however, in regard either to micturition or defæcation. The abdomen was symmetrically

distended by the presence of a large centrally situated and ill-defined swelling, in the upper portions of which there was evidence of the presence of fluid. On vaginal examination the uterus was found displaced upwards, the vaginal portion of the cervix being obliterated and the os being on a level with the top of the symphysis pubis. The sound passed the normal distance. In the pouch of Douglas was a firm, smooth, solid mass, equal in size to a man's fist, attached to the back of the cervix uteri, and growing downwards from it.

From the rapid growth and cystic nature of the tumour, from the absence of any evidence of enlargement of the uterine cavity, and from the fact that, so far from there having been any menorrhagia, the tumour had only assumed its present alarming proportions since the occurrence of the menopause six months ago, the probabilities were thought to be in favour of the disease being ovarian. Immediately on opening the abdomen, however, it was obvious that the tumour was a fibro-cystic myoma, and that the signs of fluctuation had been due partly to localised collections of ascitic fluid, and partly to a number of thin-walled superficial cysts in the tumour itself. It was further obvious that, notwithstanding the formidable nature of the undertaking, an attempt must be made to remove the tumour. Fortunately the dependent portion had contracted no adhesions in the pelvis, and was raised out of Douglas's pouch without any difficulty. With as little delay as possible the broad ligaments were tied and divided, the uterine arteries were secured, and the mass was cut away and removed, along with the body of the uterus and the uterine appendages. Peritoneal flaps were formed of sufficient length to allow of their being turned in and united over the cervical stump. There was a good deal of bleeding from the ruptured cysts of the tumour; and this loss, added to the shock of the operation, resulted in syncope, which unfortunately proved fatal about half an hour after the patient had been put back to bed.

The specimen had been brought before the Society as

presenting several points of interest, especially the entire freedom of the body of the uterus from implication in the disease, and the fact that so far from the menopause having had the effect of arresting the growth, it had apparently stimulated it to an increased rapidity of development. There could be no doubt that the proportion of cases in which uterine myomata continued to grow, and even underwent dangerous developments, after the menopause was much larger than was generally acknowledged.

Recent inquiries into this subject, both in Germany and in our own country, tended to show that we were not justified in holding out promise of relief to symptoms on the occurrence of the menopause in the sanguine manner to which we had been accustomed. Such promises must be made with much reservation. The behaviour of uterine myomata after the menopause was a subject that was at present exercising the minds of all who were engaged in the treatment of these tumours, and that stood urgently in need of further investigation.

Dr. Duncan asked if the cysts were examined microscopically especially with reference to their being lined or not with endothelium, and if Dr. Cullingworth had formed an opinion as to their mode of origin.

Dr. Heywood Smith asked if in this case of fibro-cysts there was any history as to the duration or existence of the tumour and its consistency, as it would be interesting to know whether the cystic formation was a recent development. With regard to the case that died, he would like to know whether the pulmonary artery was examined, as in a case of his many years ago after hysterectomy the patient did perfectly well, and was sitting up in bed, and just after her dinner fell back and died in a few minutes from embolism of the pulmonary artery.

Dr. Herman thought it important that the structure of Dr. Cullingworth's tumour should be recorded. Mr. Lawson Tait had stated that soft fibroids grew after removal of the ovaries, and after the menopause. There was no doubt that soft fibroids grew after the menopause. But did the hard nodulated fibroids? If not, the character of the fibroid was an important point in prognosis.

Dr. Lewers doubted whether there was a great deal of difference between the mortality of removing the uterine appendages for uterine fibroid, and that of abdominal hysterectomy

by Baer's method with intra-peritoneal treatment of the pedicle. American statistics showed the mortality of the latter operation to be a very low one. On the other hand, he remembered Mr. Knowsley Thornton laying stress on the point that removing the uterine appendages for fibroids was not to be regarded as so very slight an operation.

The PRESIDENT said that no mere figures would settle the question whether oöphorectomy or hysterectomy were the proper operation for cases of fibroid. On the one hand, there were the cases in which the fibroid grew well into the peritoneal cavity, and offered a pedicle which might be treated with little more difficulty than that of an ovarian tumour. On the other hand, the enucleation of a large fibroid out of the broad ligament was apt to be accompanied with very alarming and even fatal shock. Two such catastrophes had happened in the past week or two to patients of his own. On the other hand, oöphorectomy, which was in simple cases the simplest of operations, might become difficult and even dangerous. He had repeatedly seen the greatest difficulty in removing the appendages on account of the expansion of the broad ligament by the tumour, depriving the ovary of its pedicle. In such cases a ligature often tore the platysma, and bleeding ensued, which nothing but hysterectomy would arrest. In former years, when hysterectomy was less well understood, the unintended extirpation of the uterus had often, under such circumstances, ended fatally. Each case must be considered on its own merits.

Dr. CULLINGWORTH, in reply, said he was pleased that his specimens had evoked so much interest and so useful a discussion. He was unfortunately not able to supply Dr. W. Duncan with an account of the microscopical appearances in the case of the fibro-cystic myoma, but it was the impression of both Mr. Shattock and himself that the fluid-containing cavities in the tumour were not true cysts. He was grateful to Dr. Heywood Smith for giving him an opportunity of repairing an important omission in his notes of the post-mortem examination. He had had in his mind the possibility of pulmonary embolism, and with that in view he had the heart and great vessels examined very carefully. The results were entirely negative. He entirely concurred in the remarks made by Dr. Herman as to the importance of carefully recording all cases in which fibro-myomata continued to grow after the menopause, and he would undertake to furnish, for publication in the Society's 'Transactions,' a full account of the case he had narrated briefly that evening. He had no doubt that a change was impending in the attitude of the profession towards uterine myomata, and that a fuller knowledge of their behaviour at and subsequently to the menopause would be an important factor in determining the direction of that change.

He was surprised to hear Mr. Bland Sutton express doubts as to the rarity of finding a large number of small, hard fibroids in a symmetrically enlarged uterus. His (Dr. Cullingworth's) impression was that it was more usual under such circumstances to find a single large tumour; but that impression might be erroneous, and he would take an early opportunity of looking into the matter now that Mr. Sutton had called his attention to it. He was glad that Dr. Griffith had spoken of the dilated condition of the uterine cavity in the specimen last exhibited. He had accidentally omitted to refer to it in his description. Dr. Griffith had suggested that at the time of the operation the cavity was probably filled with blood. That was not so, however. It was quite empty.

Drs. W. Duncan and Spencer had inquired why, in this last case, the operation of oöphorectomy had not been performed in preference to hysterectomy. The remarks of Dr. Lewers furnished the answer to that question. Now that the technique of the operation of hysterectomy had been so greatly improved, and its mortality so much diminished, the reasons for preferring oöphorectomy to the more radical operation, where the two were equally practicable, no longer existed. There was still ample scope for the operation of oöphorectomy in those cases in which, surgical relief of some kind being urgently called for, the removal of the tumour itself is either impracticable or likely to be attended with special difficulty or risk. The palliative operation found perhaps its most useful application in the case of burrowing intra-pelvic tumours, where operative proceedings are called for on account of pressure symptoms. In the majority of cases, however, in which oöphorectomy would a few years ago have been very properly preferred, the proper operation to-day was hysterectomy. In the last volume of the 'St. Thomas's Hospital Reports' he had published full details of all his cases of oöphorectomy for uterine myoma, twenty in number, with a table and analytical notes. The majority of his cases had been completely successful, but in two cases the operation proved fatal, showing that it ought not to be regarded as in any sense a slight or minor operation.

There were some further considerations it was necessary to bear in mind in comparing the two operations. Let them take, for example, the mental effect upon the patient. There was a vast difference between the feelings of a person who, having nerved herself to go through the ordeal of a formidable operation, awakes from the anæsthetic and finds the tumour still there, and the feelings of one who, under similar circumstances, awakes and finds the tumour gone. Then, again, the relief to symptoms was usually less prompt in oöphorectomy. Months often elapsed before it was very marked. Even where relief

came more quickly, it not unfrequently proved transient; the troublesome symptoms returned.

There was a difference, too, in regard to the character of the convalescence. The patient after an abdominal hysterectomy, performed in the way now generally recommended and practised, had ordinarily as smooth and uneventful a convalescence as in the normal convalescence after delivery. Not so was it with the oöphorectomy patient. The convalescence was seldom free from interruption, and not uncommonly was attended with symptoms that caused grave anxiety.

For these reasons, and because it must always be a more satisfactory thing to remove the disease than merely to endeavour to influence it indirectly, oöphorectomy must be considered an inferior operation to hysterectomy. Hitherto the high mortality of hysterectomy had been a bar to its general acceptance; but now that the mortality, owing to simplification of methods, had become so greatly reduced, there was no doubt at all in his mind that it ought to be performed in preference to oöphorectomy in every case in which there were no special indications to the contrary. Not that we were in a position as yet to let hysterectomy displace oöphorectomy altogether. The latter operation still remained a most valuable addition to our resources, and in certain cases was the only operation feasible. It was impossible to be certain before the abdomen was opened as to the exact nature of the conditions present. Hence it was most wise, as the President had suggested, to undertake an operation for uterine myomata only on the understanding that one had a free hand, and was at liberty to select whichever of the two operations seemed best when the actual conditions were known and the parts exposed to view.

It had been said that the tumour in this particular case was not large enough to justify the more radical operation. With that opinion he was unable to agree.

CANCEROUS UTERUS WITH PYOMETRA.

Shown by Arthur H. N. Lewers, M.D.

Dr. Lewers showed a specimen of large pyometra in a case of cancer of the cervix in which he had performed vaginal hysterectomy. The patient was a lady fifty-five

years old, in whom the menopause had occurred five years previously. Before the operation the large size of the body of the uterus gave rise to some doubt as to whether there might not be cancer of the body of the uterus as well. Dr. Lewers, however, started with the intention of performing the supra-vaginal amputation if that seemed sufficient. During the operation the whole field was suddenly inundated with extremely fœtid pus coming from the body of the uterus through an opening about the level of the internal os, probably caused by tearing from the traction employed in pulling the uterus down. There must have been at least half a pint of pus, probably more than that. Dr. Lewers decided to remove the whole uterus.

This was not a very easy matter, as the body was so large. Before the operation there had been slight fever, but afterwards there was no rise of temperature, and the patient made an uninterrupted recovery, notwithstanding the fact that the peritoneum in the neighbourhood of Douglas's pouch must have been soiled by the fœtid pus. He ascribed the absence of trouble on this account to the complete drainage that occurs naturally under the circumstances in such cases.

Dr. Duncan was very glad to hear from Dr. Lewers' lips that he now considered the mortality of supra-vaginal amputation and that of complete removal to be practically the same, and he felt little doubt that ere long Dr. Lewers would, with his altered views as to the mortality of the two operations, give up performing amputation, when he could remove the whole of a cancerous uterus with no more risk to the patient. With regard to Dr. Lewers' remark that more of his cases of supra-vaginal amputation lived longer without recurrence of the growth than those in which he removed the whole organ, Dr. Duncan again pointed out that this fact was of no value whatever, as Dr. Lewers had admitted that the cases in which he extirpated the whole organ were of a more advanced nature, and therefore probably the extra-uterine tissues were infiltrated with cancer.

Dr. Griffith stated that he had at different times exhibited to the Society specimens which to some extent defined the circumstances under which blood, pus, or mucus would be found in a uterus after closure of the cervical canal. He had demonstrated that if the cervix was closed by any cause during

menstrual life, hæmatometra was the result; if after the climacteric, hydrometra would be found unless the cause of the closure was cancer, then pyometra. The occasional presence of purulent endometritis before the closure of the cervix would, of course, modify the result. It must be remembered that a marked dilatation of the uterine cavity occurs not rarely without any recognisable degree of stenosis of the cervix.

ON THE INFLUENCE OF THE REMOVAL OF THE OVARIES ON METABOLISM IN CONNECTION WITH OSTEOMALACIA.

By Prof. J. Emilio Curatulo, Rome (communicated by Dr. W. S. A. Griffith).

(Received August 12th, 1895.)

In a preliminary note kindly communicated to the Edinburgh Obstetrical Society by Dr. Freeland Barbour, and by myself to the Royal Medical Academy at Rome, I have only called attention to one fact of modified metabolism after the removal of the ovaries, which seemed to be of no small importance in explaining the useful therapeutical aid which is afforded in cases of osteomalacia by the removal of the ovaries. The starting-point of our researches was the now undisputed clinical fact that patients suffering from osteomalacia can be cured by castration. But the different theories propounded to explain the fact were not based upon arguments having their foundation in strict scientific research. Also Fehling's hypothesis, according to which by removal of the ovaries a *stimulus* is removed, which acting on the vaso-dilator nerves of the bones would cause passive hyperæmia, an accumulation of carbonic acid, and consequently re-absorption of earthy salts, was an hypothesis that might appear ingenious and perhaps even be true, but it cannot be said to be supported by indisputable facts scientifically proved.

On the other hand, we know Petrone's studies from Naples, tending to demonstrate that the good effects upon the disease are only due to the chloroformisation rather

than to the removal of the ovaries, thinking that the chloroform would kill the *fermentum nitricum* that this observer maintains to be the cause of the disease.

It seemed to me that an accurate and profitable study upon the action of the removal of the ovaries in cases of osteomalacia could not be made without first studying the changes which take place in metabolism after castration in healthy conditions. It is a well-known fact of rural economy that animals when castrated get fat; but a scientific investigation for the purpose of ascertaining the reason of this abnormal accumulation of fat in the system, and the eventual changes in metabolic activity of respiration and composition of urine after such operation has never been accomplished.

Professor Curatulo then refers to the experiments on bitches made by him, and recorded by him in the 'Transactions of the Obstetrical Society of Edinburgh,' vol. xx, p. 123. He found that after the removal of the ovaries the quantity of phosphoric anhydride excreted in the urine is greatly and for a considerable time diminished, while the quantity of nitrogen remains unaltered. The diminution of phosphates begins about the seventh day, and continues for three or four months.

He regards this as being the result of a diminished oxidation of phosphorus, existing as an organic compound in the tissues, and which, combining with calcium and magnesium, is stored in the bones. He supposed that the ovaries have, like other glands of the animal economy, according to the general doctrine of Brown-Séquard, a kind of internal secretion,—that is to say, that they continually introduce into the blood a secretive product, the chemical constitution of which is still unknown, capable of facilitating the oxidation of the phosphoric organic substances which supply the material for forming the salts of the bones. It results, therefore, that by the removal of these glands there must be a greater retention of organic phosphorus, consequently a greater accumulation of earthy salts in form of phosphates until the skeleton finally resumes its normal solidity.

Experiments performed after the publication of that preliminary note have proved that the theory we had pointed out was right. Under the skin of bitches, in which after

castration the discharge of phosphates through the urine was considerably diminished, we have injected a quantity (10—40 c.c.) of ovarian glycerine juice, and we observed that the quantity of phosphates eliminated the next day was really increased. When we injected a greater quantity of ovarian juice the amount of phosphates discharged the next day through the urine was very remarkable. We have begun to make the same experiments on dogs, and we found in them the same result. That the sexual glands must have an influence in moderating the development of the skeleton is proved not only by these researches, but by the fact that all giants described by anatomists have been found to have atrophied testicles. All the eunuchs that sing in the Sistine Chapel in Rome I have observed have a skeleton remarkably developed.

In order to study the changes in the metabolic activity of respiration after castration researches have been performed on little mice (*Mus musculus*). It is not very easy to find in these little animals the ovaries in the beginning, and to perform the castration, but after studying some topographic anatomy of the ovarian region it is not very difficult to succeed. It is a fact worthy to be mentioned that these little animals have a great resistance for a long operation, and their peritoneal cavity is not easily infected. I kept them also on constant diet, to study the changes on the metabolism of respiration. I used an ingenious apparatus invented by my friend Professor Luciani, Professor of Physiology in the University of Rome. I have observed that the quantity of carbonic anyhydride eliminated after the removal of the ovaries is diminished. This diminution of the carbonic anhydride might give us the key in order to explain the abnormal accumulation of fat in the system after castration, and we could admit a similar influence of the ovaries on the oxidation of the adipogenous substances. But one might ask whether this diminution in the elimination of carbonic anhydride is due to the removal of the sexual glands (a secretive product, capable of facilitating the oxidation of adipogenous sub-

stances), there being therefore no more introduced into the blood, or if this diminution is due to the fact that animals after castration become calm and quiet, and consequently eliminate less carbonic anhydride. In order to prove Petrone's theory, according to which the osteomalacia is due to a nitrification of the system caused by the *fermentum nitricum,* I have injected in dogs pure cultures of *Bac. radiciculæ,* which Winogradsky has demonstrated to be one of the organisms which produce the nitrification in the soil, and that my friend Dr. Plimmer from London kindly sent to me; but the experiments have till now given no results.*

Dr. Amand Routh thought that one of the great values of this paper was the new method by which Professor Curatulo had endeavoured to explain the action of the ovarian "internal secretion." Previously efforts had been made without result to chemically test the efferent as compared with the afferent blood of the ductless glands; and the experimental method of removal of the gland, and noting the effect upon the individual, as had been so successfully done in the case of the thyroid, had yet entirely failed to explain the method of its action. There are at least five ductless glands in addition to the ovary, the "internal secretion" of which was known to influence the system. Thus certain forms of splenic enlargement are associated with leucocythæmia, supra-renal hypertrophy with Addison's disease, atrophic thyroid with myxœdema, persistent thymus, and hypertrophic thyroid with Graves' disease, and hypertrophy of the pituitary gland with acromegaly. These are clinical facts at present more or less inexplicable, but it is not improbable that Dr. Curatulo's method of examining the urinary excretion may, as in the cases now under discussion, be the means of arriving at an explanation, especially in the instance of acromegaly, where bone tissue was also involved.

Dr. Griffith was of opinion that the valuable contribution to the study of mollities ossium by Professor Curatulo should not lead us to take too narrow a view of the subject. It is exceedingly unlikely that the ovaries had more than a very unimportant *rôle* in connection with the disease in women, and they could hardly be expected to influence it in men. He would be able to assist Mr. Bland Sutton in his endeavours to discover cases in London; for it was a curious fact that while the disease on the Continent was reported to be one of the child-bearing age in

* These researches have been performed in collaboration with Dr. Carulli in the Physiological Laboratory of the Royal University of Rome.

women, in London it appeared to be almost unknown except in advanced age, and the specimens he had obtained were from the dissecting room at St. Bartholomew's Hospital. One of these is illustrated in the 'Transactions' of the Society, vol. xxvi, p. 230. Again, there is another class of cases occurring in childhood to which little attention has been directed; he had found specimens, notably one in the museum of St. George's Hospital (Mr. Targett reminds him of another at Guy's), described as rachitic, but with all the characters of mollities ossium. The influence of the ovaries at both of these periods of life would need careful investigation.

Dr. DUNCAN pointed out that when children were the subjects of severe and early rickets a condition analogous to osteomalacia was sometimes met with ("pseudo-osteomalacia"), but that the disease was totally different from that now under consideration.

THE EFFECTS OF LACTATION ON MENSTRUATION AND IMPREGNATION.

By Leonard Remfry, M.D., B.C.(Cantab.), M.R.C.P.,
ASSISTANT OBSTETRIC PHYSICIAN TO ST. GEORGE'S HOSPITAL; OBSTETRIC PHYSICIAN TO THE GREAT NORTHERN HOSPITAL.

(Received October 25th, 1895.)

One of the most popular beliefs among married women is that suckling prevents conception; and among the poorer classes it is no uncommon thing to see a child eighteen months, or even two years old, still at the breast,—the mother very weak, the child puny and unhealthy.

With the view of inquiring into the subject generally, the author has taken notes of several hundred cases, and as a result many interesting facts have been elicited. Now, as is well known, there is an intimate connection between the function of the breast and that of the uterus. When the breasts are active and secreting, menstruation is commonly absent. If a mother does not suckle her baby, the catamenia appear some time during the puerperal period, after the mammary glands have become quiescent. Again, when a child is weaned, the rule is that the woman will soon menstruate as before pregnancy.

Not only has the breast function this connection with menstruation, but it has also an acknowledged relation with the process of involution.

The uterus in a healthy suckling woman will gradually return to its normal size in about six weeks. The condition of sub-involution is frequently found in patients who have not suckled their children. Again, after miscarriage sub-involution is more often seen than after full-time

labour; for several reasons, such as getting up too early, fragments of placenta or membranes being retained, and lastly because there has been no lactation.

Therefore many will give ergot during the puerperal period to aid involution in cases in which the child is not nursed. Suckling often causes pain in the region of the uterus, due to uterine contraction. Again, as Galabin says, "continuing to suckle an infant after pregnancy has recurred may lead to abortion, suckling having a well-known tendency to set up uterine contraction." The application of the child to the breast in cases of post-partum hæmorrhage is a practice commonly followed. Lastly, irritation of the breasts is known to have been applied with the view of criminally producing abortion.

Taking all these facts together, the connection of lactation with uterine function and uterine contraction is made a strong one.

What the condition of the uterine mucous membrane is in during suckling the author can only surmise. When amenorrhœa is present it must certainly be an anæmic one, presumably associated with little or no growth, though this may occur to a slight extent, and undergo degeneration, the products passing away unnoticed. *Per contra,* when menstruation is complete and regular during lactation, probably the mucous membrane and the changes which take place in it are identical with those associated with the usual catamenia. The difficulty of examining post mortem the uterus of a healthy suckling woman is obvious. Whether the local appearances in suckling when menstruation is not present are similar to those in chlorosis does not concern the objects of this paper.

In order to arrive at any satisfactory results it has been necessary to question a large number of women on the following points:—(1) number of pregnancies; (2) number of children nursed, and how long each time; (3) whether after delivery amenorrhœa had been present during suckling, and if not, when and how soon the catamenia had come on; (4) whether pregnancy had

commenced during suckling; (5) whether, if menstruation had appeared, it had been regular or otherwise. In this investigation the lactation-periods and the events associated with them have been studied. The histories of about 900 lactations have been inquired into, and various interesting facts made prominent. Firstly, 503 were attended with amenorrhœa, and 388 with menstruation more or less marked (this latter will be expressed more clearly later). Therefore 57 per cent. of the lactations were associated with complete amenorrhœa, and 43 per cent. with menstruation at some time—a difference of only 14 in 100. Out of the 388 cases, that is 43 per cent. of the total number, 226 became pregnant during suckling, which comes to about three-fifths. In 245 cases out of the 388 menstruation began within three months post partum, and continued regular till in the majority of cases conception occurred, or in others till the weaning of the child. In the remaining 143 a definite classification cannot be well given, owing to times of amenorrhœa being followed by times of menstruation or "shows."

The 245 should be called cases of "absolute regularity," and the 143 cases of "relative regularity" and "relative amenorrhœa" in the same woman. This combination is illustrated by the following case taken from the list. A suckling woman had amenorrhœa for six months, then three monthly periods at monthly intervals. After the third one she became pregnant. The above is a lactation period of relative amenorrhœa and relative regularity. In 57 per cent. of the cases there was absolute amenorrhœa, and in 26 per cent. absolute regularity,—that is, nearly twice as many women have amenorrhœa as have regular menstruation during suckling. The odd 17 per cent., however, is most important in adding evidence to support the principal fact demonstrated in the paper, namely, that menstruation during lactation very strongly favours impregnation. Take the figures:—In 503 lactation periods associated with absolute amenorrhœa, only 29 impregnations took place. In those associated with more

or less menstruation, namely 388, there occurred 226 impregnations. In other words, out of 100 women who have absolute amenorrhœa, only 6 become pregnant, while out of 100 who are either regular throughout suckling, or have catamenia at some part of the lactation period, 60 are impregnated, that is ten times as many. Two typical cases are given to illustrate the above.

1. Aged 85. Pregnancies ten. Suckled, as a rule, nine months. Always saw her periods at the third month post partum, being quite regular till impregnation, which took place ten times during suckling, *i. e.* on every occasion.

2. A woman had had four pregnancies. In three of them she became regular at an early date, and in each case soon became pregnant. The same woman during one lactation did not menstruate at all. She did *not* become pregnant. This was not after her last or fourth child, for then it might have been inferred that she had ceased child-bearing.

The explanation of these facts would seem to be that in the menstruation cases the mucous membrane had grown to such an extent as to be a suitable nidus for the impregnated ovum, and *vice versâ*. There are cases of pregnancy occurring during lactation in which there has only been a show on one day: *e. g.* Mrs. M— suckled a child for nine months; at six months she had a slight show for two days; and three months after, that is at nine months, she had an abortion of three months. Thus it might be conjectured, on taking one step farther, that of the 6 per cent. who became pregnant during amenorrhœa the mucous membrane had grown to an extent sufficient to lodge the ovum; in other words, if impregnation had not occurred then, menstruation would have appeared. Such a theory as this cannot be supported by any direct evidence, but there may be some truth in it.

As bearing on the subject of the association of amenorrhœa and non-impregnation may be mentioned the fact that a woman often becomes pregnant on weaning her baby without having any catamenia at all.

To recapitulate:

1. Of suckling women, 57 per cent. only have absolute amenorrhœa.

2. Forty-three per cent. menstruate more or less, but 26 per cent. have absolute regularity.

3. Impregnation does not take place so readily during lactation as at other times, but this is not true to such an extent as has been imagined.

4. If absolute amenorrhœa is present during lactation, the chances of impregnation occurring are only 6 out of 100.

5. If menstruation occurs during lactation the chances of impregnation are 60 in 100.

6. The more regular a woman is during lactation, the more likely is she to become pregnant.

7. During a menstruating lactation the changes in the uterus are presumably similar to those connected with the ordinary monthly periods, and the mucous membrane forms a nidus for the ovum

8. In the woman who does not suckle at all the menses appear, as a rule, some time in the first six weeks after delivery.

Dr. EDEN said there was no evidence of a functional relationship between the mamma and the uterus, beyond the fact that stimulation of the cutaneous nerves of the nipple induced reflex contractions of the uterine muscle. According to Dr. Remfry's figures, mammary activity had no definite effect upon the menstruation function, for in about half the cases there was amenorrhœa, and in the other half menstruation continued. Dr. Remfry's paper had an important bearing upon certain theoretical considerations. It was now proved that ovulation and menstruation were independent processes, and there was a growing opinion among physiologists that menstruation ought not to be regarded as bearing any important relation to the occurrence of conception. Dr. Remfry's facts proved that physiological amenorrhœa—*i. e.* amenorrhœa without impairment of the general bodily health—was an extremely unfavourable condition for the occurrence of conception. This could only be explained by the assumption that the preparation of the uterine mucosa by the menstrual process was a very important item in the factors of conception. If we accepted this view, however, we were met with the difficulty of explaining those rare cases in

Dr. Remfry's list in which conception occurred during amenorrhœa. We must remember that we do not know anything about the condition of the uterine mucosa in amenorrhœa. All we meant by the term was that there is no monthly escape of blood from the uterus. That there might still be constitutional changes was proved by the occurrence of menstrual molimina in a certain proportion of cases of amenorrhœa. It was also possible that menstrual changes occurred to a certain extent in the uterine mucosa, not sufficient to cause an escape of blood by the natural passages, but enough to prepare the membrane for the due reception of the fertilised ovum.

Dr. McCann stated that he had been for six months collecting statistics on the subject of Dr. Remfry's paper. Without giving accurate details he was able to state—1. That the majority of women who become pregnant during lactation have menstruated regularly after their confinement. 2. That the greater number of pregnancies during lactation commence after the eighth month. 3. In most patients the supply of milk diminishes on the occurrence of pregnancy, and the monthly loss of blood ceases. 4. Prolonged lactation, especially where the milk supply is copious, favours involution and subsequent sterility. 5. Menstruation during lactation does not always recur in the same individual. 6. The amount and duration of the menstruation during lactation correspond to that of the ordinary menstruation in the same individual. Dr. McCann did not think that non-suckling was a cause of sub-involution of the uterus.

Dr. Boxall considered that the Society was much indebted to the author of the paper for putting a popular belief through the scientific mill, and also to Dr. McCann for his observations on the same subject. He would, however, like to see an omission rectified. For though quite prepared to accept the conclusion that the more regular a woman is during lactation the more likely is she to become pregnant, it seemed to him that Dr. Remfry had omitted the data upon which this conclusion was based. In the paper 60 per cent. who became pregnant during lactation were drawn from the two combined classes of those who menstruated regularly and irregularly. He would like to see the percentage of impregnations in each class given separately. With regard to the causes of sub-involution following miscarriage, he thought that miscarriage and subsequent sub-involution were often brought about by the operation of the same cause or combination of causes.

Dr. Lewers said the possible connection between super-involution with amenorrhœa and prolonged lactation had been mentioned. More frequently, however, unduly prolonged lactation led to menorrhagia, as was taught many years ago by the late Dr. Matthews Duncan. He had seen a large number of such cases, and no doubt many present had had a similar experience.

ANNUAL MEETING.

FEBRUARY 5TH, 1896.

F. H. CHAMPNEYS, M.A., M.D., President, in the Chair.

Present—70 Fellows and 6 visitors.

Books were presented by the Middlesex Hospital Staff, Mr. C. B. Lockwood, Dr. Paul F. Mundé, Messrs. Wright and Co., and Dr. Cleveland.

Walter Sidney Sheppard, B.A., M.B., B.Ch.Cantab.; Charles Atkin Swan, M.B., B.Ch.Oxon.; and Wilfred Newell Sodon, M.B.Lond., were admitted.

John Bradbury Winter, L.R.C.P.Lond. (Brighton), and R. T. Nariman, M.D.Brux. (Bombay), were declared admitted.

The following three gentlemen were proposed for election :—T. Hellier Chittenden, L.R.C.P.Lond.; George Herbert Hopkins, F.R.C.S.Eng. (Swansea); Ernest W. Groves, L.R.C.P.Lond.

SOLID TUMOURS.

Shown by LEITH NAPIER, M.D.

THE specimen consisted of a solid ovarian tumour, a small subperitoneal uterine fibro-myoma, and the uterine appendages from the right side.

The patient consulted Dr. Leith Napier on July 24th,

1895. She was thirty-four years of age, had been married four years, and had never been pregnant nor had previous illness. Her periods were first seen at thirteen years of age, when she was regular, the interval being twenty-eight days, and the duration four days.

After marriage the periods recurred every twenty-four days, and continued four to five days. She stated that the quantity lost was now less than formerly. She complained of neuralgia in the head and neck, which for the past six months had always been worse on the day preceding menstruation. Bowels regular. Bladder irritable, micturition frequent during the day, and at times also during the night. Physical examination showed the uterus to be normal in size and position. To the left of the uterus was a very hard, irregular, nodulated lump the size of a small Tangerine orange, and attached to, but evidently distinctly separable from, the uterus. The lump was not tender.

On August 26th she was again seen. The period on 3rd August continued for two days, then ceased and returned for two days. Bladder less irritable. The physical condition was the same, except that the tumour was larger and less separable from the uterus. A diagnosis of solid ovarian growth, or possibly subperitoneal fibroid with short pedicle was made. An exploration with a view to its removal was now advised.

The patient consulted Dr. Amand Routh, and later Dr. Herman.

On September 26th patient again attended. She stated that the last period was on 22nd, duration four days, less pain than formerly, quantity slightly increased ; no leucorrhœa. No bladder irritation. Tumour was distinctly larger. She again consulted Dr. Amand Routh, who agreed that operation was advisable on account of rapid increase. She also saw Dr. Bantock, who confirmed the advice given.

Operation on October 14th. She made a good recovery. Normal temperature throughout, and left the home strong and well on November 2nd.

The special interest of the case was pathological. Dr. Kanthack, who had examined the specimens, expressed the opinion that the tumours were simple fibromata. This was agreed to as regarded the uterine growth, but Dr. Leith Napier was inclined to be sceptical about true fibroma of the ovary being nearly so common as fibro-sarcomatous growths.

Specimens regarded as simple fibroma of the ovary had been shown by Dr. Cullingworth, Dr. Handfield-Jones, Mr. Alban Doran, and others at the Society.

In the speaker's experience one could not base a prognosis wholly on a few microscopic sections; he had previously had two cases pronounced by highly competent microscopists to be true fibroma, yet secondary sarcomatous recurrence had happened. The immediate result of the operation was very satisfactory; he trusted that it was a simple fibroma of the ovary.

Dr. Amand Routh asked if Dr. Napier had removed the fibroma *per vaginam*, as he had originally intended.

In reply to Dr. Amand Routh, Dr. Leith Napier said that he performed abdominal section. Originally he proposed to operate by vaginal section (anterior colpotomy) as the smaller size of the growth would then have made this easy. He altered his intention as the tumour had grown considerably, and had become less separable from the uterus. He was glad he did so, as from the nature of its uterine attachment it would have been difficult to operate safely without opening the abdomen anteriorly. Further, the uterine fibro-myoma, which, so far as he knew, no one of the four gynæcologists who had examined the patient had recognised, had so close an attachment to the posterior uterine wall and was so vascular that it was necessary for its safe removal to temporarily bring the uterus partly outside the abdomen.

Dr. Leith Napier alluded to a case of fibro-sarcomatous growth occurring on the inner surface of the wall of an ovarian cystoma which Dr. Eden had exhibited for the speaker at the Society in November, 1895.* In addition to Dr. Eden, who had microscopically examined the growth, several skilled microscopists examined the sections, and Dr. Griffith was, he believed, one of those who had kindly done so. The opinion expressed was that this was

* *Vide* 'Obstet. Trans.,' vol. xxxv, p. 409.

a very harmless type of sarcoma, which was most unlikely to recur. Yet recurrence did speedily take place, and the patient died on February 1st, 1894 (four months after operation), with two enormous growths in the pelvis. So much for some cases of prognosis founded solely on the microscope.

Dr. Leith Napier said that the specimen was at the disposal of Dr. Griffith or any other Fellow who might wish to examine it.

A sub-committee, consisting of Drs. Cullingworth, Griffith, and Leith Napier, with Mr. Alban Doran, was appointed to examine and report on this specimen.

Report of Committee on Dr. Leith Napier's Specimen of Solid Ovarian Tumour.

We, the undersigned, have met this day, and, after examining the specimen named above, have drawn up and signed the following report.

The specimen, having been kept in spirit for nearly two months, consists of a solid lobulated tumour, $6\frac{1}{4}$ inches in circumference, $2\frac{3}{4}$ inches in length, and $1\frac{1}{2}$ inches in width. The weight is $3\frac{1}{4}$ oz.

Its outer surface is smooth excepting over an area of five eighths of an inch in diameter, which represents its attachment. On section the tumour is very hard in consistence, and presents a fibrinosed appearance, whitish bands dividing it irregularly.

A section through the whole thickness of the tumour presents, microscopically, the characters of a spindle-celled sarcoma of the ovary.

J. Bland Sutton.
Chas. J. Cullingworth.
Leith Napier.

Dr. Griffith reports separately regarding the microscopic characters as follows:

I am of opinion that the tumour has the usual characters of the spindle-celled fibroma of the ovary, and am unable to say with certainty if it is innocent or malignant, but I believe it is innocent.

WALTER S. A. GRIFFITH.

SLOUGH FORMING A COMPLETE CAST OF THE VAGINA, FROM A CASE OF ENTERIC FEVER.

Shown by W. S. PLAYFAIR, M.D.

DR. PLAYFAIR exhibited a specimen of a slough forming a complete cast of the vagina. This was a tube of sloughing tissue of considerable thickness, with one opening at the top corresponding to the insertion of the cervix, the other to the ostium vaginæ. It had been passed spontaneously in the course of the third week of a severe case of typhoid fever, and in consequence of the unusual nature of the occurrence, and the alarm it caused, Dr. Playfair had been asked to see the patient. He had never himself met with a similar case, nor had he been able to find any record of one in the works on medicine he had consulted, including Murchison's classical book on fevers. He had, however, come across a notice of the same thing having occurred not very rarely in cases of malignant smallpox in the pre-vaccination days. He had had an opportunity of examining the patient after convalescence, and, beyond a narrowing of the upper part of the vagina, could find little trace of mischief.

Milan was due to a co-existing uterine gestation which had aborted, and from which came the blood-clot which caused septic infection.

UNRUPTURED TUBAL GESTATION.

Shown by WILLIAM DUNCAN, M.D.

THE patient from whom the specimen was removed was admitted under Dr. Duncan's care to the Chelsea Hospital for Women with the typical symptoms and physical signs of tubal pregnancy.

Mrs. E. F—, aged 30, has had two children (twins, born in June, 1892); no miscarriages. Since the last confinement the periods were regular up to October 10th, 1895. She missed her period in November, and on December 1st was seized with acute abdominal pain and sickness. A loss came on on December 5th; this lasted five days, was not accompanied by clots or membrane, but was followed by a brownish, somewhat offensive discharge, which continued until January 13th, 1896, when bright blood again began to come away.

On admission (January 13th) nothing abnormal could be detected in the lower abdomen, but *per vaginam* the uterus felt somewhat bulky, and was pushed over to the left by a rounded elastic swelling in the right posterior quarter of the pelvis, which moved with the uterus. Large pulsating vessels could be felt passing over the mass.

Extra-uterine pregnancy was diagnosed, and abdominal section performed next day. The right tube was the size of a German sausage, and appeared in one or two places on the point of rupture: there was a corpus luteum of pregnancy in the right ovary. On section the tube contained a gestation sac surrounded by placenta and blood.

The left ovary was cystic, and the tube dilated into a hydrosalpinx, so it was necessary to remove the left appendage also.

The patient made an uninterrupted recovery.

LARGE DOUBLE TUBO-OVARIAN CYSTS.

Shown by WILLIAM DUNCAN, M.D.

MRS. D—, aged 25, married four years, has never been pregnant. Catamenia commenced at sixteen, and have always been quite regular. In 1893 she was told she had an ovarian tumour, but as she was not inconvenienced by it she continued to go about as usual until November 7th, 1895, when severe abdominal pain came on, and the tumour increased in size.

On examination, January 7th, 1896, the abdomen is prominent below the umbilicus, owing to a cystic swelling which reaches nearly up to the umbilicus, extends two fingers' breadth to the right of the middle line and into the left flank, where an irregular boss can be felt.

Per vaginam the uterus is pushed forwards and upwards by a cystic swelling in the pouch of Douglas. The uterus is normal in size and mobile.

Abdominal section was performed; the omentum was adherent to the abdominal wall. Two cystic tumours were found, the larger one being on the right side and filling up the pelvic cavity. After numerous adhesions were tied and divided the tumours were removed, and both proved to be tubo-ovarian.

The patient made an uninterrupted recovery.

INTRA-LIGAMENTOUS GESTATION RETAINED FOR TWENTY-ONE YEARS.

Shown by A. L. Galabin, M.D.

Dr. Galabin showed a specimen of extra-uterine gestation of the intra-ligamentous variety, which had reached full term and was removed by operation after being retained for over twenty-one years.

The patient was in Guy's Hospital in 1872 under Dr. Braxton Hicks and Dr. Phillips, and was aged then twenty-five.

There was then a history of pregnancy which had reached full term two or three months before, and had not ended in delivery. Extra-uterine fœtation was diagnosed, and it was decided not to interfere. She was afterwards in the Soho Hospital, where the same diagnosis was made and the same decision arrived at. The tumour remained for twenty years, slightly shrinking, and she had no acute symptoms, though she suffered more or less inconvenience. There was no subsequent pregnancy.

After twenty years the abdomen began to enlarge greatly, and there were physical signs of an ovarian cyst. Abdominal section was performed in Guy's Hospital in 1894, and an ovarian tumour of the right side was removed without great difficulty. The uterus was pushed to the right, and a hard tumour occupied the left broad ligament. An attempt was made to incise it, but it was so calcified that it resisted the knife. It was found possible to remove it entire by dissecting it out of the pelvic cellular tissue, the whole of the left broad ligament being removed. The tumour, being sawn open, revealed a full-term fœtus doubled up and tightly packed in the sac. The head lay downwards and the spine forwards. The sac was completely calcified, but the fœtus was in wonderful preservation. Even the brain remained intact

and soft, but of a dark grey colour, and the shape of the ventricles of the brain was unaltered.

The patient made a good recovery.

Dr. Heywood Smith asked if Dr. Galabin had seen the ureter, and if so, whether it was displaced by the growth of the tumour.

Dr. Galabin said, in answer to Dr. Heywood Smith, that he did not see or feel the ureter, although throughout the operation of detaching the sac he was in constant dread of tearing it. Apparently, however, it escaped.

TUBAL GESTATION RUPTURED AT THE SIXTH WEEK.

Shown by A. L. Galabin, M.D.

Dr. Galabin showed a specimen of tubal fœtation ruptured at six weeks; with the embryo, $\frac{9}{16}$ inch in length. The case was unusual from the fact that it did not occur after a period of sterility; but only a year after marriage, during which time there had already been a pregnancy.

The patient was aged twenty-four, had been married one year. Five months after marriage she had a miscarriage at two months' pregnancy.

A normal period ended on October 29th. The next period did not come on at the time expected. On December 3rd she had a slight show for one day. She was treated by Dr. F. Wallace for a threatened miscarriage, and kept in bed about a week. On December 13th she went out for a walk. During the following night severe pain in the left side came on, and Dr. Wallace was called up to see her. She was again kept in bed. On the morning of December 15th, when she had got out of bed for the action of the bowels, she had again severe pain in the left side, and fainted. Dr. Wallace was not then sent for, but saw her in the ordinary course

that afternoon. He found a good deal of collapse present, and suspected ruptured tubal fœtation. Dr. Galabin saw her in consultation the same evening. The pain was then somewhat relieved by sedatives, pulse about 120, the patient looking pale. There was no resistance nor induration in the pelvis, and nothing abnormal could at first be felt, the recti muscles being rigid. An anæsthetic was then given, and a small lump was felt bimanually high up on the left side of the uterus. It was decided to perform abdominal section the next day.

The operation was performed on December 16th. The peritoneal cavity contained a very large quantity of dark fluid blood, but no clots. A mass of clot containing placental tissue about the size of a walnut was sticking in the aperture in the left tube, but came away before it could be drawn up. There were no adhesions, and the left tube and ovary were removed with ease. The uterus did not seem appreciably enlarged. The right appendages appeared normal. The peritoneal cavity was washed out, and the embryo came out in the stream. No drainage was used, and the patient recovered very rapidly.

It was remarkable that no clotting had occurred although the hæmorrhage had begun probably more than three days, and certainly at least thirty hours before operation. The case illustrated the facility of the operation and the rapidity of recovery under these circumstances. It was also remarkable that there was no sanguineous discharge *per vaginam* at or after the time of rupture, and only a slight show for one day previously.

ABDOMINAL HYSTERECTOMY WITH INTRA-PERITONEAL TREATMENT OF THE STUMP; WITH NOTES OF EIGHT CASES.

By Harrison Cripps, F.R.C.S.,

ASSISTANT SURGEON TO ST. BARTHOLOMEW'S HOSPITAL, AND OPERATOR FOR THE ABDOMINAL SECTIONS IN THE WOMEN'S WARD.

(Received November 8th, 1895.)

(*Abstract.*)

The author considers that the surgical removal of fibroid tumours of the uterus is called for in the following class of cases:

1. Excessive hæmorrhage, uncontrolled by the ordinary methods of treatment, and in which oöphorectomy is impossible.
2. Serious pressure-effects on the bladder or rectum.
3. When the pain or the size of the tumour render the patient unable to earn her living.

The writer contrasts the extra-peritoneal with the intra-peritoneal method of treatment of the pedicle. The latter has given him the better results.

Whilst in the extra peritoneal method the danger from sepsis is slighter, that from obstruction of the intestine and ureters seems greater than in the intra-peritoneal method. This greater risk of peritonitis in the intra-peritoneal method is probably from infection through the vagina. To minimise this risk the author lays stress on two points:

1. He employs thorough and repeated douching of the vagina with perchloride of mercury before operating.
2. He is careful to accurately close the peritoneum over the surface of the stump.

Details of the method of operation employed are then given, stress being laid on two points:

(*a*) The importance of having sufficient room, supplied if necessary by making a long abdominal incision.

(*b*) The method of securing the vessels in the broad ligaments.

This depends on whether the layers of this ligament have been separated by lateral burrowing of the tumour or not.

Notes are then given of eight cases operated on by the intra-peritoneal method (up to September, 1895). Seven cases ended in recovery; there was one death from sepsis, due to infection from the vagina.

Mr. President and Gentlemen,—I do not propose this evening to enter into details justifying hysterectomy, for in certain circumstances not only is it a justifiable operation, but one of extreme value.

A large number of women have fibroid tumours of greater or less extent, which never give rise to trouble and in no way interfere with the health; others, again, may have tumours which for a while give trouble, but which, ceasing to grow, cause no further inconvenience, and which may subsequently atrophy, or even completely disappear. On the other hand, a fibroid tumour may be the gravest of diseases, rendering existence miserable, and ultimately proving fatal from the effects of pressure, inflammation, or cystic degeneration. If fibroid tumours could be removed like similar growths on the surface of the body without appreciable risk, there could be no question as to the propriety of their removal. Unfortunately this is not so, for, on the contrary, the operation puts life into immediate peril, and must be considered as one of the gravest in surgery.

With improved methods and care in detail there is every probability that the mortality from hysterectomy will decrease. Nevertheless, when the anatomical position of the uterus and its connections with the bladder, rectum, ureter, and large vessels are considered, it can be

realised how in the majority of cases the operation must be more severe, and deal with more vital structures than an average ovariotomy. Considering the risk to the patient's life, it is undoubtedly only in certain cases that the operation should be undertaken; and what has to be considered is the same as in all other surgical procedures, whether the discomfort, pain, and risk to life in leaving the tumour alone is not greater than that involved in surgical interference. As the detail and safety of the operation are improved, so will a larger number than at present of these cases come within the range of legitimate surgical interference.

At present we consider at St. Bartholomew's Hospital the following class of cases justifies an operation:

1. Excessive hæmorrhage, uncontrolled by rest and appropriate medical treatment, and in which oöphorectomy may be impracticable.

2. Serious pressure effects upon the bladder or rectum.

3. When the pain or the size of the tumour renders the woman incapable of earning her livelihood.

Before undertaking any operation the surgical aspect of the case must be carefully considered. It is not possible, even after the most thorough examination, to form an exact estimate of the difficulties that may be encountered in the operation. Nevertheless, from the position of the tumour, the degree of mobility, and other signs, a fairly accurate estimate of the severity of the operation may be formed, and the fact must not be lost sight of that an operation might be quite proper where no unusual surgical difficulties were anticipated, yet would be unjustifiable if such were obviously present.

An operation having been decided on, there are two methods of performing it by abdominal section, the extra-peritoneal and the intra-peritoneal plan of treating the stump. In the former the pedicle is brought outside the abdomen, and fixed in the lower angle of the wound. In the latter it is cut through as near the vagina as possible, and allowed to drop back into the pelvis. I have

had some experience of both these methods, and although it is too early to speak positively as to the merits of the one over the other, there is little doubt that the intra-peritoneal treatment will be that generally adopted in the future. In my own practice up to the present time it has afforded the better results. I do not, however, anticipate that it will diminish the risk of sepsis; indeed, on the contrary, the chances of this deadly complication seem to be greater than when the pedicle is brought outside. If the pedicle when brought outside be trimmed small, and kept scrupulously clean and dry by the application of spirit and iodoform and boracic powder, there is practically no risk of sepsis. The special danger with the pedicle drawn out seems to be from obstruction produced either by adhesion to the pedicle, or by the kinking of the colon caused by the forcible dragging up of the pedicle. There would also appear to be less risk to the ureters, for several cases are recorded in which they have been actually included in the serre-nœud, or drawn up and kinked by the dragging on the pedicle. These dangers are avoided by intra-peritoneal treatment, which leaves a far better and sounder scar.

The point, however, about which we require further information and experience, is the question of septic peritonitis. I take it that, so far as the operation itself is concerned, there is with a clean theatre, and clean hands and instruments, no more risk in the one case than in the other; but what has to be guarded against in the intra-peritoneal plan is the chance of secondary septic inflammation taking place through the vagina. I am satisfied that the infection in the fatal case which I record in this series occurred by the vaginal route. This experience impresses two points: the one, the thorough and repeated washing of the vagina prior to the operation by perchloride solution; the other is the exercise of greater care in accurately closing the peritoneum over the surface of the stump. Dr. Baer, to whom part of the credit is due of introducing this method, errs, I think, in

laying little or no stress upon this point; indeed, he says in many cases no stitching across of the peritoneum is necessary, the parts naturally falling together. It is perfectly true that the tension put on the broad ligaments by the ligatures on either side draws the peritoneal surfaces together over the stump. I have noticed, however, that though the stump is practically dry as regards any actually bleeding vessel, there is a slight general oozing. Blood thus collecting even in small quantity between the surface of the stump and the peritoneal flaps will cause the latter, if unsecured, to gape, and allow part of the blood-clot to project into the peritoneal cavity. It can be thus understood how easily peritonitis could be excited, should this blood-clot become infected by the vagina, with which it directly communicates. In my fatal case a small clot had thus insinuated itself between the peritoneal edges, which were only loosely united with a couple of sutures, and apparently was the starting-point of the trouble. In future, even at the risk of prolonging the operation, I shall make a point of accurately and completely uniting the peritoneal surfaces with a row of the finest interrupted sutures. There are one or two other points in the operation to which I would wish to call particular attention. In the first place I do not hesitate to secure plenty of room by making a long abdominal incision. In this way not only are the intestines less liable to bruising by manipulation, but a good view will be obtained for sewing over the pedicle, which, it must be remembered, lies almost at the bottom of the pelvis. Another important step in the operation is the securing the vessels as they enter the tumour through the broad ligament. The ease or difficulty of this part of the operation will depend on the extent to which the layers of the ligament have been separated by the tumour growing between them.

A careful examination will show how the bulk of the blood-vessels pass to and from the tumour in two directions only. Of course this is what would be expected from the normal anatomy of the parts where the blood-vessels

enter the broad ligament at right angles to the pelvis on either side, but the normal position is often strangely distorted by the growing tumour. The uterus and broad ligaments are considerably twisted on their axes. The large vessels can be often seen encircling the tumour for several inches before disappearing into it. Thus there is what may be described as a vascular band spread out like a ribbon, two, three, or more inches wide, passing round the tumour. With a not too sharply pointed, strong, large needle in a handle the operation is commenced by passing a thread of stout silk below the vascular ribbon, entering it at a point as low down on the tumour towards the cervix as possible, keeping it close to the tumour substance, and getting it to emerge well beyond the vascular area behind. The needle is now unthreaded and withdrawn, and introduced from before backwards through the upper edge of the broad ligament close to the side of the pelvis. The free end of the silk lying behind the vascular area is then threaded through the eye of the needle and withdrawn. In this way the chief vessels will be encircled by a ligature. It is best left loose and not tightened at this stage. A similar ligature being passed on the opposite side, they can now be each firmly tied if the broad ligament has not been widely separated. The object of bringing back the thread through the upper and outer margin of the broad ligament is merely to prevent it slipping when tied. A long clamp forceps is now put on the broad ligament close to the tumour to prevent regurgitation. The broad ligament is then divided by cutting close to the forceps. This sets the tumour and uterus to a certain extent free, and allows of its being drawn up by the assistant. A transverse cut is made by lightly drawing the knife across the peritoneum lying in front of the tumour or uterus, and about two inches above the reflection of the bladder. The ends of this transverse cut extend as far as where the broad ligament has already been opened laterally. With the handle of the knife, the bladder,

together with the peritoneum, is peeled off the lower surface of the tumour as far as possible. The lower the operator gets, the more closely he will find it adherent to the cervix.

The tumour is now drawn upwards and forwards, and a similar transverse cut is made behind, a little higher than the level of that made in front, the peritoneum being again peeled down as before. At this period the operator will be in the neighbourhood of the uterine arteries. By using a short stout needle, set at right angles, a thread may be passed as low down towards the cervix as possible, keeping close to the cervix so as to avoid the ureters. It is advised by some operators that this final transfixion should be made so as to include the peritoneum before and behind, forming the lower part of the broad ligament, but I have found this often impracticable, and pass the ligature within or between the layers of the broad ligament, which are not easily distinguishable at this period. These ligatures being passed and tied on either side, the uterus is cut across at the level down to which the peritoneum has been reflected. The stump is then seized by vulsella and further trimmed away. In one of my cases every scrap of the cervix was removed at the first cut, the knife having passed across the upper part of the vagina. In this case there was some rather troublesome hæmorrhage from the vaginal walls. In the other cases, after trimming the stump, it was found that a small nodule of the cervix not more than an inch in length was left. The peritoneum, as has already been mentioned, should be sewn most carefully across the surface of the stump, taking care that the peritoneal edges are in contact. In this way the continuity of the peritoneal floor of Douglas's pouch is completely restored, and the open cervical canal shut off from the peritoneum. I will again refer for a moment to the treatment of the vessels in the broad ligament. In two of my cases, after transfixing the ligament below the vascular area, the parts were so tightly on the stretch from the tumour

expanding the ligament, that it would have been absolutely impossible, owing to the tension, to have tied them without cutting through or tearing some of the large thin-walled veins. I therefore clamped and successively divided the broad ligament on the tumour side of the ligature in five or six portions. After this in one case the tension was so relieved that the primary ligature could be firmly and securely tied. In another case I withdrew the ligature altogether, transfixing and tying each of the portions included in the forceps separately, and am disposed to think that, when there is much separation of the layers, it is better to deal thus with the broad ligament in segments rather than to endeavour to include the whole upper portion in a single ligature. This ligaturing of the broad ligament previous to the removal of the tumour I was only able to do in four of the cases. In the others, owing to the way that the broad ligaments were separated by the growing tumour, it was quite impracticable; and as to the directions given by Baer for putting a large pair of clamp forceps on the tumour side to prevent regurgitation, it was as impracticable in some of the cases as fixing them over the side of a full moon, the broad ligament having to be clamped and divided portion by portion.

I will now give the notes as briefly as possible of all. The cases are eight in number on which I have operated by the intra-peritoneal method up to the end of September last. Of these cases, seven recovered and one died, the death being due to peritonitis starting, as I believe, from vaginal infection. No drainage was employed in any of the cases, but further and more extended experience, which I shall hope to publish on a future occasion, has altered my views in this respect, and in the future I intend to use a small-calibre glass drainage-tube extending from the lower angle of the wound to the bottom of Douglas's pouch, to be retained until I am satisfied that there is no fluid at the bottom of the pelvis likely to decompose by vaginal infection.

The cases I have recorded are too few to draw any general deduction as to the relative mortality of this operation when compared with that of fixing the stump in the wound. Nevertheless I venture to bring the subject before the Society this evening, hoping that other surgeons may be induced to give their experience of the method, and that suggestions may be made as to further improvement in the details of the operation.

I should mention that the hospital cases were under the care of Dr. Champneys, with the exception of Cases 3 and 4, which were admitted under Dr. Griffith, and it is with their permission that I have been able to bring the cases forward this evening. I am also much indebted to my colleague, Mr. Bruce Clark, for his assistance during some of the operations.

Case 1.—M. G—, aged 35, admitted in June, 1894.

Swelling first noticed two years ago; increased slowly at first, more rapidly lately. The abdomen was distended by a tumour rising midway between the navel and ensiform cartilage. The tumour was elastic, and gave much the sensation of being a thick-walled cyst. The sound, however, passed 5½ inches. On opening the abdomen the tumour proved to be a soft lobulated fibroid between the layers of the left broad ligament. There were some omental adhesions. The left ovary was enlarged and cystic, and being much in the way was first removed. One lobe of the tumour was deeply fixed in the pelvis, and it was not until the broad ligament had been divided and peeled back that it was shelled out. The peritoneum was then peeled back. The tumour, which weighed 13 lbs., together with the upper part of the uterus, was then cut off. In the pit left after enucleating the lobe from the left broad ligament there was considerable hæmorrhage. This was at first controlled by a large sponge. On further examination the iliac vessels and ureter exposed for some length were seen lying along the outer side of the pit. After considerable difficulty a good-

sized vessel, from which bleeding was occurring, was secured with artery forceps and tied. No irrigation or drainage. The wound was closed with silk-gut sutures.

The patient did well for a fortnight, when the temperature became raised. On examining *per vaginam* the whole left half of the pelvis was found occupied by a large indurated fixed mass. In the fourth week a few drops of pus exuded from the lower angle of the wound. A probe passed through this sinus 3 or 4 inches towards the centre of the mass previously described. From this time the temperature became normal, and the induration gradually disappeared, and the patient was discharged from the hospital five weeks after the operation, a small sinus still existing. A month later, after passing a fine aspirating trocar down the sinus and syringing vigorously, a small silk ligature came away.

Case 2.—M. W—, aged 41, admitted in June, 1895. For the last five years suffered from severe floodings. For the last year has had much abdominal pain and several attacks of retention of urine. The abdomen is occupied by a hard tumour reaching three inches above the navel. *Per vaginam* the whole pelvic cavity is occupied by a spherical mass continuous with the abdominal tumour. There is a projection of the abdominal tumour into the anterior wall of the cervix, the posterior lip being tightly stretched over it. A sound passes its full length behind the tumour. The abdomen was opened by a 6½-inch incision. With a little manipulation the tumour was extruded from the abdominal cavity. The ovaries and tubes were both situated high up on the tumour. The broad ligament was then secured on either side by ligatures, and clamped on the distal side and divided. The bladder was lying high up on the surface of the tumour. Two anterior and posterior peritoneal flaps were cut, and the bladder peeled down. Both the uterine arteries could be plainly seen and picked up with pressure forceps, divided, and tied; the tumour was then cut off.

It was now seen that the whole of the uterus and cervix had been removed, and the upper part of the vagina, looking like a circular band, was exposed at the bottom of the wound. There was some free oozing from the cut surface of the vagina. Four bleeding points were secured with fine sutures. The wound being quite dry, the anterior and posterior peritoneal flaps were sewn across and the abdomen closed. The tumour, weighing 10 lbs., was a soft fibroid growing from the anterior part of the cervix.

The patient was discharged well at the end of the month.

Case 3.—J. M—, aged 40, admitted July, 1895. A year ago commenced to lose blood very freely, and for the last four months has never gone more than a week without loss. The patient has become extremely anæmic. On examination the abdomen was found occupied by a partly elastic tumour extending to the navel. Tumour was fairly moveable. The abdomen was opened by a 7-inch incision, and an exactly similar operation to that in the last case performed, with the exception that the broad ligaments were clamped and divided in portions, and about one inch of the cervix was left, and practically no blood was lost. The patient made a satisfactory recovery.

Case 4.—A. P—, aged 33, admitted August, 1895. First noticed a swelling seven months ago; was regular till five months ago, since which time she has seen nothing. Breasts have the appearance of pregnancy. Abdomen occupied by a large well-defined tumour, rising 2½ inches above the navel. There was considerable doubt as to the nature of the tumour, but this was cleared up by the patient herself, who a week after admission was delivered of a four months fœtus. After this the swelling, though somewhat smaller in size, still remained. The pain which she suffered some months previously became worse after the miscarriage, the temperature was raised, and she could not sleep, and was rapidly losing ground.

It was decided to open the abdomen, which was done by a 6-inch incision. The tumour was found adherent over its whole surface to the parietes, to the omentum, and to the intestine. The parietal adhesions were obviously recent, being merely sticky lymph. The other adhesions were old and firm. On separating the tumour it proved to be a fibro-cystic outgrowth involving the uterus. Two peritoneal flaps were cut, and some large vessels entering the tumour tied. The peritoneal flaps were brought together by fine sutures, and the patient recovered.

Case 5.—M. N—, aged 48, admitted into St. Bartholomew's Hospital in August, 1895. For five years has been suffering severely from hæmorrhage. During the last year the tumour has increased very rapidly, has caused great pain, and has incapacitated her for work. On examination the tumour was found to extend two inches above the navel, and *per vaginam* some hard masses were felt in Douglas's pouch.

On opening the abdomen the tumour was found not to have opened the broad ligaments very widely, and it therefore came well up with the ovaries situated high on its surface. The broad ligament on the left side was tied with ease; that on the right could not be tied till the tumour was partly shelled out. The rest of the operation was completed in the usual manner, the amputation being just above the vagina. No flushing or drainage. The patient did badly from the first, there being much chloroform vomiting. She died on the fourth day.

Post-mortem note states that there was no pus or suggestion of septic inflammation in the abdominal wound, but at the bottom of the pelvis the coils of intestine were slightly adherent from recent inflammation. The hysterectomy stump looked healthy; there was no pus about it. There was a small blood-clot between the surface of the stump and the peritoneal flaps, and a portion of this was protruding into the lower part of the abdominal

cavity between two of the sutures fastening the peritoneum across the stump. This clot was believed to have been the source of infection.

Case 6.—Mrs. M—, married, aged 38, had noticed a swelling for a couple of years, and had experienced pain and discomfort for a much longer period. She was regular, but the periods were very profuse, lasting six or eight days. Eighteen months ago she was examined and told that she suffered from an ovarian cyst. On examining the abdomen, a firm lobulated tumour was felt, occupying the lower half of the abdomen, more on the right than on the left side. *Per vaginam* it was felt that this tumour was continuous with the uterus; the sound passed four inches. Palliative treatment having been tried for over a year without benefit, an operation was decided upon. This was performed at Gordon House, Mr. Gill giving the anæsthetic, Mr. Morris and Dr. Champneys being present. After making a 7-inch incision, a fibroid tumour the size of an adult's head was found. A tube could be traced extending over the tumour, but no ovaries could be clearly made out.

Coming from each side and wrapping round the tumour for about 5 or 6 inches were two bands, some 2 inches broad, full of large dilated veins; this obviously was a portion of the broad ligament which had been drawn round the tumour by its partial twisting. A strong silk ligature was passed beneath these bands on either side and tied; the bands were then divided on the tumour side of the ligature, a clamp having been previously put on to prevent regurgitation of the blood. The bladder was peeled off in the front and the peritoneum from behind; the tumour being now forcibly drawn upwards. There appeared to be a remarkably small pedicle, round which a single ligature was passed within the peritoneal flaps; the pedicle was cut across above the ligature, and the peritoneal flaps united over the stump. The patient convalesced without any drawbacks.

Case 7.—Mrs. ——, aged 40, under the care of Dr. Baines and Dr. Champneys, was the mother of three children, the youngest born ten years ago; menstruation regular and profuse. She had noticed pain for a long time, but the swelling only for a year, which has increased very obviously since. For the last six months she has been practically an invalid. An operation was decided on. After making a 7-inch incision a tumour the size of an adult head was seen under the broad ligament, connected with the uterus; the broad ligament was partially expanded over it. The ligaments were then transfixed on each side external to and below the tubes and ovaries, but as the part was so stretched it did not seem safe to tie them. Each side was then clamped just under the tubes with long forceps, and the ligament was then cut through by degrees, several forceps being put successively just on the distal side of the untied ligatures. After thus dividing the ligament for some distance on either side, the tumour, which before had been very fixed, became comparatively free, and the tension being taken off the ligament, the ligatures, which had been previously passed, were safely tied; the knife was then carried across the front of the tumour 1½ inches above the level of the bladder, the peritoneum being divided and a similar cut made behind. The tumour and uterus were then drawn forcibly upwards and the peritoneum was peeled off downwards. The uterine vessels came into view on either side, and were picked up with pressure forceps and tied between the layers of the broad ligament. The tumour and uterus were now cut off by a horizontal sweep of the knife as low down as possible; there was no bleeding. The stump was then seized by vulsella forceps, drawn upwards, and trimmed. The peritoneal flaps were then carefully sewn across the stump. The patient did well for twenty-four hours; vomiting then commenced; at this period the vomit was apparently gastric juice only. On the third day, however, this vomiting, which occurred pretty well every couple of

hours, became like pitch in colour and consistency. At this time hiccough commenced, and there was marked swelling of the abdomen; notwithstanding this the pulse, though quick, remained of good volume. The condition not improving, a copious enema was given. An hour after this the patient passed a considerable quantity of wind, and the vomiting gradually ceased. From this period she made an uninterrupted recovery.

Case 8.—Miss ——, aged 38, a patient of Dr. Parsons, of Wimbledon, had suffered for a couple of years with a tumour in the abdomen. During the last year she thinks the tumour has increased; it has caused her considerable pain and discomfort, which it did not do previously, and for some time she has practically led the life of an invalid. After consultation with Dr. Champneys and Dr. Parsons, an operation was decided upon. A 6-inch incision was made. The tumour on presenting itself proved to be a fibroid about 8 inches in diameter; on one side of it were two pedunculated nodules the size of cricket balls. There was no difficulty in drawing the tumour and uterus out of the abdominal cavity; the tubes and ovaries could be seen lying anteriorly and posteriorly upon its upper surface. A ligature was passed on either side through the broad ligament below the ovary and the tube, but as in the last case they were not tied till later, the tension being very great. A large pair of clamp forceps was then put on, on either side of the broad ligament nearer the uterus than the ligature already passed. The broad ligament was then divided in segments, portions of the distal side being successively grasped by four or five forceps. After cutting some little distance in this way it was practicable to tie the main ligatures which had previously been passed. The bladder in front and the peritoneum behind being peeled back in the usual way, the uterus was cut off just above the vaginal portion of the cervix with a clean sweep of the knife. This cut had been carried so low that no further trimming appeared to

be necessary. The antero-posterior layers of the peritoneum were then sewn across the face of the stump, seven or eight ligatures being used; there was practically no hæmorrhage. The patient did well.

The discussion on Mr. Cripps's paper was postponed to the March meeting of the Society.

Annual Meeting.

The audited balance-sheet of the Treasurer (Dr. Potter) was read.

It was moved by Dr. Routh, seconded by Dr. Horrocks, and carried—"That the audited report of the Treasurer just read be received, adopted, and printed in the next volume of the 'Transactions.'"

Dr. Routh had much pleasure in moving the adoption of the Treasurer's report. It was one which was in every respect satisfactory; it showed that there was no falling off of members, and, as a consequence, of funds. Thus in spite of the difficulty with the Medical Council, and the new form of midwifery certificate given, the number of qualifying midwives continued on the increase. There was also one cheering feature in this report: it proved that notwithstanding the enormous number of new medical societies which had cropped up all over the kingdom, this Society fully held its own, and continued to be sought after by medical men with eagerness, and esteemed as a high honour.

BALANCE-SHEET OF THE OBSTETRICAL SOCIETY OF LONDON.

(Abstract of the Receipts and Expenditure for the year ending December 31st, 1895.)

1895. RECEIPTS.		£	s.	d.
To balance from 1894		154	8	9
,, (1) 1 Subscription for 1892; 13 Ditto ditto 1893; 77 Ditto ditto 1894; 467 Ditto ditto 1895; 13 Ditto ditto 1896	= 571 realising	599	12	0
,, (2) 1 Composition Fee at £15 15*s.* £15 15 0; 1 Ditto at £10 10*s.* 10 10 0; 3 Ditto at £5 5*s.* 15 15 0		42	0	0
,, (3) Midwives' Examination Fees and Certificate for five Examinations (less half Fees returned = £25 14*s.* 6*d.*) .		591	18	6
,, (4) Sale of 'Transactions' (Longmans) . . 125 12 1; Do. do. (Society) . 1 18 2; Do. Dr. Champneys' Pamphlet and Midwives' Questions . 2 0 9		129	11	0
,, (5) Interest on Consols . . 47 17 0; Ditto on Deposit . . 1 16 9		49	13	9
Amount of Stock, 2¾ per Cent. Consols, standing in the names of the Trustees . . .	£1800 0 0			
		£1567	4	0

Audited and found correct, January 31st, 1896.

(*Signed*) WALTER RIGDEN.
A. A. KANTHACK.
T. W. EDEN.
WILLIAM DUNCAN.

1895. EXPENDITURE.		£	s.	d.
By (1) 'Transactions,' Vol. XXXVI, Printing, Paper, Binding, Delivery, Engraving, Lithography, &c. . . .		264	2	10
,, (2) Library: Books Purchased . . £35 17 10½; Binding . . . 11 14 7		47	12	5½
,, (3) Museum and Library: Rent . . . 200 0 0; Salary of Librarian . 120 0 0; Repairs to Furniture, Cleaning, Coals, &c. . 29 11 4		349	11	4
,, (4) General Meetings and other Expenses: Expenses of Meetings . £14 18 1; Stationery and Postage . 49 18 0		64	16	1
,, (5) Examination of Midwives: Fees to Examiners . . 221 15 0; General Expenses . . 65 4 3		286	19	3
,, (6) Extraordinary Expenses: In connection with issue of Dr. Champneys' Pamphlet . . 5 19 11½; Shannon File Cabinet . 3 10 0		9	9	11½
,, (7) Banking Expenses: Commission and Cheques . .		13	9	
,, (8) Balance as per Bank Book . .		243	18	4
On Deposit		300	0	0
		£1567	4	0

Report of the Honorary Librarian.

The Library now contains a total number of 4919 volumes, being an increase of 122; this addition is made up of 48 donations, 18 purchases, and 61 periodicals.

Two important early black-letter works on midwifery have been purchased at £4 the two, viz.:

(1) Hebammenbuch, 'Daraus man alle heimligkeit des Weiblichen Geschlects erlehrnen (welcherlen gestalt des Mensch in Mutter Leib empfangen),' &c., A.D. 1600.

(2) 'Der Swangern frawen und hebammen rosegarten,' A.D. 1500.

It was recommended to the Council "not to allow either book out of the Library without leave of the Council, and to keep them both locked up."

There were 776 visits of Fellows to the Library during the year, for the purpose of referring to medical literature.

JOHN PHILLIPS,
Hon. Librarian.

It was moved by Dr. CLEVELAND, seconded by Mr. BUTLER-SMYTHE, and carried—"That the report of the Honorary Librarian be received, adopted, and printed in the 'Transactions.'"

Dr. CLEVELAND, in moving the resolution, said it was refreshing to learn from the report just read that the Society's Library was in such a flourishing condition, and that so many of the Fellows appreciated the advantages afforded by it.

Report of the Chairman of the Board for the Examination of Midwives.

The number of candidates during 1895 has been larger than in any previous year. Of the 467 who applied to

be admitted to the examination 420 passed, 33 failed, and 14 were absent.

From 1872 to 1895 inclusive, the number of candidates who have applied was 2915, of whom 2482 passed, 396 failed, and 37 were absent.

The total number of midwives on the Society's register at the present time (including those who passed in January, 1896) is 2589.

The percentage of rejections in 1895 was about 7, being rather less than one half the average proportion of rejections during the twenty-three previous years. There is a continuous improvement in the class of women who present themselves, in regard to their social position, general education, and special knowledge. The diminution in the proportion of rejections is due to this circumstance, and not to any lowering of the standard of the examination.

As some objections had been raised to the form of the Society's certificate by the General Medical Council, it was thought desirable at the commencement of the year not to issue any formal certificates to successful candidates until a new form of certificate had been devised and had received the approval and sanction of the General Medical Council. The successful candidates at the January and April examinations were, therefore, supplied with temporary certificates of an informal kind until the new form of certificate had been agreed upon. The new certificates were issued to these candidates in June.

CHAS. J. CULLINGWORTH.

Dr. POTTER moved—"That the Report of the Chairman of the Board for the Examination of Midwives be received, adopted, and printed in the 'Transactions.'"

This was seconded by Dr. A. ROUTH and carried.

The PRESIDENT then delivered the Annual Address.

ANNUAL ADDRESS.

GENTLEMEN,—I have the pleasure of reporting to you that our Society is larger than ever. It has increased in the last year from 768, the largest number so far, to 779. This number is made up of 763 ordinary and 16 honorary Fellows.

During the past year 14 Fellows have resigned and 10 have died; while, on the other hand, 34 new Fellows have been elected.

The Treasurer's balance-sheet has been read, and must be regarded as quite satisfactory.

The report of the honorary Librarian has informed you of the growth of the Library. The new sub-librarian has fully justified her election by the Society.

The report of the Chairman of the Board for the Examination of Midwives has shown that, in spite of the difficulties of the past year, the numbers applying for our certificate are greater than ever. The numbers for the ten previous years are as follows:

1885	82	1890	207
1886	102	1891	258
1887	127	1892	289
1888	153	1893	339
1889	170	1894	432

In the past year the applicants have numbered no less than 467.

THE SOCIETY AND THE GENERAL MEDICAL COUNCIL.

In my Inaugural Address last year I was chiefly concerned with the relations of the Society to the General

Medical Council regarding the examination and certification of midwives. We were face to face with a difficulty, and my address ended, perforce, in a situation of anxiety and suspense. A local congregation of the British Medical Association had denounced us to the General Medical Council, and that body had addressed to us a series of letters which were of a different character from those which we had been accustomed to receive, or which we either expected or deserved.

The part which your President had to play in the early part of his year of office was that of the Devil, and is, as you remember, thus described:

> "The happier state
> . . . which follows dignity might draw
> Envy from each inferiour; but who here
> Will envy whom the highest place exposes
> Foremost to stand against the Thunderer's aim,
> Your bulwark?"

I have said that your President appeared (for this occasion only) in the character of Satan. Who the Thunderer was it is more difficult to say; there were so many of them, all thundering away as loud as the size of their organs would permit. The "tone" of the thunder was not remarkable, but it may have been designed with the view of producing what are known in acoustics as "overtones," and which result from certain combinations of notes of different pitch, or from over-blowing certain wind instruments, especially small ones, by which the tone appears higher than it really is (see Helmholtz, 'Tonempfindungen').

I am thankful to remember that, amid all this din, our Council kept their heads and came to calm and judicial decisions.

But if your President appeared in the character of Satan, it is hardly too much to say that the Society might have been pictorially represented as Andromeda chained to a rock, and momentarily expecting destruction at the hands or teeth of a dragon of thirty segments,

whose five caudal vertebræ were being pinched and otherwise irritated by a small but restless tribe of Hyperboreans.

It is known to physiologists that an irritation applied to an afferent nerve will first produce reflex movements on the same side of the body; if more intense these may become bilateral; while if still more violent it may cause general convulsions. This fear must have been present to the minds of many, and indeed premonitory symptoms were not absent. The advent of a Perseus was fervently prayed for; but, after all, no Perseus was needed, for a short conversation with the courteous and venerable head (at his own request) sufficed to show that there was no desire on one side except for what was right; and that the irritation of the caudal vertebræ had entirely failed to affect the integrity of the nervous system of the dragon on the other.

In accordance with the views of the General Medical Council, we have modified the certificate granted to our midwives. In doing so we have safeguarded our principles, while we have removed all just cause of offence.

Our certificate had been large—framed, no doubt, on existing certificates; it had been decorated with a figure of Lucina; it had the seal of the Society appended to it; it was signed by the President, Secretaries, and Board of Examiners.

In all these respects it has been modified: it is smaller; Lucina has departed to the celestial regions; the seal (which we were legally advised was properly only appended to the documents of a corporate body) has been removed; and the signatures are now confined to those of the Chairman of the Board of Examiners and one Secretary.

Size appeared to us unimportant, Lucina was only an ornament, and it is hoped that her aid will be none the less present to us now that her image has re-sought those spheres from which she descended to decorate our certificate. If we had no legal right to a seal, that ought to disappear; and all that was needed in the way of signa-

tures was that our certificate should be signed by the proper officials.

The wording of the certificate has also undergone alteration. It formerly ran thus:—"We certify that has passed to our satisfaction the examination instituted by the Obstetrical Society of London, and that she is, in our opinion, a skilled midwife, competent to attend Natural Labour." As amended it runs as follows:—"We hereby certify that has passed to our satisfaction the Examination in Midwifery instituted by the Obstetrical Society of London.

"*Note.*—This certificate confers no legal qualification to practise under the Medical Acts."

It will be observed that the old certificate expressed the opinion that its holder was "a skilled midwife," and also that she was "competent to attend natural labour."

The new certificate omits the words "skilled midwife," but states in return that she has passed an examination in "midwifery," which is much the same thing.

The words relating to her competence to attend Natural Labour were really a limitation; but, as the Medical Council preferred that they should be omitted, we have omitted them.

The note at the bottom of the new certificate was not added at the suggestion of the General Medical Council, but by the deliberate vote of our own Council, who felt that it constituted a complete refutation of the statement that our Society encouraged or permitted the use of its certificate for the purpose of engaging in medical practice. To those who use it as it is intended to be used, namely, as a means of assuring inquirers that its holder has undergone a certain training and passed a certain examination, this addition is no detraction from its value. To those who would use it (if any such there are) for improper purposes, the note, printed as it is in red ink, would be an effectual bar.

In accordance with the wish of the Medical Council, our certificate is called a Certificate, and not a Diploma,

and the latter word has been replaced by the former in all documents relating to the subject. This is a small matter, but it is only an instance of the object which our Council aimed at throughout the negotiations with the General Medical Council, namely, to remove all possible causes of misunderstanding where these did not entail sacrifice of principle; but to refuse all changes (such as the insertion of the new-fangled term "nurse-midwife") which appeared to them to sacrifice a principle. In this instance they took their stand on the language of the Book of Genesis, dating from a pre-General-Medical-Council era.

If we compare gains and losses after these changes, we shall see that our certificate has lost in size, it has lost Lucina, it has lost the seal; in short, it has lost its ornaments. In my opinion that is all that it has lost. On the other hand, it has gained the *imprimatur* of the General Medical Council, which it never had before, and is henceforward in an unassailable position.

It is to be doubted whether those who attacked us last year (and on previous occasions) would have done so, had they foreseen the results of their attack.

I am not intending to discuss the question whether our old or our present certificate is the better worded. I still prefer our old certificate, and think it is better drawn, partly on account of the limiting clause which it contained. But there can be no doubt that our present certificate carries vastly increased weight, and that, as I ventured to prophesy last year, the sifting of the question has only redounded to our justification, and to the establishment of our examination upon a firmer footing than ever.

Our object has never been to bolster up midwives against doctors; it has been to take care that, so far as lay in our power, the poor shall be able, when they ask for a midwife, or at least for one of the Society's midwives, to procure a woman who shall not murder them, either by infecting them, or by perpetrating surgical horrors on them, or by failing to recognise a dangerous condition requiring the care of a medical man. I believe that

many poor women in the past, and more in the future, will have cause to bless the Society.

How far the changes have been acceptable to midwives I have no knowledge, but the numbers presenting themselves for our new certificate have been larger than ever.

We cannot, as a profession, too clearly recognise that our position depends not on the decorations of individuals nor on the artificial regulations of social precedence, but on our usefulness; and that at the head of that usefulness stands our usefulness to those who are most miserable and most wretched. The highest title of any medical man is that of *servus servorum;* the lowest position is that of self-seeking.

If our profession has been honoured in the past, and if it is still honoured in the present, it is because the good of mankind, and especially of those who have none to help them, has been put first, and personal advantage last. It is in hospital practice, and in practice among the poor, where pecuniary advantage is absent, that our pleasure is most unmixed. In all practice, the more we are able to regard payment as merely an incident, the better for us.

On the other hand, nothing so much degrades our profession as the spirit of Trades-unionism, which not only will certainly be resisted and frustrated by the public opinion of our country, but inevitably places us on a lower level. That Parliament will ever sanction any measures which tend to subordinate the interests of the sick to those of the doctor is inconceivable; but the mere suspicion of such a movement is to be earnestly deprecated in the best interests of our profession. We have inherited a noble birthright and a noble tradition; let us see to it that our shield remains untarnished.

Of no department of medical practice is this so true as of that which cares for poor mothers and their infants. The interests of these are paramount, and those of doctors or midwives are comparatively unimportant. If midwives attempt to capture this class for their own benefit, they will certainly fail. If medical men attempt to stand

between the poor and their safety, they will certainly fail; but they will also lose an honourable position, which is far superior to any which midwives have ever held.

In the past year I have been convinced of one fact, which is that sentiments like these are held by honourable medical men, but that many of them have not had the courage of their opinions. I think this is due not only to timidity, but also to the reluctance which many high-minded men feel to being drawn into a vortex of clamour and abuse, where weapons are used with which they cannot fight.

Alterations in the Laws.

In November a General Meeting was called to consider some revisions of Chapter VI of the laws relating to the election of Officers and Council.

The amendments proposed by the Council had two objects in view: first, to protect, and even to extend the privileges of Fellows in electing the Officers and Council; and secondly, to guard against a surprise-vote, concocted in secret and suddenly sprung upon the Society.

At this meeting the main objects were accepted without debate, but a good many suggestions were made with the view of improving the Council's scheme by increasing the secrecy of the voting.

Various references were made by several speakers to methods in vogue at the Royal College of Surgeons of England, and also at its sister college in Ireland, but no one had embodied the scheme in an amendment in a concrete form.

There seemed, however, to be a strong feeling among many in favour of some such scheme, and I consequently drew up a slip to be sent to all Fellows with their notice of the Annual Meeting. This was approved by the Council, and I read it to the Society at the December meeting, where I think I may say it was approved also.

It runs as follows :—" Every Fellow voting *in absentiâ* is requested to erase superfluous names from the balloting list, leaving not more than the number of names required, to enclose his voting paper in a closed envelope, to sign his name and address on the envelope for purposes of identification, and to enclose this envelope in another directed to the President not later than the day before the Annual Meeting. After identification of the Fellow's name and address, the envelope marked with the name will be destroyed, and the voting paper put into the ballot-box."

It will be seen, on comparing Chapter VI of the laws in its amended with its previous form, that the following are the changes really introduced :

In Sections 1 to 4 no change has been made. In Section 4, as formerly existing, the list of those nominated by the Council was sent to every Fellow, to be used as a balloting paper at the Annual General Meeting. Those within the London postal area were obliged to vote in person or not at all ; those outside the London postal area were at liberty (Section 5) to vote by signing and returning the balloting list, under cover, to the President before the Annual Meeting. In both cases any name could be substituted for any other without further ado. By this means it seemed very unlikely that amendments would coincide in sufficient numbers to gain the majority necessary to effect any change. On the other hand, it was of course possible, by sufficiently canvassing, to produce sufficient agreement to gain a majority among voters ; and it was also possible, by sufficient secrecy, to flood the ballot-box with an unexpected wave of voting papers, which, in the absence of any knowledge of what was impending, and consequently in the absence of many of the votes of the supporters of the Council, might carry any persons, and consequently any policy, however disastrous to the Society.

By the old system acquiescence in the selection of the Council was easy, but change was difficult except by

means of a resort to secret measures. By the law as amended the following course has to be pursued :

A list of those nominated by the Council is to be sent to each Fellow (Section 4) "on or before the fourteenth day of December, together with an explanatory extract from the laws of the Society (Chapter VI, Sections 4 and 5)." This early date is necessary in order to carry out the subsequent proceedings, as will shortly appear.

On receipt of this list, amendments may be proposed according to the provisions of Section 5 :

"If it be desired to propose any Fellow as officer or member of Council, other than those whose names stand upon the list recommended by the Council, the name of such Fellow, duly proposed by one Fellow and seconded by two other Fellows, shall be sent to the President before the first Wednesday in January, after which date no new name shall be proposed. It shall be the duty of the honorary Secretaries, in the event of any such additional nominations being received within the specified time, to prepare and transmit to each Fellow by post, with the notice of the Annual Meeting, a balloting list, containing (1) the names of those nominated by the Council, and (2) the additional nominations, specifying the post for which each Fellow is nominated, together with the names of his proposer and seconders."

There are three points to be noted in this section ; (*a*) that amendments must be duly proposed and seconded, and (*b*) that the names of the proposer and two seconders are published. This provides in the first place that those who propose amendments shall do so seriously and with a full sense of responsibility ; secondly, that the Society shall know who the gentlemen are who propose to amend the nominations of the elected executive of the Society ; (*c*) thirdly, that time is given for the circulation of these amendments before the Annual Meeting.

By Section 10 it is declared that, "in the event of no additional nominations being received within the specified time, the President shall at the Annual Meeting declare

the officers and members of Council, nominated by the Council, to be duly elected, no ballot being in such case necessary."

Clause 6 is an amplification of the old Clause 6, to bring it into accordance with the above changes, and to specify the procedure with more accuracy.

Clause 7 is an important extension of the privileges of Fellows, and provides that all Fellows, whether town or country, shall be able to vote by voting papers if they find it more convenient. This extension has worked well at the Royal College of Surgeons, and the Council thought that it would increase the interest of Fellows in the Society.

It seemed hard that a gentleman residing at a considerable distance, though within the metropolitan postal area, should lose his vote if prevented from attending the Annual Meeting in person, while country members, who perhaps took less interest in the Society, could exercise their right of voting.

The Council desires that all Fellows shall exercise their vote intelligently and with a full sense of responsibility, and that the Council shall, as far as possible, represent the whole Society.

Clause 8 specifies the manner of voting in person at the Annual Meeting.

Clause 9 specifies the mode of voting *in absentiâ* by voting papers. It is with this clause that the slip already described will be incorporated if it is approved on trial.

Clause 11 remains as heretofore.

It is hoped and believed that these alterations will have the effect of eliciting any opinions which may be held by Fellows who do not agree with the proposals of the Council, and will also render impossible any cabal fostered in secret, and sprung at the last moment upon the Society in a manner not customary among English gentlemen.

On the present occasion, no amendments to the nominations by the Council having been received within

the specified time, all the gentlemen so nominated are elected without a ballot.

New Honorary Fellows.

The only ballot to be taken to-night is for the election of Dr. Braxton Hicks as an honorary Fellow.

It occurred to my predecessor, Dr. Herman, that Dr. Braxton Hicks well deserved this great honour, not only on account of the scientific work which has made his name famous, but also on account of the great and continuous interest which he has taken in our Society.

The title of Honorary Fellow of our Society is one which anyone might covet. It has been held by many highly distinguished men; it is given purely for merit, and its conferment is hedged round with strict safeguards, as will be seen on reference to Chapter III of our laws.

The person in question must be nominated in writing, either by or through the President, at one meeting of the Council after due notice; he is balloted for at a subsequent meeting of the Council, a majority of nine tenths of the Council being necessary for his nomination; he is balloted for at the Annual Meeting.

It is expressly provided that the Council are not bound to fill up vacancies among the honorary Fellows.

It may be well to remind the Society that corresponding Fellows are no longer eligible, all mention of them having been intentionally omitted from the last revision of the laws.

It is to be hoped that, should the Society elect Dr. Braxton Hicks to-night, he will accept this distinction—the highest which it is in the power of the Society to confer,—together with the heartfelt wish that he may be long spared to adorn it.

Mr. Walter Heape's Researches.

An excellent paper by Mr. Walter Heape on the "Menstruation of Monkeys," published in the 'Philosophical Transactions,' which carried our knowledge of the subject to a point of accuracy never before reached, suggested to your President that the Society might aid Mr. Heape in the investigation of menstruation in women, the knowledge of which is still in an imperfect condition. He therefore suggested to the Council the appointment of a committee, which met Mr. Heape, by whose aid a system has been arranged by which specimens bearing on the subject can be sent to Mr. Heape at the Anatomical Museum, Cambridge. Mr. Heape provides bottles in which such specimens may be packed, together with papers for recording the necessary facts connected with each case as to age, menstruation, cause of death, date of death, &c.

It is to be hoped that all Fellows will endeavour to send specimens to Mr. Heape, and thus to aid in an investigation which should prove of the greatest value in the elucidation of a function which stands at the foundation of our knowledge in all that concerns diseases of women.

I feel that Mr. Heape is, of all others, the man who is most likely to finally settle this important and much debated question, and I think this Society will be honoured if it aids in such a consummation.

The Dinner to Foreign Guests.

The occasion of the meeting of the British Medical Association in London at the end of July and the beginning of August brought to our city a large number of foreign guests, and it was felt that our Society had the opportunity of offering hospitality to many whom it would be their honour as well as their privilege to meet. A dinner was therefore arranged at the Whitehall rooms of the Hôtel Métropôle on August 2nd, to which the

following accepted invitations:—Professor A. Martin of Berlin, Professor Lazarewitch of St. Petersburg, Professor Cordes of Geneva, Professor Curatulo of Rome, Professor Cautacuzène of Bucharest, Dr. Stuart of Brooklyn, N.Y., and Dr. Muret of Lausanne.

The dinner, arranged by our honorary Secretaries, Drs. William Duncan and Dakin, was excellent, bright, and not tedious, and we had the pleasure of hearing speeches from most of our guests in English, which must have excited not only our kindly feelings from the cordiality of the sentiments which they expressed, but our admiration for their competence as linguists.

Obituary Notices.

Mr. George Philip Philps died in January, 1895, at the age of fifty-one. After practising for some twenty-four years in Peckham he moved to Kensington. Soon after this he had a severe attack of influenza, from which he never completely recovered, being always subsequently a sufferer from heart troubles. He left a widow and family.

Dr. H. W. Maunsell died on February 21st from bronchitis following influenza after a week's illness. He was born in Dublin in 1847, his father being a solicitor in that city. He was educated at Trinity College, Dublin, and after qualifying went to Melbourne, where he held the post of Resident Medical Officer for three years. He then occupied a similar and better paid post at the Westland Hospital, Hokatika, which he soon relinquished in consequence of increasing private practice. He went back to Europe in consequence of an attack of hæmoptysis caused by a fall. After two years' absence he returned to New Zealand and settled at Dunedin, being soon after appointed surgeon to the Dunedin Hospital. He was afterwards Lecturer on Surgery in the University of Otago. He was again obliged to return to Europe on account of

failing health, and some two years ago settled down to practise in South Kensington. As a surgeon he possessed a considerable reputation, especially in the department of intestinal surgery, in which he made several improvements, some of which (as his method of suturing divided intestine) are considered by one well able to judge to be in advance of all contemporary methods. He is described as an enthusiastic surgeon, an excellent artist, and a charming companion.

Mr. John Jones died on February 14th, at King Street, Regent Street, at the age of fifty-eight.

Mr. Edward John Chance died at the age of eighty-eight, on February 25th, at his house in Russell Square. He had practised in the City, and was formerly Consulting Surgeon to the Metropolitan Hospital, and also Senior Surgeon and Honorary Secretary to the City Orthopædic Hospital.

Mr. Hugh Thomas, of Small Heath, near Birmingham, was killed by an accident on May 22nd. In crossing the road he was knocked down by a butcher's cart, which broke three ribs and lacerated the liver. Not feeling the damage much at the time, he died the day after the accident. Mr. Thomas was born in 1850 at Beaumaris. He was educated at Queen's College, Birmingham, being distinguished as a student. After holding a resident post at the Queen's Hospital he settled in practice at Small Heath, a suburb of Birmingham. He was not only active as a medical practitioner, but as a citizen, and sat as Councillor for the Bordesley Ward. He was a keen politician, and took great interest in the well-being of the poor.

Mr. James Prytherch James, of Eastleigh, died at Barton-under-Needwood of heart disease after influenza on June 17th, at the age of forty-one.

Dr. Frederick Barnard Betts died on September 4th at Antofagasta, Chili, of septic pneumonia, after an illness of only eight days, aged twenty-eight. He was educated at Westminster Hospital, where he held all the resident

posts. His health became delicate; he made three voyages to South America in the R.M.S. Iberia as ship's surgeon. He then returned and acted as house surgeon to Queen Charlotte's Lying-in Hospital. After this he returned to South America and acted as surgeon to the Huanchaca Silver Mine and Railway at Antofagasta, and took the degree of M.D. at the University of Santiago. He was of an exceptionally bright and cheerful disposition, which quickly won the hearts of those among whom he settled, and his early death spread universal dismay amongst Europeans and Chilians alike. His funeral was attended by over 2000 persons, including the foreign Consuls. The 'Chilian Times' of September 11th says of him: "Although but little more than two years resident in Antofagasta, the universal grief manifested at his death and at his grave testified how much he was respected and beloved. His memory will linger long in many a grateful heart. . . . . Young, gifted, terribly in earnest, and thoroughly devoted to his profession, he was only happy when busy relieving the pains and sufferings of his fellow-men."

Dr. Richard Hodges died on November 28th in Camden Road, in his seventy-fifth year. He was educated at St. Thomas's Hospital, and was awarded the Fothergill Gold Medal in 1851, for an essay on 'Hæmorrhage,' by the Medical Society of London. He was one of our original Fellows, and had contributed three papers to our 'Transactions.'

Dr. William Richard Grove died on Christmas Eve at St. Ives, Huntingdonshire, aged fifty-seven.

Dr. George Hugh Kidd died on December 26th, at 58, Merrion Square, Dublin, at the age of seventy-one, his death not being altogether unexpected. Dr. Kidd was born of parents of Scottish extraction at Armagh. He graduated at Edinburgh in 1845 with the distinction of a gold medal. His thesis was on the subject of vaccination, the especial point being the necessity of re-vaccination. On his return to Dublin, at about the

age of twenty-one, he was appointed Demonstrator of Anatomy, and afterwards Lecturer on Anatomy and Physiology, in the Park Street School of Medicine, at which place he became, in 1849, the Lecturer on Anatomy, which post he held for nearly ten years. After this he entered into private practice, at first general, afterwards obstetrical; and in this department he was one of the leaders in Dublin. He was appointed Surgeon, and afterwards Master, to the Coombe Lying-in Hospital. He was elected a Fellow of the Royal College of Surgeons of Ireland in 1844, a member of the Council in 1872, and President in 1875. He was at various times President of the Irish Royal Academy of Medicine, and of the Obstetrical and Pathological Societies of Dublin. He was an honorary Fellow of our Society, and of the Obstetrical Society of Edinburgh, besides corresponding and consulting appointments. Among many works of public utility in which he took great interest was the establishment of an institution for imbecile children. He was the first direct representative of the Irish practitioners on the General Medical Council, and held the office for nine years. Dr. Kidd was a man of strong convictions, both in politics and in other matters, and these convictions he is said to have been in the habit of expressing strongly. A writer of one of his obituary notices says, "He was essentially masterful, and, although he was not always right, there were few who, in his days of health, cared to combat his propositions, vigorously and pointedly put as they were." He leaves a widow and young children. He had the comfort of being attended in his last illness by old friends. Those who knew him speak strongly of his honour, uprightness, and fearlessness, than which there can be no finer qualities.

Review of the Work of the Society.

The work of the Society at its meetings has not been less interesting than in past years.

At the January meeting a specimen was shown by Dr. Cullingworth of a pyosalpinx simulating a tubo-ovarian abscess. The disease was believed to have existed for fourteen years, though the patient felt well after the first five months. The collection discharged by the rectum, four ounces of highly offensive pus escaping in this way. The tube was removed, and no attempt made to close the hole in the rectum. The patient made a good recovery.

At the same meeting Dr. Stevens showed a fœtus with absence of urethra, and with ascites obstructing labour.

The fœtus was macerated, the fluid mostly ascitic, three and a half pints escaping on perforation of the diaphragm, while the bladder contained about six ounces. The bladder ended blindly beneath the symphysis, and the penis contained no urethra or corpus spongiosum.

The condition of the upper urinary tract was curious; the left ureter was enormously distended and tortuous, the left kidney appeared normal; the right ureter was very small, the right kidney atrophied, and containing two cysts. The left hypogastric artery was a mere cord, though pervious. The case was one of multiple congenital defects. The analysis of the fluid in the bladder is not given.

Dr. Stevens recognised the gravity of the case, and delivered in the proper manner by opening the thorax and then the abdomen through the diaphragm.

At the same meeting Dr. Holt showed a fœtus papyraceus, which presented together with a fœtus of about seven and a half months.

Dr. Amand Routh also showed a uterus with a cancerous cervix removed by the vagina, together with a parovarian cyst so tense as to be mistaken for a fibroid.

Dr. Des Vœux showed a placenta with hæmorrhage.

Dr. John Shaw read a paper on peritonitis, its nature and treatment.

At the February meeting Dr. Remfry showed a drawing and a photograph of a woman, aged 27, without breasts or uterus. The pelvis seemed to be normal.

Dr. Griffith showed a patient with a flattened pelvis having a conjugate of 3¾ inches, on whom he had performed symphysiotomy in the previous October. The child died during delivery. The patient had occasional slight incontinence of urine on exertion.

Mr. Butler-Smythe showed a dermoid cyst containing about two pints of pill-like bodies, believed to consist of altered fat. The condition is rare.

Dr. W. Duncan showed for Mr. Dawson a fœtus with numerous malformations.

A valuable paper was read by Dr. Probyn-Williams and Mr. Lennard Cutler on the Temperature, Pulse, and Respiration during Labour and Lying-in.

Their observations led them to conclude that the low rate of the pulse after delivery as given in the text-books is exaggerated, and that chloroform tends to produce a high pulse-rate after delivery.

As to tension, in one case low tension during delivery was followed by hæmorrhage after delivery.

At the March meeting Dr. Lewers showed a specimen of tubal mole. The correctness of the title was challenged by some of the Fellows, and the case would have been more complete if microscopical sections had been made. On the other hand, the condition both of the breasts and of the uterus make it probable that the case was of the nature described.

A couch and some instruments were shown by Drs. Wise and MacNaughton Jones.

Dr. Inglis Parsons read a paper on the Disintegration of Organic Tissue by High-tension Discharges, being a series of experiments on the effects of voltaic interrupted currents passed through beef, with the view of improving the treatment of malignant disease by electricity.

The paper dealt with technical details falling rather under the province of electrical engineers than of medical

men, and I can express no opinion concerning the author's position.

But a very distinguished medical electrician, Dr. Lewis Jones, who was present as a visitor, denied that the current produced any results, under the circumstances detailed, except those due to the generation of heat, and asserted that the effect was not due to occult influence, but that the meat was merely cooked.

At the April meeting Dr. Cullingworth showed a specimen of a complete tubal abortion; and also a diffuse (non-capsulated) myoma of the uterus actively growing in a woman aged fifty-five, whose family history was interesting, inasmuch as both in her, and in the only two of her six sisters who reached the age of fifty, menstruation still continued. In the patient's case menstruation continued until the operation at the age of fifty-five; in the case of one of her sisters the menopause did not occur till the age of fifty-three, and in that of the other not till the age of fifty-eight.

Dr. William Duncan showed specimens of a degenerating uterine myoma, of an œdematous myoma, of a double tubo-ovarian cystoma, and of an early stage of tubo-ovarian cysts.

Dr. Lewers showed a specimen of a tubal gestation of three months, operated on before rupture, containing a second dilatation of the Fallopian tube on its uterine side, suspected by the exhibitor to be a tubal mole; the specimen would in this case show twin tubal pregnancy in the same Fallopian tube.

Dr. Remfry read a paper containing a list of ovariotomies in women over eighty (ten in number), including a case aged eighty-three complicated by epithelioma of the vulva.

Dr. Hubert Roberts also read a paper on the common form of "white leg" after confinement.

The author gave details of sixteen original cases, and urged that the commonest form of "white leg" is not that usually considered typical, but is that in which thrombosis of the veins is present without marked

obstruction of lymphatics or brawny hardness; he also suggests that in such legs there are not necessarily signs pointing to sepsis, but rather to a blood-change associated with hæmorrhage at the time of labour; that the thrombosis begins usually in the uterine and pelvic veins; that it affects the femoral and saphenous veins, and that the pyrexia present does not necessarily indicate sepsis.

The paper was of much interest, the cases well related, and their pathology intelligently debated. It gave rise to a very interesting discussion.

I may perhaps be allowed to express the hope that the Society may be presented with more work of this class.

At the meeting in June, Dr. William Duncan showed a specimen of missed abortion, the pregnancy having apparently advanced to the fourth month, and retained eight months longer, the pregnancy having thus, in a sense, lasted a year; also a case of sloughing fibroid removed successfully by abdominal hysterectomy; also a case of unruptured tubal gestation removed by abdominal section; also a case of conjoined twins, of the variety known as Thoracopagus.

Dr. Playfair showed a cancerous uterus, two months pregnant, removed by vaginal extirpation, and a case of sarcoma of the body of the uterus treated in the same way.

Mr. O'Callaghan showed an œdematous myoma.

Dr. Lewers showed six specimens of supra-vaginal amputation of the cervix for cancer, in which eight years, seven years, five years, two years, and two years had respectively elapsed without recurrence.

Dr. Addinsell showed a fœtus with many deformities.

Dr. Eden gave a most interesting and instructive demonstration of the placenta, illustrated by lantern slides and microscopical sections. Three stages of development were distinguished, and great stress was laid on the formation of the intervillous spaces in the maternal part of the placenta. These spaces are, according to Dr. Eden, made up (1) of the space existing primarily between the decidua and the chorion; (2) of spaces formed by the

destruction of decidual tissue; (3) of glandular and vascular channels opened up in the same way. He believed the circulation through these to be chiefly promoted by the uterine contractions.

Mr. Doran took advantage of the magic lantern to show a microphotograph of a placental polypus, in which, though taken from a museum specimen, the villi of the chorion were plainly visible.

At the meeting in July Mr. Doran showed (for Dr. Walter Lowe and Mr. Harvey Bradbury) a specimen of Acardiacus mylacephalus, carefully dissected.

Dr. Blacker showed an interesting specimen of a uterus with fibroid tumours and carcinoma of the cervix, removed post mortem from a patient on whom eight years previously the operation of oöphorectomy had been performed for hæmorrhage. The results of the operation were that no blood was subsequently lost, and that the patient lost all sexual feeling, which had previously been well marked. Eight years later cancer of the cervix supervened, and she died semi-comatose, both ureters being much dilated. The kidneys showed signs of chronic interstitial nephritis.

Mr. Targett showed an interesting specimen of acute suppuration and sloughing of the ovaries after parturition, the Fallopian tubes being unaffected.

The same gentleman also showed epidermic casts from the vagina, caused by the introduction of cylinders of some medicament. In ten months no less than fifty casts were passed.

Dr. Amand Routh showed the macerated skull of an anencephalic fœtus which had been exhibited to the Society in 1893: this will be found with a careful report by Drs. Routh and Giles, and two woodcuts, in our 'Transactions.'

Dr. Cullingworth showed a pedunculated fibro-myoma of the broad ligament with twisted pedicle.

Dr. Playfair showed a specimen of tubal abortion.

Dr. Galabin showed a very interesting fœtation in a

rudimentary horn of the uterus removed unruptured by abdominal section.

Dr. Galabin also showed some improved sanitary towels, and made some remarks on their use in high altitudes.

Mr. Doran read a paper of great interest on placental polypus, of which he believes that fibrinous polypus is merely a variety.

The paper exhibits the care, the accuracy, and the wide pathological knowledge to which we are accustomed from the pen of Mr. Doran, and also contains some interesting remarks on a singular disease, known as "deciduoma malignum," of which I doubt not that we shall have specimens and sections before long.

At the October meeting some midwifery instruments presented by Professor Lazarewitch were shown.

Dr. William Duncan showed specimens of ruptured tubal gestation and of double pyosalpinx.

A paper was read by Drs. Stevens and Griffith on the variation in height of the fundus uteri above the symphysis pubis during the puerperium, graphically described by charts.

Dr. G. Drummond Robinson read a paper on certain micro-organisms of obstetrical and gynæcological interest. In the course of this interesting communication, which was illustrated with lime-light pictures of microphotographs, special attention was called to the *Streptococcus pyogenes*, which was constantly found in the blood and tissues in fatal cases of puerperal sepsis; to the absence of all microbes from the cavity of the uterus in normal puerperal cases; to the fact that many different micro-organisms are found in the uterine cavity, and in the substance of the mucous membrane in cases of puerperal sepsis; and to the fact that, of these, the *Streptococcus pyogenes* seems alone to possess the power of penetrating the uterine wall, including veins and lymphatics, producing in some cases death without any obvious lesion, and in others suppuration in various tissues. Its presence in the clots in some cases of phlegmasia dolens is also noted.

Other micro-organisms noted included the *Bacillus coli communis*, and an instructive case was related in which this was found in the uterine discharges during life, and after death in the uterine cavity, peritoneum, and heart's blood. This case was one of incarceration of the retroverted gravid uterus with intestinal obstruction.

The gonococcus was also described, and its relation to gonorrhœa discussed.

In November a solid tumour of doubtful nature was shown by Dr. Leith Napier.

A small uterine myoma undergoing necrotic changes in a young subject (aged twenty-nine) was shown by Dr. Cullingworth.

An œdematous fibroid associated with pregnancy was shown by Dr. Galabin, and a specimen of tubal gestation by Dr. Remfry.

A paper was read by Mr. Bland Sutton on a case of tubo-uterine pregnancy with primary intra-peritoneal rupture; and a learned and very interesting paper was read by Dr. Giles on a case of uterus didelphys, including an analysis and classification of the several varieties of this malformation, a summary of many illustrative cases, and an excellent bibliography.

It will be noted that some of the most valuable papers have been contributed by the junior Fellows of the Society. There are many, however, of our junior Fellows who, with ample clinical material, have not yet added to the literature of our 'Transactions.' It can hardly be denied that, while our immediate interest may be equally divided between the inspection and discussion of specimens and the reception, appreciation, and discussion of papers, it is on the latter that the permanent reputation of our Society, in a scientific sense, mainly rests. If we are, as we may hope we all are, jealous of the reputation of our Society, and anxious to keep it in the van of similar societies all over the world, it surely becomes our duty to give ourselves some trouble to ensure this pre-eminence. I believe that, in some cases, reluctance is a sign of modesty.

I would fain believe that it is never a sign of any quality less admirable; but in this, as in so many other questions, it is true that—

"Ce n'est que le premier pas qui coûte,"

and that a first paper, like a first speech, is mainly formidable in prospect, while a second effort costs the writer far less anxiety. Let me, therefore, appeal to those who have the necessary opportunities, but have not yet had the necessary courage, to acquire that valuable property as soon as possible, and let me assure them of the kindly interest which will attend the birth of their maiden effort.

The reputation of each Fellow is affected by the reputation of our Society (the converse being equally true), and it is our duty to keep this joint reputation as high as may be. But, besides this, I trust that the possession of some reputation as a scientific investigator is still a valuable help to every one who has his position to make in obstetric medicine, and I know of no way so natural nor so easy for the attainment of this as the contribution of good scientific papers to our 'Transactions.'

There is another fact to be remembered, namely, that the time of life and position when there is more leisure, and when private practice is not yet engrossing, is just the best time for many kinds of laborious research which become impossible later; and, in this connection, I am often reminded of Virgil's advice to the husbandman, to make —not "hay while the sun shines," but—to make use of rainy days to prepare for the harvest:

"Frigidus agricolam si quando continet imber,
Multa, forent quæ mox cœlo properanda sereno,
Maturare datur."

I have now, gentlemen, reviewed the position of the Society in all its aspects. I think we may comfort ourselves with the thought that our survey is satisfactory, and I hope that we may look forward to a year of good solid work, of friendly discussion, and of continued goodwill.

Dr. J. Watt Black in eulogistic terms moved—"That the thanks of the meeting be given to Dr. Champneys for his most interesting address, and that he be requested to allow it to be printed in the next volume of the 'Transactions.'"

This was seconded by Dr. Galabin, and carried by acclamation.

Dr. Galabin, in seconding the motion, said that it would at all times be a great advantage to the Society to have a President of such distinction at its head. During the past year, however, this advantage had been specially manifest since two questions of such delicacy and importance had arisen for settlement—the question of the diploma given to midwives, and the alteration of some of the most important laws of the Society. He thought that the Society owed its thanks to the President, not only for the interesting description of the course of these events in his address, but for the diplomatic tact which he had shown in effecting the settlement with the General Medical Council, and in guiding the deliberations of the Council of the Society.

The President announced that Dr. J. Braxton Hicks was duly elected an Honorary Fellow of the Society, also that the Officers and Council shown on the printed list as recommended by the Council were duly elected.

Officers and Council.

President.—Francis Henry Champneys, M.A., M.D.

Vice-Presidents.—William Duncan, M.D.; John H. Galton, M.D.; Peter Horrocks, M.D.; Thomas Cargill Nesham, M.D. (Newcastle-on-Tyne).

Treasurer.—John Baptiste Potter, M.D.

Chairman of the Board for the Examination of Midwives.—Charles James Cullingworth, M.D.

Honorary Secretaries.—W. Radford Dakin, M.D.; John Phillips, M.A., M.D.

Honorary Librarian.—Walter S. A. Griffith, M.D.

Other Members of Council.—Thomas Rutherford Adams, M.D. (Croydon); John Walters, M.B. (Reigate); Joseph Thompson (Nottingham); Albert Kisch; Lovell Drage, M.D. (Hatfield); Willoughby Furner (Brighton); Percy Boulton, M.D.; Amand Routh, M.D.; John James Tweed, jun., F.R.C.S.; Constantine Holman, M.D.; John D. Malcolm, M.B., C.M.; Montagu Handfield Jones, M.D.; William Rivers Pollock, M.B., B.C.; Leonard Remfry, M.A., M.D.; John Henry Salter (Kelvedon); Harold A. Des Vœux, M.D.; Claude Clarke Claremont; Walter W. H. Tate, M.B.

It was moved by Dr. Cullingworth, seconded by Dr. Taylor, and carried—"That the thanks of the meeting be given to the retiring Vice-President, Dr. James Duncan, and to the other retiring members of Council, Dr. Fletcher Beach, Dr. Boxall, Dr. Donald (Manchester), Dr. Gow, Dr. Griffith, Dr. Harper, Dr. Pearson, Mr. Bland Sutton, and Mr. Targett."

It was moved by Mr. Alban Doran, seconded by Dr. Spencer, and carried—"That the best thanks of the meeting be given to the retiring Honorary Secretary, Dr. William Duncan, and the retiring Honorary Librarian, Dr. Phillips, for their valuable services to the Society during their respective terms of office."

Mr. Alban Doran, in moving the resolution, spoke in highest terms of Dr. Duncan's energy and tact as Secretary, and as he knew well how heavy were the duties of the appointment *quorum pars olim fui*, he showed that all the more credit must be awarded to Dr. Duncan for having continued to bring forward specimens during his term of office, and to join in the discussions, though hampered by official duties. Dr. Phillips had actively furthered the interests of the Society in looking after the Library, which now proved a valuable collection of works on obstetrics and diseases of women.

Judicious selection of new books was very necessary as the Library grew larger. Dr. Phillips had taken great pains about recent publications offered for purchase, *concretam exemit labem purumque reliquit.*

Dr. HERBERT SPENCER had much pleasure in seconding the vote of thanks proposed by Mr. Doran. The Society was much indebted to the retiring Librarian and Secretary, who had provided it with so many interesting specimens in bottles and in books.

MARCH 4TH, 1896.

F. H. CHAMPNEYS, M.A., M.D., President, in the Chair.

Present—49 Fellows and 6 visitors.

Dr. Braxton Hicks presented a book to the Library.

Ernest William Cross, L.R.C.P. (Robertsbridge), was declared admitted.

The following gentlemen were elected Fellows of the Society :—T. Hillier Chittenden, L.R.C.P.Lond. ; George Herbert Hopkins, F.R.C.S.Eng. (Swansea) ; Ernest W. Groves, L.R.C.P.Lond.

The following gentlemen were proposed for election :—Sidney Edward Barrett, B.A., M.B., B.C.Cantab. ; Arthur Corrie Keep, M.D., C.M.Edin.

Report on Dr. Lewers' Specimen which was shown as a Tubal Mole on March 6th, 1895.*

THE specimen, somewhat disfigured by long immersion in alcohol, consists of the greater part of a Fallopian tube, the mesosalpinx, and the ovary. The isthmus and infundibulum are considerably distended by a firm, dark clot, strongly adherent to the tubal walls. The fimbriæ seemed to lie flat on the surface of the end of the tube ; the ostium admits a probe for a quarter of an inch. The specimen shows no evidence of hæmorrhage from the ostium. The ovary, of normal size, contains a large recent corpus luteum, completely decolourised by spirit. The specimen is a true tubal mole.

* 'Obst. Trans.,' vol. xxxvi, p. 78.

Report on a Section of the above.

The section shows a large organised clot closely adherent to the submucous tissue of the tube. This clot contains several chorionic villi, some bearing a perfect border of *trophoblast.**

J. Bland Sutton.
Alban Doran.
Arthur H. N. Lewers.

Report on Dr. A. L. Galabin's Specimen of Extra-uterine Gestation.

The specimen consists of the uterus and its appendages, with the bladder, rectum, and a gestation sac placed between the uterus and rectum.

The *uterus* measures 3 inches in length, and its walls at their thickest part are $\frac{5}{8}$ inch in diameter. The uterine cavity displays no detached decidua, but in its lining membrane decidual structures were detected on microscopical examination.

The *left appendages* are normal. The ovary is small, and on section a pale oval body is seen in its outer half, measuring $\frac{3}{8}$ inch in long diameter. The centre of this body is marked by several minute pits, but in its general appearance the nodule resembles a corpus luteum.

The *right Fallopian tube and ovary*, which had been removed by operation, are now restored to their appropriate situations. The tube is normal, its ostium is patent and not dilated, and when fresh a bristle was easily passed along it as far as the uterine end. A small hydatid of Morgagni was seen at the operation, but has now disappeared. The mesosalpinx is normal. What appears to

* Mr. Sutton signs the report conditionally on the word "trophoblast" being replaced by the word "epithelium."

be the *right ovary* contains one or two small cysts; of these the largest was laid open by division of the pedicle at the operation. It contains no corpus luteum.

The *gestation sac* is placed between the uterus and rectum, and occupies the whole of the pouch of Douglas. Its wall, which is thin and tough (a part only has been preserved), was in the recent state closely adherent to the peritoneum of Douglas's pouch, to the rectum behind, and to the back of the uterus and both broad ligaments in front. It extended up the back of the uterus to within an inch of its fundus. The outer surface of the wall of this sac, where it has been artificially detached from the pelvic peritoneum, is smooth and somewhat polished, resembling peritoneum. The inner surface of this sac is rough from adherent blood-clot.

Microscopical examination of the sac wall revealed interlacing bundles of spindle-celled tissue, having many of the characters of unstriped muscle-fibres. The spindle-celled tissue is covered with loose cellular tissue, and a uniform membrane like peritoneum.

The sac contained a loose fœtus and much blood-clot.

The *fœtus* measures 2¼ inches in length after immersion in spirit, and in its development corresponds with that of the tenth week of normal intra-uterine gestation.

At the lowest part of the gestation sac, to the right of the cervix uteri, and near the right utero-sacral ligament, is a circular pit, 1 inch in diameter and ½ inch deep. Its surface is ragged from adherent blood-clot, like the interior of the gestation sac of which it forms a part. This pit appears to represent the placental site. We are of opinion that—

1. The preparation is *not* the result of a tubal gestation ending in rupture, either into the peritoneal cavity or the broad ligament.

2. If an example of tubal abortion, the abortion must have occurred at a very early stage of gestation, and the ovum must have been completely transplanted to the bottom of the pouch of Douglas, and continued its deve-

lopment in that situation. Further, it is necessary to assume that the Fallopian tube under these circumstances must have resumed its normal condition.

3. It is possibly a primary ovarian pregnancy, the sac of which has burrowed between the layers of the broad ligament, leading to distension and growth of a limited portion of the pelvic peritoneum. In favour of this view is the histological structure of the wall of the gestation sac; while against it is the fact that a space of fully three quarters of an inch of normal broad ligament exists between the right ovary and the previously described pit which appears to represent the placental site.

4. It is more probably an example of primary abdominal (intra-peritoneal) gestation.

AMAND ROUTH.
ALBAN DORAN.
ALFRED L. GALABIN.
T. W. EDEN.

Dr. GALABIN thought that the report of the committee raised one point which observers of any similar case in future should pay regard to, namely, whether it might not be that, in primary abdominal fœtation, a membrane might be found corresponding to the decidua reflexa. At the necropsy of his case Dr. Perry thought that the fœtation was subperitoneal, and he had been at first of the same opinion, on account of the character of the sac wall, having a smooth external surface like peritoneum, and being apparently a definite, fully organised membrane. He still felt sure that it could not be merely an exudation of lymph, especially as there were no intestinal adhesions. But, with the rest of the committee, he had become convinced that, while the ovum had certainly not got into the broad ligament by rupture of the tube, it was hardly possible that it could have done so from the ovary. If, however, the fœtal sac was a kind of decidua reflexa formed from the peritoneal surface the difficulty was explained, and one could understand that its histological structure resembled that of the surface of the broad ligament.

Dr. AMAND ROUTH drew attention to the question involved in the report, as to whether it was possible for an ovum after tubal abortion to become secondarily engrafted elsewhere, and continue to grow. Books were silent on the subject, and in the absence of data the sub-committee could not be definite in their conclusions.

EXTRA-UTERINE FŒTATION NOT PRIMARILY TUBAL.

Shown by A. L. Galabin, M.D.

The patient was aged twenty-seven. She had had three children. The last was eleven months old, and she was suckling it up to the time of rupture. In November and December scanty but apparently normal menstruation occurred for the first time since delivery. As it proved, menstruation must have recommenced with the onset of extra-uterine pregnancy.

On January 14th, when she got out of bed in the morning, she was suddenly attacked with severe abdominal pain, and fainted. Pain and collapse gradually increased, and ruptured extra-uterine pregnancy was diagnosed. She was admitted into Guy's Hospital on January 16th, and had then been vomiting everything she took for twenty-four hours, and was suffering intense pain. There was great pallor, and the pulse was feeble, nearly 150; temp. 101°.

Abdominal section was performed the same evening. The peritoneal cavity was found full of clots and blood. As soon as the abdominal tension was taken off the patient became more collapsed, and the pulse could not be felt at the wrist. Saline fluid was injected into a vein during the operation, and strychnine injected subcutaneously. The clots and blood were washed out, and a mass of adherent clot containing placental tissue was removed from a ragged cavity in the posterior part of the right broad ligament at its lower part. The upper part of the broad ligament, including the Fallopian tube, was quickly tied and removed, and a ligature to secure the ovarian artery placed as near as psssible to the pelvic wall. It was then found that free bleeding was still continuing from the interior of the extra-uterine sac, which extended across the back of the uterus and both broad ligaments, and was torn across from side to side. This could only be checked by packing the whole pelvis tightly

with iodoform gauze. The patient rallied for a time, but rather suddenly became collapsed, and died about twelve hours after the operation.

Dr. AMAND ROUTH thought that Dr. Galabin's specimen of supposed ovarian gestation was too valuable to be lightly put aside. He hoped it might be referred to a sub-committee. On a casual inspection the extravasated blood seemed to have formed an adventitious cyst wall in Douglas's pouch, and did not appear to him to be lying, as Dr. Galabin suggested, between the layers of the broad ligament.

Mr. ALBAN DORAN, in some notes on Dr. Arthur Beale's case of fœtus in the peritoneal cavity ('Transactions,' vol. xxxv, 1893, p. 222), indicated numerous sources of fallacy in reports on alleged primary ovarian pregnancy. That condition could hardly be proved to exist until a minute fœtus could be demonstrated lying in a true gestation sac entirely inside the ovary.

Report on a Specimen of Fœtus Diprosopus Anencephalicus.

Shown by Dr. AMAND ROUTH at the Obstetrical Society in May, 1895.

THE specimen was sent to Dr. Routh by Dr. J. F. Williams, of Camberwell, in whose practice it occurred.

Sex, female. Length, 11½ inches. Weight, 1 lb. 11 oz.

External appearance, viewed anteriorly.—The trunk and limbs appear to be normal, except that there is double talipes calcaneus. The monster is a specimen of anterior dichotomy, which is most pronounced in the skeletal system (see later). Superficially it is only apparent in the facial and cranial regions (see Fig. 1). The double face is nearly the width of the shoulders, which are somewhat wider than normal, each face pointing forwards and outwards; the supra-orbital ridges being inclined to one another, in the same horizontal plane, at an angle of 95°. There is no neck; the ears, of which there are only two, being flattened in the angle between head and shoulders. Anteriorly the skin is reflected directly from the two chins on to the chest at about the level of the third rib. The

left face has a single harelip; and the right face a double one, with the præmaxilla adherent to the nose. Situated at the junction of the two faces, about half an

FIG. 1.

inch below the level of a line joining the two inner eyes, is a small dimple, representing an auditory meatus common to the two skulls (compare Fig. 1 with Fig. 3).

Viewed posteriorly.—The vaults of both skulls are absent, the double bases forming in the centre a prominent boss where the two contiguous ex-occipitals coalesce. There is no skin from the supra-orbital ridges anteriorly backwards over the head and along the dorsum of the fœtus to the level of the iliac crests (a condition of spina bifida). The margins of this denuded area correspond above to the margins of the cranial base, and along the dorsum of the trunk to two lines from the posterior borders of the scapulæ to the sacro-iliac synchondroses. This area is about an inch wide; the spinal column

underlying it appears to be double, and is flattened out, owing to the absence of the neural arches. The external genitals are normal, and the anus is perforate.

Dissection: base of the skull.—This is covered with ragged masses of dura mater, altered brain tissue, vessels and nerves. Certain of the cranial nerves are seen entering their respective foramina.

Spinal column.—In the situation of the denuded area above described two membranes, a superficial and a deep, reaching from the base of the skull to the sacrum, were reflected. Between them, and arising from the superficial one, were seen two complete sets of spinal nerves, one set belonging to each spinal column. The outer nerves of each set pierced the deeper membrane to enter their intervertebral foramina, which were one inch apart. The inner nerves of the two sets were one eighth of an inch apart.

Internal organs.—On laying open the abdomen and thorax the diaphragm was found to be perforated on the left side, with a consequent escape into the thoracic cavity of the left lobe of the liver, the spleen, stomach, transverse colon, and pancreas. This diaphragmatic hernia occupied more than half of the thoracic cavity, the heart and both lungs being pushed into a small space on the right side.

The alimentary canal is single in the abdomen and thorax, but the œsophagus is very wide at its commencement, tapering gradually down to the stomach, which is larger than usual, but otherwise normal. There are two mouths, two tongues, with their roots attached as usual to two complete chins; two palates, one of which, the left, is cleft in its soft portion, and partly in the hard. The mouths open posteriorly into one large pharynx, and there is one glottis and one trachea.

Skeletal system.—The extremities do not call for special notice. The skull and trunk were carefully macerated, after which they presented the characteristics shown in the accompanying sketches, Figs. 2—4.

The skull.—In the main the description of the anencephalic skull by two of us in the 'Transactions' for 1895, pp. 219—222, is applicable to each half of the present specimen, of which the two halves are fairly separate. The special points resulting from the dichotomy are as follows.

Upper surface (Fig. 2).—The two skulls are firmly

FIG. 2.

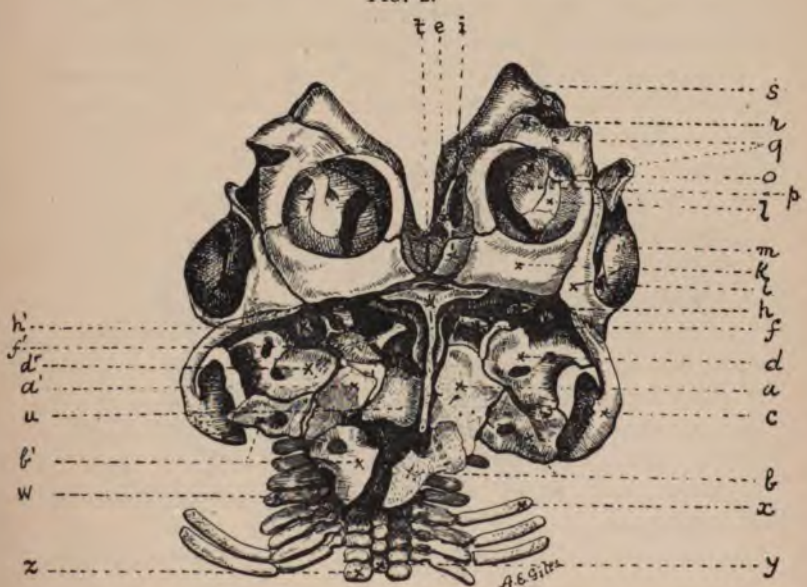

Skull of Fœtus Diprosopus Anencephalicus (upper surface, natural size).

a. Basi-occipital, right skull.
a'. Do. left skull.
b. Exoccipitals, right skull.
b'. Do. left skull.
c. Lower part of squamo-occipital.
d. Petro-mastoid portion of temporal.
d'. Do. do. left.
e. Squamo-zygomatic portion of temporal.
f. Basi-sphenoid.
f'. Do. left.
h. Lesser wing of sphenoid.
h'. Do. left.
i. Greater wing of sphenoid.
k. Orbital plate of frontal.
l. Lateral mass of ethmoid (orbital surface).
m. Malar.
o. Lachrymal.
p. Orbital plate of superior maxilla.
q. Nasal process of superior maxilla.
r. Alveolar process of superior maxilla.
s. Mandible.
t. Fused adjacent squamo-occipitals.
u. Fused mass of adjacent petro-mastoid portions of temporal.
w. Lamina of vertebra of cervical vertebra.
x. Rib.
y. Fused contiguous vertebral laminæ.
z. Double row of vertebral bodies.

N.B.—For convenience of comparison the lettering employed is as far as possible the same as that used in the description of the single anencephalic skull in the report of Drs. A. Routh and Giles, in the 'Transactions' for 1895, pp. 220, 221.

fused by their contiguous lateral surfaces. The adjacent squamo-occipitals form a T-shaped structure in the centre of the upper surface of the bases. The adjacent petro-mastoid portions of the temporal bones form an irregular-shaped mass, somewhat rounded above where it underlies the fused squamo-occipitals. This piece of bone appears also on the under aspect as a quadrilateral mass. The adjacent ex-occipitals are deflected towards the left,

FIG. 3.

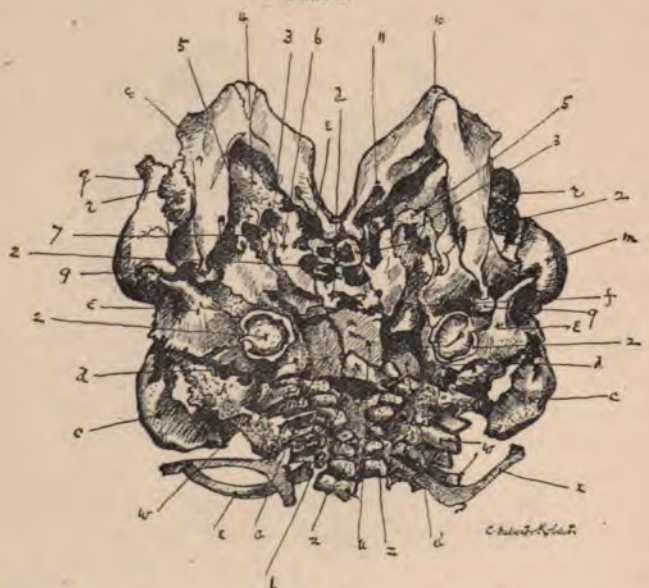

Skull of Fœtus Diprosopus Anencephalicus (under surface, natural size).

a. Basi-occipital, right skull.
a'. Do. left skull.
c. Lower part of squamo-occipital.
d. Petro-mastoid portion of temporal.
e. Squamo-zygomatic portion of temporal.
f. Basi-sphenoid.
m. Malar.
q. Nasal process of superior maxilla.
r. Alveolar process of superior maxilla.
u. Fused mass of adjacent petro-mastoid portions of temporal.
w. Lamina of cervical vertebra.
x. Rib.
z. Double row of vertebral bodies.

1. Lateral mass of atlas.
2. Tympanic membrane and ring with ossicle.
3. Posterior nares.
4. Palatine process of superior maxilla.
5. Palate bone.
6. Sphenoid.
7. Vomer.
8. Alveolar process of inferior maxilla.
9. Glenoid fossa and condyle of inferior maxilla.
10. Symphysis and mental process of inferior maxilla.
11. Inferior dental foramen.

N.B.—The lettering employed above is as far as possible the same as that employed in the description of the single anencephalic skull: Drs. A. Routh and Giles, 'Obstet. Soc. Trans.,' 1895, pp. 220, 221.

causing the right skull to have a wider posterior border than the left.

Under surface (Fig. 3 : letters as in Fig. 2 as far as possible).—The dichotomous condition of the two skulls is well seen, but renders the recognition of the various parts somewhat difficult. The two inferior maxillæ are perfect and distinct, and in the middle line the condyles can be seen in contact. There are two well-formed pairs of glenoid cavities, with moveable joints. Just behind the two inner condyles can be seen the two tympanic rings and auditory meatus of the fused skulls, in close apposition but distinct. The meatus of the right side contains an ossicle. The tympanic rings and membrane (and an ossicle) corresponding to these externally are perfect and well shown. In the middle line further back is seen the somewhat square mass of the fused petro-mastoids (*u*), with a basi-occipital on each side (*a*, *a'*). The other petro-mastoids, right and left (*d d*), are perfect. The doubling of the vertebral column is well seen, and above it a curious mass of bone (1), Fig. 3, corresponding to the right lateral mass of the atlas of the left spinal column. The superior maxillæ and their alveolar processes (*r*), the posterior nares, the palatine processes of the superior maxillæ (4), palate bones (5), and vomers (7) can be made out. The squamo-zygomatic portions of the temporals (*e*) and the lower part of the squamo-occipitals (*c*) are well seen on this surface.

Vertebral column and pelvis (Fig. 4).—The drawing from the macerated specimen show the remarkable doubling of the spinal column, which extends from above downwards as far as the first sacral vertebra. Unfortunately some portions of the specimen have been lost in the process of maceration.

The chief feature is the double row of large vertebral bodies, extending from the skull to the first sacral vertebra on each side ; below the first sacral the spine remains single.

The condition found in the dorsal region is as follows :

FIG. 4.

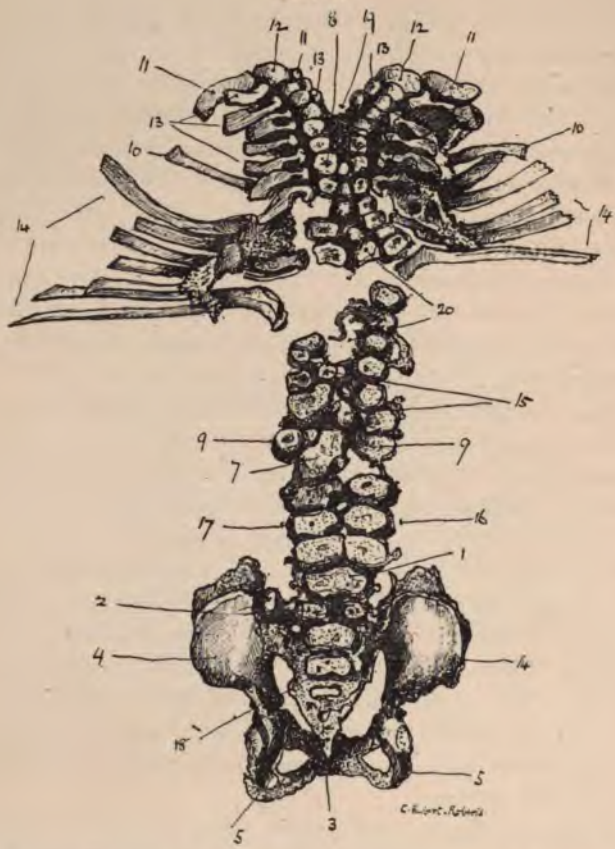

Spinal columns and pelvis of fœtus Diprosopus Anencephalicus after maceration (posterior surface, natural size).

1. Last lumbar vertebra.
2. First sacral and alar process.
3. Coccyx.
4. Ilium.
5. Ischium.
6. Os pubis.
7. First lumbar vertebra.
8. First dorsal vertebra.
9. Last dorsal.
10. First rib.
11. Lamina of axis.
12. Body of axis.
13. Laminæ of cervical vertebræ.
14. Ribs.
15. Laminæ of dorsal vertebræ (fused).
16. Right spinal column.
17. Left spinal column.
18. Sacrum.
19. Division of the two separate spines above.
20. Spaces where fused laminæ have dropped out in maceration.

—In the centre is an irregular row of fused contiguous laminæ; on each side is a row of vertebral bodies; further out on each side is a row corresponding to the external laminæ.

In the cervical region the contiguous laminæ are separate; in the lumbar region most of the contiguous laminæ are absent, whilst the external ones have been lost in maceration.

Above the first dorsal vertebræ the spinal columns diverge like the limbs of a Y, and show the central body with a lamina on each side. These laminæ are imperfect internally, but are well developed externally. In the specimen the atlas and axis resemble the other cervical vertebræ.

The *ribs* that remain are practically normal, but are distorted as to their real position.

The *pelvis* is perfect, and does not seem in any way to depart from the normal in size or development.

W. R. Dakin.
C. Hubert Roberts.
Arthur E. Giles.
Amand Routh, *Convener.*

FIBROID TUMOUR AND CANCER OF THE UTERUS.

Shown by Dr. Amand Routh.

The woman from whom the specimen was taken, aged 52, was married, and had ceased to menstruate for two years, but had during the previous three months been losing blood and an offensive watery discharge. The physical signs pointed to an ordinary fibroid uterus with multiple nodules, but as it was clear that some other intra-uterine condition had recently developed, the cervix was rapidly dilated, after a glycerine

vaginal tampon had been inserted; and the whole endometrium was found to be the seat of a malignant growth, which the microscope showed was alveolar carcinoma.

The following week (January 6th, 1896) the uterus was removed, but with great difficulty owing to its large size (weighing 15 ounces), and to the small nulliparous vagina, which had to be freely stretched and incised.

The woman made a good recovery.

INDEPENDENT CANCER OF THE BODY AND OF THE CERVIX UTERI.

Shown by Dr. Amand Routh.

In the case from which this specimen was removed, a large fungating mass of epithelioma was found to be growing from the posterior lip of the cervix. The woman was aged 56, and had borne nine children. She had ceased to menstruate six years, but for eight months had been losing blood, and had an offensive discharge.

Previous to operation the epitheliomatous mass was gouged away from the cervix, and the uterus then removed without difficulty on February 3rd, 1896.

After removal, the body of the uterus was laid open, and it is seen—and this has been confirmed by the microscope—that there was also cancer of the lining membrane of the body. Dr. A. Routh pointed out that if he had been content to perform only the operation of supravaginal amputation of the cervix in this case, the woman would have been no better, for the cancer of the body would have speedily declared itself, and would probably have been thought to be a recurrence in the stump. The intervening tissue seemed to be perfectly healthy, at all events to the naked eye; so that on inspection of the

stump the operator could not have become aware of the growth in the body also.

The case, therefore, seemed to show the advisability of doing complete vaginal hysterectomy in cancer of the cervix, especially as the risk to life appeared to him to be no greater than after the partial operation.

The woman made a good recovery.

OVARIAN TUMOUR CONTAINING CORPUS LUTEUM.

Shown by Dr. Galabin.

Dr. Galabin showed tumours of both ovaries, removed at the fourth month of pregnancy. The right tumour was a dermoid cyst containing gruel-like fluid, which solidified on cooling. It contained also hair, loose teeth, and bone. The left tumour was an ordinary cystic adenoma, except that three small cysts in it were evidently dermoid, containing fluid similar to that in the right ovary. In the left tumour was seen a large corpus luteum of pregnancy, and near it a small fragment of unaltered ovary. The patient made a good recovery. There was no threatening of abortion, and none of the metrostaxis which almost always follows removal of both ovaries apart from pregnancy. This was sometimes attributed to the effect on the circulation produced by tying the vessels. Dr. Galabin thought that it was rather analogous to menstruation, and that removal of a follicle preparing for menstruation produced the same effect as rupture or maturation of the follicle. If this were so, the flow would naturally not occur in pregnancy when no follicles were being developed.

UTERINE FIBROID ASSOCIATED WITH CARCINOMA.

Shown by Dr. Galabin.

Dr. Galabin showed a specimen of fibroid tumour of the uterus, complicated by carcinoma limited to a part of the intra-uterine surface of the fibroids. The uterus was removed by Baer's operation, and the patient made a good recovery. The patient was aged 44, and had a fibroid tumour for years, causing menorrhagia. In October, 1894, the menorrhagia had been converted for three months into metrorrhagia. Dr. Galabin on this account performed oöphorectomy. The tumour was about the size of five months' pregnancy, and partially invaded the left broad ligament. For six months the patient was apparently cured, and no menstruation nor hæmorrhage occurred. Then metrorrhagia recommenced, but the patient did not come again for advice till November, 1895. Dr. Galabin then decided to remove the uterus. First he dilated the cervix, and passed in the finger, to decide whether there was any cancer, but only smooth fibroids could be reached. Baer's operation was therefore chosen. Very dense intestinal adhesions had to be dissected off about the site of the left pedicle, and in the midst of these was found the ligature, surrounded by a little caseous material. After the uterus was removed the cancer was discovered. As the patient was already somewhat collapsed by a long operation, and as a margin of 2½ inches was found to exist between the lower edge of the cancer and the cut section, it was decided not to remove the cervix. Dr. Galabin thought that the cancer probably existed at the time of the first operation. It was to be noted that exploration through the cervix failed to reveal it even at the time of the second operation. In future, in any case of fibroid tumour where metrorrhagia was a symptom, he should choose hysterectomy in preference to oöphorectomy.

HYDRONEPHROSIS OF THE LEFT KIDNEY.

By Mr. J. Sidney Turner.

Mr. J. Sidney Turner exhibited a specimen of hydronephrosis of the left kidney, which he had removed fourteen days before. He also showed the other kidney, which was abnormally large, and had two distinct ureters.

Mr. Sidney Turner said that some apology was necessary to the Society for bringing this case before it, as, strictly speaking, it hardly came within the domain of obstetric surgery; but as the operation had been performed under the diagnosis of ovarian tumour, it became of interest to members of this Society. The case was instructive from three points of view, viz. the diagnostic; the operative; and the result, which unfortunately in this case was completed by the post-mortem.

The patient was a widow aged fifty-eight with one child, of bad physique, having very bad lateral curvature of the spine. She came under his notice on February 1st last, having sustained a severe fall which caused injury to the hip-joint. In examining the patient a large, soft, fluctuating rounded tumour about the size of a man's head was found in the left inguinal and hypogastric regions, extending downwards to Poupart's ligament, and just beyond the median line. It had every characteristic of an unilocular ovarian cyst, except that a coil of intestine was felt in front of it. This, though not unknown in the case of ovarian tumour, is far more usual in hydronephrosis, and should perhaps have arrested more attention. There was, however, distinct resonance in the left lumbar region, and the tumour could be felt, but with some difficulty, *per vaginam*. There was no history of any pain nor of any accumulated quantities of water being passed at any time. When the abdomen was opened the tumour was found to

have no attachment to the pelvic organs, and was recognised to be a cyst of the left kidney, with the ureter undilated and not containing any calculus. It had pushed the peritoneum with the descending colon downwards and forwards, so that the colon lay across from left to right. The peritoneum over it was exceedingly vascular, and so, instead of trying to dissect off the adherent bowel, and having numerous vessels to tie, and recognising the fact that there had been no pain nor peritonitis, the peritoneum was carefully opened between the courses of the vessels and then separated from the cyst, which was tapped and three pints of urine drawn off; it was then enucleated and freed up to the renal artery, which was tied, and the cyst was removed after the ureter had been also tied. In this way no hæmorrhage was incurred, and not more than one ounce of blood was lost during the whole operation, which lasted one hour and three quarters. The progress of the case was apparently all that could be wished. There was no rise of temperature, the patient passing water and the bowels acting easily; no opium or any other drug being administered, as there was no pain; the wound healing perfectly in seven days. The urine was necessarily scanty for the first twenty-four hours, as only a small amount of liquid was given, but it increased day by day from 15 ounces to 44 ounces; it was of normal specific gravity and free from albumen.

On the fourteenth day after the operation, when in the act of passing water, faintness suddenly supervened, and in about four or five minutes death occurred, in spite of the hypodermic injection of ether which was given. The patient had never sat up, although she was to have been allowed to do so on this very day. The post-mortem examination revealed more negative than positive results. There were no clots in the pulmonary artery, no lesions in the brain substance nor its ventricles, no peritonitis nor intestinal mischief (the cæcum was, however, very distended by flatus); there was no fluid in the peritoneum, which was quite healed. The peri-

cardium contained a small amount of fluid, but there were no adhesions; the aortic valves were slightly atheromatous, as is often the case in persons of the same age; the right lung was pushed over by the curved spine, and was very adherent from old pleurisy. The most interesting organ was the other kidney, which was twice the normal size, and had two distinct ureters, which on first leaving the kidney were about 1½ inches apart, came together lower down, but never united till the bladder was reached. The probable explanation of the cystic state of the left kidney was that originally it had been a floating kidney, and the ureter had become twisted. Indeed, the ureter was found in this twisted condition, and a probe was passed down it with considerable difficulty. This case illustrates once more the principle which has often been laid down by this Society, that when a surgeon undertakes a laparotomy he must be prepared to do almost anything in the way of abdominal surgery.

Dr. Galton thought that an important practical lesson was taught by the mode in which the adhesions had been dealt with in this case. The adhesions to intestines were numerous and extensive; but by dissecting off the peritoneum from the outside of the sac they were separated without the use of a single ligature, and without hæmorrhage. He did not see why the adhesions of intestine to ovarian tumours should not be treated in the same way.

Dr. Heywood Smith said he had had experience, in a case between twenty and thirty years ago, not wholly unlike that of Dr. Turner's. A young woman consulted him for a large abdominal swelling, which, appearing to be renal, Mr. Thornton advised tapping with the view of examining the contents. He drew off with an aspirator only six ounces of fluid one afternoon, and the patient died in a few hours. At the necropsy both kidneys were found enormously distended with an irregular calculus filling the pelvis of each.

DEFORMED FŒTUS WITH CYSTIC TUMOUR OF NECK.

By A. H. N. Lewers, M.D.

The fœtus was sent to Dr. Lewers by Dr. Currie of Finsbury Park. The mother was a rickety woman, 36 years old, and had had three previous confinements, labour coming on at the eighth month. The first two children are living; the third lived six months. In this, the fourth pregnancy, labour came on at term. Dr. Currie found she had a flattened pelvis, with a conjugata vera of about three inches. He perforated, and completed delivery with the craniotomy forceps, but with very great difficulty, owing, as appeared afterwards, in great part at all events, to the presence of a peculiar tumour of the neck. The mother's brother, a rickety man, is married to a healthy woman, and they have had two deformed children, but particulars as to the deformity cannot be obtained. (The specimen was referred to a committee consisting of Mr. Targett, Mr. Doran, and Dr. Lewers.)

CHORIONIC VILLI FROM A TUBAL MOLE REMOVED BY ABDOMINAL SECTION.

By A. H. N. Lewers, M.D.

This is a section from the tubal mole, on which a report by the committee appointed to examine it was read at the meeting (see p. 87).

ADJOURNED DISCUSSION ON ABDOMINAL HYSTERECTOMY WITH INTRA-PERITONEAL TREATMENT OF THE STUMP. WITH NOTES OF EIGHT CASES.

By Harrison Cripps, F.R.C.S.,

ASSISTANT SURGEON TO ST. BARTHOLOMEW'S HOSPITAL, AND OPERATOR FOR THE ABDOMINAL SECTIONS IN THE WOMEN'S WARD.

Dr. Cullingworth said that the operation which formed the subject of Mr. Cripps's paper being one of which he had had some personal experience, he would venture to offer a few remarks. Mr. Cripps's paper reflected the change which was gradually being effected in the attitude of the profession towards operations for myoma of the uterus. There could be no doubt that these operations were becoming more frequent. This was partly to be accounted for by the diminution of the mortality from the operation, consequent upon antiseptic methods and an improved technique. The risk of the operation being lessened, it was justifiable to advise surgical interference in cases in which, had the risk been what it used to be, it would not have been justifiable. But the change was also in some measure due to an advance in our knowledge of the natural history of uterine myomata, and to the more general recognition of the fact that these tumours are often a source of much misery, and not unfrequently a serious menace to the patient's health and even to her life. In the light of the evidence that was gradually being accumulated as to the very considerable proportion of cases in which these tumours continued to grow after the menopause, we were no longer able, without much reservation, to offer such mild comfort to our patients as could be obtained from the prophecy that their troubles would cease at the menopause. The cases on record were now numerous in which, so far from the tumours ceasing to be a source of trouble and inconvenience at that epoch, dangerous complications, such as extensive œdema, malignant change, and even gangrene, have set in some years later, with consequences fatal to the patient. All these considerations had made it impossible for us to speak to our patients as lightly and hopefully as we formerly felt justified in doing, and had contributed to make us more ready to advise surgical interference than we used to be. We no longer felt it incumbent upon us to invariably wait until dangerous symptoms had actually supervened. Under certain circumstances, and when other means had been tried and had failed

we anticipated the advent of dangerous complications by advising timely operation, before the health had become so seriously undermined as to give surgical intervention but little chance of success.

He was afraid he could not enter upon a critical examination of the details of Mr. Cripps's cases, as he had not the full text of the paper before him, and could not trust his memory sufficiently. He would therefore base his remarks on the abstract. He knew, from disagreeable experience, how very easy it was to come away from the perusal of an abstract with erroneous impressions. He hoped Mr. Cripps would correct him if he fell into any errors of that kind.

The abstract opened with an enumeration of the conditions that call for surgical interference in the case of uterine myomata. He did not suppose the author intended the list to be exhaustive, but there were one or two other conditions of such importance as to deserve mention in any list of the kind. For example, surgical interference was called for (1) when it became evident that degenerative cystic or other changes were taking place, (2) when the rate of growth had begun suddenly to increase, and (3) when, after the menopause, the tumours were obviously increasing in size.

The author contrasted the extra-peritoneal with what he termed the intra-peritoneal method of treatment of the pedicle. As a matter of strict accuracy, the latter method was not intra-peritoneal. The pedicle was not left in the peritoneal cavity in the sense that the pedicle of an ovariotomy was so left. It was really left beneath, and not within the peritoneum. This, however, was a point of little importance. The term had been frequently used, and was therefore in little danger of being misunderstood. He entirely agreed with the author in preferring the so-called intra-peritoneal method to the extra-peritoneal. Every one who had practised the extra-peritoneal method must have felt more or less dissatisfied with it. For his own part, he had always regarded it as a clumsy and unsurgical proceeding, that was sure to be replaced sooner or later by some method that would permit closure of the abdominal wound. Until some method was discovered of securing the patient against the risks of hæmorrhage from the stump, the extra-peritoneal was undoubtedly the only safe method to employ. But from the moment that it was suggested to tie the uterine arteries as a preliminary step of the operation, the abandoment of the extra-peritoneal method became merely a question of time. Already that method had been practically superseded. It was now only practised by operators who had become accustomed to it, and who very naturally and properly hesitated to relinquish a method that had given them good results. The rivalry at present was not between the extra-

peritoneal and intra-peritoneal methods of dealing with the pedicle, but between the method of leaving the cervix, and that of removing the entire uterus. In the most recent discussions a third rival had entered the field, namely, operation through the vagina with morcellement of the tumour when it was too large to be removed entire. He (Dr. Cullingworth) had performed the operation of abdominal hysterectomy in forty cases, in nine employing the extra-peritoneal method of dealing with the pedicle, and in thirty-one the so-called intra-peritoneal method, the cervix being left in all the cases. Since he had first adopted the intra-peritoneal method, now two years and a half ago, he had not once returned to the older plan of treatment. He thought that, as a matter of fairness, he ought to state that his mortality had been higher since he changed his method. But that increase in the mortality was not the fault of the method. It was due to exceptional complications that he believed would have influenced the result just the same whatever method had been adopted; such, for example, as a gangrenous condition of the tumour, which he had met with in no fewer than three cases out of the forty. When the cases did well, there was a very striking contrast between the comfort of the convalescence after the one method, and the discomfort after the other. A patient whose abdominal wound had been closed, and in whom there was no strain on the pedicle, was in a very different position, mentally and bodily, from one in whom the stump was left outside, to undergo necrosis and gradual separation. The formidable array of pins and serre-nœud, the necessity of daily interference, and the vague dread of what might happen when the dead tissue was finally removed, kept a nervous patient in a state of continual apprehension during just those first few days, when absolute repose of mind and body was of so much importance. Of course the question of mortality was of more importance than the question of comfort; but if, as he firmly believed to be the case, the dangers attending the intra-peritoneal method were not greater than those attending the other method, the minor question of the patient's comfort during her convalescence was not one to be altogether overlooked. The typical convalescence of a hysterectomy patient, treated by the intra-peritoneal method, was as painless and uneventful as a normal puerperium.

He had not been able to follow the precise details of the author's method of securing the vessels in the broad ligament. His own method was to tear a hole in the broad ligament by first perforating it with a blunt pedicle-needle, and then expanding the opening by means of a pair of small pressure-forceps. A slit-like opening was thus made without injury to the vessels. At each extremity of the slit a silk ligature was passed and tied, the one over the free upper border of the broad

ligament, the other over the infundibulo-pelvic ligament. This latter secured the ovarian artery. The inner one prevented bleeding during the operation from the vessels on the uterine side of the broad ligament, and took the place of the inconvenient clamp-forceps. The tissues between these two ligatures having been divided, the upper part of the tumour was set free. The next step was to tie the uterine artery on each side. He felt for the pulsating vessel just as it reached the side of the uterus, and as near as possible to the level of the os internum, and secured it in its continuity. He believed with Mr. Greig Smith that the ligature was less likely to slip if, instead of dissecting out the vessel, the surrounding tissues were included in the ligature. He therefore passed a needle (with fixed handle) through the peritoneum, beneath the vessel, and back again through the peritoneum on the other side of the vessel. Sometimes the ligature passed through both the peritoneal layers of the broad ligament. As the securing of the uterine arteries was the most important step of the operation, he not unfrequently passed a double ligature, and adopted the "stay-knot" suggested by Ballance and Edmunds. The rest of the operation was now performed with little or no bleeding, and without any of that obscuration of the field of operation which bleeding vessels always entail.

With regard to the mode in which infection had taken place in the author's fatal case, he thought the author had expressed himself more absolutely than the facts warranted. The statement in the last two lines of the abstract ran thus:—"There was one death from sepsis, due to infection from the vagina." He thought it would have been well to state this rather as an opinion than a fact. He was disposed to agree with a remark he had recentlyheard made by the President, that the vagina was blamed as a channel of infection somewhat too readily. The experiences of vaginal hysterectomy tended largely to absolve the vagina from the imputation under which it had rested in regard to this matter of infection. There were other points in the paper that invited criticism, amongst others the reference to the operation of oöphorectomy. He had, however, already occupied so much of the time of the meeting that he would simply ask to be allowed, in conclusion, to read a short extract from a paper in which he had given an account of all his cases of oöphorectomy ('St. Thomas's Hospital Reports,' vol. xxii). The cases were twenty in number, and the conclusions at which he had arrived with regard to the operation were—

"(1) That it affords an almost certain means of relieving all the more dangerous symptoms in cases in which active treatment is necessary, and in which removal of the tumour or tumours is either impracticable or likely to be attended with special difficulty or grave risk.

"(2) That it is unsuitable in cases where the tumours have attained a very large size, or have become œdematous, or have undergone cystic or other degenerative change.

"(3) That it is peculiarly applicable to those cases in which the tumours are for the most part intra-pelvic, and in which operative interference is required for the relief or prevention of dangerous pressure symptoms.

"(4) That its field of usefulness is likely to become curtailed in proportion as the technique of abdominal hysterectomy improves, and the mortality of the latter operation diminishes.

"(5) That although, in experienced hands, its mortality is not high, it should never be regarded or spoken of as a slight or minor operation.

"(6) That it is impossible to know beforehand whether it will be an easy or a difficult, or even a practicable operation.

"(7) That the relief is not generally so prompt or convalescence so free from interruption as in an ordinary case of ovariotomy, or even of abdominal hysterectomy.

"(8) That before being submitted to the operation a patient should, in the interests both of herself and the operator, be made fully aware of the uncertainties that specially attend it."

Dr. Galabin said that he agreed with Mr. Cripps and Dr. Cullingworth in preferring the intra-pelvic treatment of the pedicle. He should lay more stress than Mr. Cripps had done on the superiority and rapidity of the convalescence in patients so treated. Mr. Cripps had said that there was less risk of sepsis with the extra-peritoneal supra-pubic treatment of the pedicle. Even if this were true as regards fatal sepsis, sloughing of the pedicle, which reached somewhat below the plane of constriction, was an essential part of that method; and he thought that this often caused a partial septic absorption with constitutional disturbance.

His own experience of the intra-pelvic method was limited to a very few months, since which time, stimulated by the example of Dr. Cullingworth, he had adopted Baer's method of operating. He understood this to be essentially the same which Mr. Cripps had followed. He considered its novelty and advantage to lie in the avoidance of any ligatures or sutures placed in myomatous or uterine tissue. He had operated in this way in six cases of large fibroid tumour. In one case of fibroid tumour he had performed parhysterectomy, removing also the cervix, and bringing down all ligatures through the vagina. This case was complicated by extensive adhesions and pyosalpinx, and a large mass of the fibroid had to be enucleated out of pelvic cellular tissue under the pouch of Douglas. He had treated in the same way two cases of cancer of the fundus, too large to remove through the vagina. So far he had been fortunate enough not to lose a patient by either method. But in the case of a small

fibroid, not much larger than the uterus at four months' pregnancy, he still chose oöphorectomy by preference.

He did not understand whether Mr. Cripps turned his sutures into the pouch formed by sewing together the peritoneum, or left them intra-peritoneal. Dr. Galabin adopted the latter plan, leaving no ligature or suture in the pouch. To isolate the pouch from the peritoneal cavity as completely as possible, he used a continuous suture of chromicised gut, piercing the peritoneum twice on one side, once on the other, so as to make a sero-fibrous union, as advised by Mr. Greig Smith. He had not interfered with the cervical canal, unless there was reason to think that the interior of the uterus was septic. In that case he dilated beforehand, and washed out the cavity with mercury solution. In several of his cases a considerable amount of sanguineous drainage came away through the vagina.

With his first ligature on the broad ligament he secured the ovarian vessels by a mass ligature. Before placing the second mass ligature, to secure the uterine artery, he made the anterior division of the peritoneum across the fibroid, and stripped down the bladder, thinking that in this way the uterine artery could be secured at a lower point than by the method followed by Dr. Cullingworth.

Dr. Peter Horrocks looked upon abdominal hysterectomy with extra-peritoneal treatment of the stump as a barbarous operation; and he considered that if the intra-peritoneal method could be perfected, it was greatly to be preferred. He agreed with nearly all that Dr. Cullingworth had said; but he would like to ask how many years the thirty or forty operations mentioned by him had been spread over, because he thought it unfair to compare operations performed during the last year or two with those performed earlier when asepsis was not so certainly secured. At the present time, by means of sterilisation of instruments and sponges, real or artificial, and by improved methods generally, one could almost guarantee asepsis. Hence the question of operation or no operation took on a different aspect, and in cases in which one might have recommended no operation, one could not only recommend it, but even urge it when the patient's condition demanded it. He had performed abdominal hysterectomy for fibroids by Baer's method four times, with one death. The three recoveries were all that could be desired in freedom from pain, absence of pyrexia, and speed of convalescence. The fatal case was in great part, if not entirely, due to the complication of renal disease. He had generally dissected out a portion of the cervical mucous membrane, namely, that part near the raw surface of the stump. He thought it desirable to have free drainage into the vagina, and he very much doubted whether the secretion in the cervix uteri or in the vagina possessed

pathogenic qualities except in disease. Hence he questioned the correctness of the opinion of Mr. Cripps in regard to his explanation of death in the fatal case recorded.

Again, he did not think that drainage of the pelvic cavity by means of a tube passed through the abdominal wound would be an improvement, because the small quantity of serum exuded from the seat of operation could be easily absorbed, and its withdrawal through a tube could hardly be expected to make any difference as to the result of the operation.

Mr. MEREDITH expressed his dissent from the views of previous speakers as to the grave risks of septic infection entailed by the extra-peritoneal method of treatment. His own experience of this treatment, founded upon nearly one hundred cases, was entirely opposed to their statements, no instance of septic infection from the uterine stump *after* the removal of the serre-nœud and pin having occurred in his practice. Mr. Cripps, in his abstract, had referred to obstruction of intestine or ureters as dangers entailed by the use of the serre-nœud; but the speaker saw no reason why either of these accidents should result from a skilfully performed operation. Regarding the question of a presumed analogy between the state of things left after a vaginal hysterectomy, and that entailed by the so-called intra-peritoneal treatment of a uterine stump, Mr. Meredith considered such analogy faulty, inasmuch as in the former instance the cervix as a possible source of infection is non-existent, the cellular tissue of the broad ligament is in great measure protected by the ligatures, and there is every facility for free pelvic drainage; while in the latter case the cervix remains *in situ*, with its stump covered in by flaps of peritoneum enclosing a potential cavity, whence there is no means of escape for effused serum or blood excepting through the cervical canal —a state of things most favourable for the development and extension of sepsis, especially if the adjoining broad ligaments have been opened up. While fully prepared to recognise the advantages of a perfected method of intra-peritoneal treatment of the uterine stump, he should certainly for the present continue to use the serre-nœud—at all events until the procedure advocated in Mr. Cripps's paper can be shown to afford as good results as are now attainable in competent hands by the extra-peritoneal treatment of the stump.

The PRESIDENT said that, as regards the indications for operations on fibroids, it must be remembered that nothing was commoner than the presence of a fibroid growth of great or little size in a woman who was or felt that she was quite well. So that on one side it must be admitted that the majority of cases need no treatment at all, still less a dangerous operation; and we must also remember that we have to face an operation of exceptional danger.

The number of cases in which operation is justifiable or desirable must, generally speaking, be regulated by the ascertained risks of the tumour against the ascertained risks of the operation; the former must exceed the latter before operation can be justified. As regards the risk of the tumour, some remarks had been made to the effect that they are greater than has been supposed. As regards the risks of the operation, he did not think we knew at present the results of intra-peritoneal methods, so that there was no firm basis of comparison. He thought, however, that the time was far distant when the mortality would be so low that the operation of all fibroid tumours became justifiable. As regarded the mode of operation, he had been struck with the great danger of sepsis. He knew that this would occur after the enucleation of a fibroid in the hands of careful surgeons, in whose practice sepsis after ordinary abdominal operations was almost unknown. The cause was not plain. The vagina had been blamed. But he was inclined to regard the vagina as a much-maligned tube, and not nearly as dangerously unclean as was commonly supposed. Were it otherwise, how could the almost uniformly calm course after vaginal hysterectomy be accounted for? Here there was a free communication between the vaginal and peritoneal cavities; there was also a large raw surface (he did not agree with Mr. Meredith that this was enclosed), and there was a foul discharge after the first day or two; and yet the patients did almost uniformly well. One great difference between the two was, of course, that in abdominal hysterectomy there was no drainage, and in vaginal hysterectomy very free drainage. But he did not think that, even so, the vagina could be regarded as a highly septic canal. As regarded the question of oöphorectomy, he quite agreed that it was generally an unsatisfactory operation for fibroids, and should rarely be practised. It was often not feasible, and its results were uncertain. A polypus was apt still to cause hæmorrhage after it, and so were other conditions of the uterine cavity. Indeed, where a surgical operation became, in his opinion, advisable, he boldly advised hysterectomy, and deprecated oöphorectomy in the great majority of cases, believing that it was better for the patient to run a little extra risk for the sake of getting a really satisfactory result. In this respect he not unfrequently found himself more surgical than the surgeons. The question of intra-peritoneal or extra-peritoneal treatment must be decided for the present on the grounds of relative mortality. If the clamp still gave the best results, it could not be justly described as an obsolete operation. Whenever the two methods showed equally good results, the advantages of the intra-peritoneal method were so obvious that it would finally displace the other. For some cases it might already be the preferable operation, but the choice must be made on the

grounds of safety, for he thought each one of us would prefer to have his life saved by a "barbarous proceeding" to being killed by the most advanced "surgical triumph."

Mr. Harrison Cripps, in reply, said that he entirely agreed with the President that a large proportion of fibroid tumours never gave any trouble, nor increased to an inconvenient size; and that it was not right, unless some serious symptoms were being produced, to expose the patient to the risk which a hysterectomy necessarily entails. He could not, therefore, quite agree with Dr. Cullingworth as to the advisability of operating on fibroids whilst they were still small, to avoid the more serious operation when they had grown bigger. He thought it better that the patient should take her chance, and only be operated on when necessity arose. In answer to other speakers as to the ligaturing of the broad ligaments, he quite agreed that these could be completely transfixed and tied in those cases where the ligaments were well defined and not separated; but when a large tumour had to be dealt with, which had spread within the layers of the broad ligament widely separating them, it was quite impracticable to tie them by transfixion, and the vessels could only be secured by clamping and tying successive portions of the broad ligament, and the uterine arteries especially would have to be tied separately between the layers, and not by transfixing and including them with the peritoneal layers. In answer to Mr. Meredith he (Mr. Cripps) did not state any dogmatic opinion as to the advantage of the intra- over the extra-peritoneal method of treating the stump. He merely stated that up to the time his paper was written it had given in his hands rather better results, but that he was not satisfied that it had diminished the risk of sepsis; and he further congratulated Mr. Meredith on the great success that had attended his treatment of the stump by bringing it out at the abdominal wound. Of the eight cases which he had recorded in his paper, one had terminated fatally, and this he believed from a small septic clot between the surface of the stump and the peritoneal flaps. Mr. Harrison Cripps, in answer to further questions, gave his reasons as to why he formed the opinion that the infection in this case came through the vagina. He also stated that though drainage was used in none of the eight cases, he now intended to employ it for a few days after the operation. In conclusion he thanked the various speakers for their criticism, which showed there was still much to be done before the best method of treating the pedicle in abdominal hysterectomy could be finally solved.

APRIL 1st, 1896.

F. H. Champneys, M.A., M.D., President, in the Chair.

Present—54 Fellows and 10 visitors.

Books were presented by the American Gynæcological Society, and the staffs of St. Bartholomew's and St. Thomas's Hospital.

Ernest W. Groves, L.R.C.P.Lond., was admitted a Fellow of the Society.

The following gentlemen were elected Fellows of the Society:—Sidney Edward Barrett, B.A., M.B., B.C. Cantab.; and Arthur Corrie Keep, M.D., C.M.Edin.

The following gentlemen were proposed for election:—Louis J. E. Carré, M.D.; Rolf Creasy, L.R.C.P. (Windlesham); J. Lockhart Downes, M.B., C.M.Edin.; Frank Edward Easton, L.R.C.P.Lond.; W. Campbell McDonnell, L.R.C.P.Lond.; A. Lyons, M.B.Lond. (Thames Ditton); and Patrick Fraser McGregor, M.B.

SPECULUM.

Shown by Herbert Spencer, M.D.

Dr. Spencer showed a speculum shaped like a Fergusson's, but with hollow walls silvered inside and

hermetically sealed. As advantages, he claimed for it that it could be rendered aseptic by boiling, or by the strongest antiseptics, the whole of the surface being of glass inside and outside.

SKIAGRAM OF A SIRENIFORM MONSTER.

Shown by Herbert Spencer, M.D.

Dr. Spencer showed a "skiagram" of a sireniform monster (*sympus dipus*), showing the whole osseous system of the fœtus, of special interest being the internal position of the fibulæ, owing to the outward rotation of the limbs, and the bones of the fused feet, which contained only nine digits. Dr. Spencer thought that the new photography was of considerable obstetrical value. It could be used to demonstrate, without dissection, the osseous system of monsters, as in the case exhibited. It would also show in a very clear manner the position and extent of the *caput succedaneum*. Fractures, especially of the clavicles, could be readily demonstrated. Researches on the ossification of the bones of the fœtus could also be carried out in living children by means of the Röntgen rays. For taking the skiagram he was indebted to Mr. Porter, of University College, and to Mr. Hair.

Dr. Spencer's Skiagram of a Sireniform Monster.

SARCOMA OF CERVIX UTERI.

Shown by A. L. Galabin, M.D.

Dr. Galabin showed a specimen of sarcoma of the cervix uteri, with microscopic section, which showed the growth to consist of round cells in rather abundant fibrillated stroma. Clinically the case presented the ordinary appearance of cancer of the cervix. The uterus was somewhat fixed and the growth large, so that it was impossible to get any view by speculum of the posterior vaginal fornix. Vaginal hysterectomy was performed, and it was found necessary to open the peritoneum of the pouch of Douglas by the aid of touch alone. The patient made a good recovery, and was so far free from recurrence (six months after the operation). It was found that the lining mucous membrane of the cervical canal remained healthy, and the growth appeared to have commenced in the muscular wall.

MYXO-SARCOMA OF URETHRA IN A CHILD.

Shown by A. L. Galabin, M.D.

Dr. Galabin showed a specimen of a pedunculated myxo-sarcomatous growth of the urethra from a child aged three, with microscopic section of structure. The patient had been in a medical ward of Guy's Hospital for hæmaturia, the cause of which was not positively ascertained. She was afterwards admitted into the gynæcological ward on account of a mass which began to protrude from the vagina through the hymen. This was found to

spring by a pedicle out of a widely dilated urethra, and it had descended into the vagina behind the hymen, apparently in consequence of the urethral meatus becoming dilated and displaced backwards as it came down. The growth measured about 3 inches in each of its two principal dimensions. Its surface was bright red and lobulated. The growth was removed with the galvanic cautery, and it was then found that the urethra was wide enough to allow the finger to pass into the bladder, and feel its surface to be uneven with growth. After the operation the child was relieved from all symptoms, but no doubt was felt that the growth would run a malignant course. She died rather unexpectedly about a week after leaving the hospital. The section showed the predominant character of the growth to be myxomatous, with round cells interspersed.

MICROSCOPIC SECTIONS OF TISSUE REMOVED FROM THE UTERUS.

Shown by A. L. Galabin, M.D.

Dr. Galabin showed microscopic sections of tissue removed from the uterus six months after a miscarriage at five months, which he thought of interest in reference to the papers of the evening, although he did not regard it as malignant. The patient was aged forty. She had irregular hæmorrhage ever since the miscarriage, which had become continuous for the last three months. The uterus, being dilated, was curetted, and the scoop brought away more tissue than the normal mucous membrane. Microscopic sections showed at one part chorionic villi, with a curious proliferation of the trophoblast, so that it formed a network round the ends of the villi, consisting

of protoplasm containing nuclei, and vacuolated in places. At another part bands of muscular fibre were seen to be infiltrated with a structure containing in some places large cells like decidual cells, in other places consisting of a small-celled fibrillated stroma. He thought that the villi showed evidence of quite recent vitality, and that the probable explanation was that, retaining their vitality, and perhaps penetrating the maternal wall more deeply than usual, they had stimulated the maternal tissue also to continued proliferation. The patient had no return of hæmorrhage, and remained well so far, but only a few weeks had passed since the operation. The tissue removed at the operation did not look like placenta, and was thought, from its naked-eye appearance, to be probably new growth.

RUPTURED TUBE AND THREE WEEKS EMBRYO FROM THE SAC OF AN OLD PELVIC HÆMATOCELE.

Shown by C. J. Cullingworth, M.D.

The specimens consisted of a portion of the left Fallopian tube and an embryo. The former was two inches in length, normal at its cut uterine end, somewhat dilated in its central portion, and constricted so as to be only just pervious at its fimbriated extremity. In the dilated portion was an old laceration, forming a wound an inch long by half an inch wide, and exposing the interior of the tube. The edges of the laceration were more or less regular, everted, and cicatricial. Adhering to the exposed mucous membrame was a quantity of old blood-clot.

The embryo was about five-sixteenths of an inch (one

centimetre) in length, and corresponded in size and appearance to an embryo of about three weeks.

The patient from whom the specimens were removed was a woman aged thirty-four, whose third and last child was born four years ago. In July, 1895, she was taken suddenly ill, with a temperature of 104°, and a large tender swelling in the pelvis and lower part of the abdomen. She was in bed for eight weeks, and was at at one time considered to be in great danger. She had had two similar but slighter attacks since,—one in November, 1895, for which she was in bed four weeks; and one in February, 1896, which kept her in bed a fortnight. She was first seen by Dr. Cullingworth on the 29th February, when the last attack of illness had just subsided. There was then fixation of the uterus, and behind and to the right of it there was a large circumscribed cystic swelling, which Dr. Cullingworth believed to be an inflamed and adherent ovarian cyst. The patient was admitted into hospital with a view to operation, but when again examined the swelling was found to have become somewhat diminished in size. This diminution suggested the possibility of the swelling being due to an encysted collection of serum in the peritoneum, and the operation was postponed. But as no further diminution took place, and the patient was in a good deal of pain and anxious to have relief, the abdomen was opened on March 26th. The swelling proved to be a collection of serum in the sac of an old hæmatocele. The roof of the cavity was formed by adherent omentum and small intestine. From its walls, firm, irregular pieces of old contracted blood-clot projected into the cavity. There was no free blood in the cavity. The right uterine appendages were adherent, but otherwise normal. The left Fallopian tube was as above described. The left ovary was normal. The embryo was found amongst the fragments of old blood-clot adherent to the pelvic wall.

Dr. Cullingworth said that the opportunity of examining the sac of a pelvic hæmatocele some months after its

occurrence, and when almost all the blood had become absorbed, occurred very rarely. He considered himself exceedingly fortunate to have discovered the embryo in this case. The size of the embryo showed that rupture had occurred about the fourth week; hence there had been no missed menstrual period to help to a correct diagnosis. It was interesting to know that the temperature in a case of pelvic hæmatocele from ruptured tubal gestation might rise as high as 104°, and it was also interesting to know that serum might accumulate in the sac of an old hæmatocele to such an extent as to simulate an ovarian cyst.

NOTES OF A CASE OF MALIGNANT DISEASE OF THE UTERUS WITH NUMEROUS DEPOSITS IN THE LUNGS, AND DEATH, FOLLOWING AN ABORTION.

By John D. Malcolm, C.M., F.R.C.S.Edin.,
SURGEON TO THE SAMARITAN FREE HOSPITAL.

REPORT OF POST-MORTEM APPEARANCES BY DR. R. G. HEBB.

The subject of the following notes was twenty-seven years of age at the time of her death, and had been married seven years. She had three children. The first was prematurely born at the seventh month, and died of asthenia. Before the second child was born the patient had three miscarriages in the earlier months of gestation. The second child is alive and well. The third was born in April, 1894, and died of bronchitis at the age of fourteen months. The patient's family history was very good. All her brothers were alive, and her parents and grandparents were also living. She was stout and healthy until July, 1895, when it was remarked by her husband and friends that she began to lose flesh. Dr. Mackintosh, of Mortlake, to whom I am indebted for these notes, also observed this emaciation, and that the patient's complexion acquired a sallow tinge about that time. She was not then under medical treatment. Two months later, on September 28th, 1895, the patient was supposed to miscarry, being, it was believed, about six weeks pregnant at the time. No medical man was called in. She recovered and was getting about again, when the vaginal discharge became offensive. She therefore sent for Dr. Mackintosh, who found that her temperature was 103° F., and her

pulse was very quick. He made her stay in bed, and on October 12th she was put under chloroform, and some brownish débris was removed from the uterus. The cavity of the womb was carefully washed out, and the washing out was repeated daily for a week, after which time the temperature had fallen to normal. The débris removed was not examined by the microscope. After this the patient seemed to be doing well. She was up and looking after her house, but she did not gain flesh or strength. On December 20th she was suddenly seized with severe abdominal pain, and the temperature rose to 104·4° F. Dr. Mackintosh recognised that the patient's condition was serious, and lost no time in sending her into the Samaritan Free Hospital, under my care. She was admitted late at night on December 20th, 1895. She was then obviously very ill. There was severe pain with extreme tenderness and slight distension of the abdomen. The broad ligaments appeared to form one continuous mass of inflamed tissue, stretching across the roof of the pelvis, and firmly fixing the uterus. The temperature was 101° F., and the pulse 130, small and thready. The patient frequently vomited a little green fluid. The tongue was clean and moist. There was a very slight vaginal discharge, which had not an offensive odour. I diagnosed an acute, wide-spread pelvic cellulitis, which I treated by hot applications and opium given *per rectum* in sufficient quantity to soothe the pain.

Next day Dr. Percy Boulton saw the patient with me. He agreed with my diagnosis, and we looked on the case as a very serious one. The patient was removed to the care of Dr. Boulton. On the 22nd her condition became much worse. On December 23rd Dr. Boulton discovered some soft growth presenting at the os uteri, and as the only possible means of helping the patient, by removing a centre of septic infection, he dilated the cervix, and removed as much as possible of this growth. Before interfering with the growth he discovered that there was a perforation of the fundus of the uterus. The

patient's condition rendered vaginal hysterectomy out of the question, and she died early the following morning.

The origin of the perforation of the fundus is not obvious. It evidently was the cause of the acute symptoms showing themselves on the forenoon of December 20th, but there is no history of any strain or accident at that time. The condition of the uterus found after death, the weakness necessarily accompanying that condition before death, and the febrile attack for which Dr. Mackintosh was first called in, would all tend, however, to so weaken the tissues that a very slight strain might lead to a rupture of the womb.

At the autopsy Dr. Hebb found that "the stomach and some coils of intestine were much distended. The omentum was firmly fixed to the pelvic viscera and held taut over the distended bowel. Much pus, purulent lymph, and foul-smelling fluid were found in the peritoneal sac. The last five or six inches of the ileum and the junction of the rectum and sigmoid flexure were fixed by old adhesions to the fundus uteri. The intestinal coils were matted together by soft, recent adhesions. On reflecting the omentum, a ragged hole roughly triangular in shape, with sides about 1½ inches in length, was seen in the fundus uteri. The uterus was 4½ inches long, and measured 3 inches across its fundus. The os was widely patulous. On making a vertical section the internal aspect of the fundus was found to be rough and ragged from the presence of coarse bands of tissue. The subjacent uterine tissue was soft, spongy, and vascular. On the anterior aspect of the fundus were two isolated masses of spongy vascular deposit, the size of Spanish nuts. The uterus was fixed to the right side of the pelvis by a mass of white fibrous tissue, in which were several abscess cavities and deposits of new growth, similar to that in the uterus. In this mass the right ovary and the end of the right ureter were implicated.

"Both Fallopian tubes were dilated and filled with pus. The fimbriated ends, though much swollen, were not

adherent. The left ovary was hyperæmic and soft, but otherwise normal.

"The liver weighed 75 ounces. It was very soft, of a pale red hue, and mottled all over with yellow areas.

"The spleen weighed 17 ounces. Its surface was covered in part with yellowish lymph. Its substance was homogeneous, of moderately firm consistence, and of a dark mauve hue.

"Each kidney weighed 5½ ounces. Both were extremely pale and flabby. Their surfaces were smooth, and the cortices did not appear wasted. In both kidneys there were numerous small cysts, varying in size from that of a pea to that of a small walnut. The right ureter was much dilated, and the right pelvis slightly so.

"The adrenals and pancreas were normal. There was no deposit visible to the naked eye in the abdominal glands.

"On the pleura at the base of the right lung there was a thin deposit of yellow lymph, and both pleuræ exhibited protrusions due to deposits in the subjacent lung. The lungs were spongy and fairly crepitant, except where there were deposits, of which more than forty were counted. These deposits were of spheroidal shape, of moderately firm consistence, with depressed surfaces, and on section they presented very similar appearances to those of the isolated masses in the uterus, and to those of the masses in the pelvic cellular tissue. If anything, they were rather firmer in consistence. The deposits were larger in the lower lobes than in the upper. The mediastinal glands were similarly affected. None of the deposits were breaking down or suppurating.

"The heart weighed 8½ ounces. There was much firm, decolourised clot in the right cavities. The endocardium was normal. The muscle was soft and pale.

"Microscopic examination of sections of a nodule from the uterus shows collections of sarcoma cells. These cells vary in size and shape, most being large with a single nucleus. Besides these there are not a few large

Plate I.

Fig. 1.

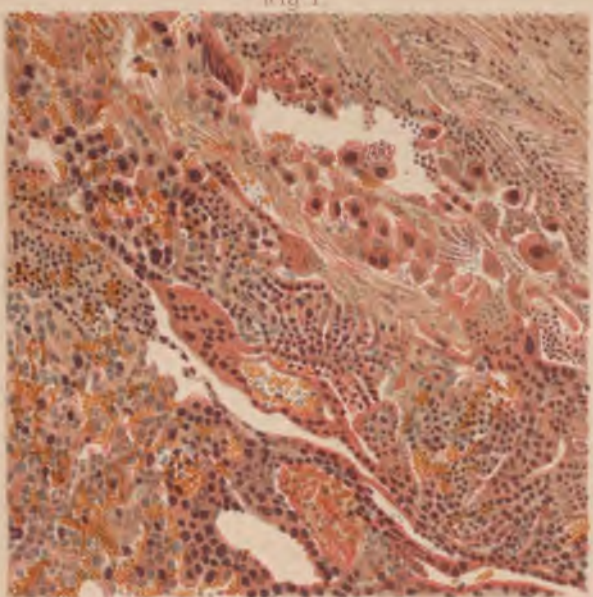

Uterus. × 100

Fig. 2.

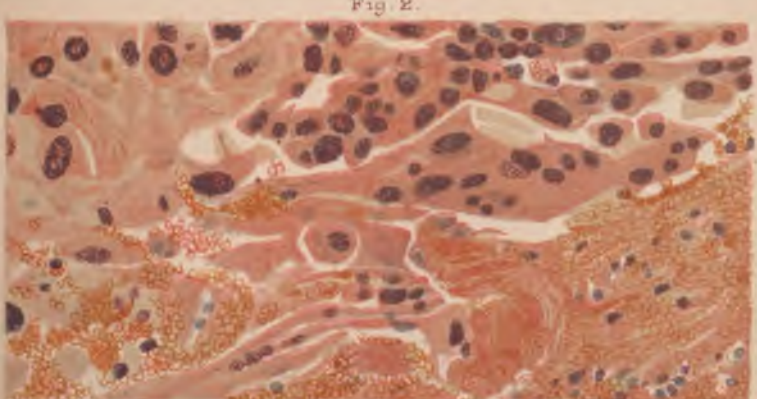

Lung × 300

M.H. Lapidge del.t

West, Newman chromo lith.

irregularly-shaped masses of protoplasm with several or many nuclei.

"The cell-areas are chiefly located in the peripheral portion of the nodules, the centre and the greater part thereof being composed of blood-corpuscles entangled in a fibrous coagulum. The lung sections are quite similar.

"There are not a few cell inclusions, and in some places appearances having some resemblance to thin-walled vessels."

I have somewhat hastily put together these notes on the suggestion of my colleague, Mr. Doran, as the case seems to bear directly on the subject of the papers to be discussed to-night.

Dr. Hebb has placed very beautiful specimens of sections of the new growths under microscopes on the table, and the appearances have been faithfully reproduced in the accompanying plates.

A CASE OF DECIDUOMA MALIGNUM OCCURRING IN ENGLAND.

By J. Rutherford Morison, M.B.

(Communicated by Alban Doran.)

[In submitting these clinical notes of Mr. Morison's to the consideration of the Society, I may state that the author was struck by the fact noted in my recent contribution on "Placental Polypus,"* that no case of malignant change in the uterus directly associated with a recent pregnancy had been reported in England. Yet this remarkable disease, "deciduoma malignum," has been repeatedly observed on the continent of Europe. In the discussion on the above-mentioned memoir, Dr. Herbert Spencer expressed a belief that a case once under his observation was really an instance of this interesting disease.

I also exhibit for the author, Mr. Rutherford Morison, assistant surgeon to the Newcastle-on-Tyne Royal Infirmary, the uterus (see fig.) which he removed (Museum R.C.S., 4672 D.*a*), and two microscopic sections of the growth discovered in its cavity. It seems possible that the growth was originally a submucous uterine myoma, and that it became invaded by so-called decidual cells. This invasion is shown very clearly in one section. In the other the greater part is plain muscle-fibre seen in full length and in section, but there is a distinct area of cell invasion.—A. Doran.]

M. G—, aged 35, sent to me by Dr. Harrison of North Shields, in November, 1892, gave the following history.

She felt quite well till her confinement nine weeks ago.

* 'Trans. Obstet. Soc.,' vol. xxxvii, 1895, p. 229. I refer at the end of that paper to recent literature on the subject.

Labour was difficult, for the presentation was transverse; she was delivered by turning. In less than a fortnight

she was up and going about, feeling as well as after previous confinements. The lochial discharge did not entirely cease, but was light-coloured and insignificant in amount. Six weeks after her confinement she began to bleed seriously, and at once went to bed. The bleeding only lasted a few hours, and it ceased when she fainted and became unconscious. Twice during the succeeding fortnight she had similar attacks, though she kept quiet and remained in bed. On each occasion the loss of blood was so sudden and severe that she lost consciousness.

Her previous health had been excellent. She had nine children born at full time; the eldest was twelve years of age. The puerperia had always previously been normal. She never menstruated between her pregnancies.

Previous to marriage she had no menstrual trouble. The family history was unimportant.

The patient was admitted to a private hospital under my care. She was a very stout, easy-going, dark-complexioned woman, profoundly anæmic, with waxy skin and pale mucous membranes. Her thoracic and abdominal organs, so far as could be ascertained, were healthy.

Per vaginam.—Os patulous; uterus considerably enlarged.

On November 1st, 1894, the uterus was explored, curetted, and swabbed out with chloride of zinc under an anæsthetic. On introducing the finger, the enlarged cavity of the uterus was found to be occupied by a soft friable structure, and the amount removed with a curette half filled a saucer. The scraping examined microscopically was found to consist chiefly of changed blood-clot, though it was thought that in one specimen placental tissue could be recognised. On November 6th, 1894, the patient returned home.

On arriving at home she went to bed, where she remained till her re-admission to the private hospital. She felt quite well till November 10th, when she began to have bearing-down pains.

These continued more or less till November 23rd, when a violent hæmorrhage commenced. A variety of remedies were tried, but the bleeding continued till the following day, when the uterus was plugged, and the condition of the patient had become very serious. Next day the plug was removed, and there was no further hæmorrhage.

On November 25th, 1894, she was re-admitted to the private hospital, very ill. Her whole body was swollen (anæmic dropsy), and the pallor was extreme.

On November 26th the uterus was again explored under an anæsthetic. The same conditions were present as on the previous occasion. After thorough curetting the cavity was swabbed out with iodised phenol and plugged with iodoform gauze. No hæmorrhage followed the operation or the removal of the plug three days later.

Some of the material removed, which looked like changed blood-clot, was sent for examination to the Clinical Research Association, and the report on it was, "The scrapings show abundant evidences of squamous-celled epithelioma. The growth has a thick coating of blood-clot, and the processes embedded in the clot have undergone degenerative changes."

On December 11th, 1894, in consequence of this report, the uterus and both ovaries and tubes were removed by the vagina.

(In the specimen now exhibited one ovary and tube have been since cut off for histological purposes.)

The uterus and the broad ligaments were secured by four pairs of large and eight pairs of small hæmostatic forceps, and the peritoneum drained through the vagina by a strand of iodoform gauze. Not more than half an ounce of blood was lost during the operation, and the patient was put to bed, apparently no worse. Her recovery was somewhat interrupted by an attack of phlebitis of the internal saphena vein, but she went home on December 29th in a much improved condition, and soon recovered her usual health and energy. The extirpated uterus was about double its normal size, and soft and flabby. Externally a small vascular nodule was seen at the fundus, about the size of a split marble, pushing the peritoneum outwards, but apparently not involving it. On opening the uterus, a growth about the size of a Tangerine orange occupied the upper part of the enlarged uterine cavity. It infiltrated the upper and posterior walls of the uterus, and was continuous with the nodule outside, and had a distinct broad pedicle half the circumference of its body.

For the after history of this case I am indebted to Dr. Harrison, who says, "Four months after the last operation hæmoptysis came on. It only occurred at intervals at first, but soon dyspnœa set in, and œdema of both legs. There was no doubt of the lung tumour, the bulging of the scapula being most marked, and dulness gradually extending up the back on the left side. Dr.

Philipson saw the case with me, and had no hesitation in agreeing with my opinion."

Death occurred on July 11th, 1895. I could get no post-mortem. There was no sign of recurrence of the disease in the abdomen or vagina.

A CASE OF DECIDUOMA MALIGNUM.

By Herbert R. Spencer, M.D., B.S.Lond.,
PROFESSOR OF OBSTETRIC MEDICINE IN UNIVERSITY COLLEGE, LONDON; OBSTETRIC PHYSICIAN TO UNIVERSITY COLLEGE HOSPITAL.

(Received February 12th, 1896.)

(*Abstract.*)

The author gives a full clinical history and post-mortem record of a case of deciduoma malignum occurring in 1889—the first case, he believed, observed in this country. The disease occurred in a young Danish woman twenty-seven years of age, a secundipara (whose previous labour took place at the age of twenty). The first symptom of the disease (passage of masses of the growth) occurred twenty-eight days after a normal labour which was followed by a normal puerperium. Subsequently there was repeated discharge of masses of growth and of blood, and the disease ran a septic course and terminated fatally within ten and a half weeks of delivery.

At the necropsy an ulcerated and gangrenous growth was found at the placental site, the ulceration and gangrene having nearly perforated the fundus. Secondary growth was also found in the cervix and in the lungs, but nowhere else in the body. The growth in all three situations is similar and is characteristic of deciduoma malignum, being apparently a large-celled sarcoma with the typical "syncytium." A full account of the microscopic appearances is given. The necessity of early diagnosis and treatment by vaginal hysterectomy is pointed out. The specimens, drawings, photographs, sections, and temperature chart are exhibited.

Mrs. E. T—, a secundipara, by birth a Dane, by occupation a restaurant waitress, was admitted under

my care into University College Hospital on September 2nd, 1889, complaining of loss of blood after her confinement.

The patient was delivered in the hospital maternity on July 19th, 1889. The labour was normal, lasting ten hours; the child, a female, was born alive in the first vertex position; the placenta was delivered naturally ten minutes afterwards. The patient kept to her bed for ten days, when she was certified "well."

During the puerperium there was not an excessive quantity of lochial discharge, which was quite sweet; no clots were passed, and the after-pains were very slight. On the seventeenth or eighteenth day after her confinement the patient returned to her work, and about a week later, on getting up one morning, she passed five or six black lumps from the vagina during micturition; they were rather hard, and there was no trouble in passing them, though for a few hours previously the patient had pains in the hypogastric region.

The patient now kept to her bed "on and off" for a week, and had a similar attack about a week after the first, losing a quantity of blood in addition to the "lumps." She then came to the hospital for some strengthening medicine, as she felt very weak.

On August 28th there was a third loss of "lumps," but no blood. Since this date the patient had had a foul-smelling discharge, which was now diminishing. There was no pain.

Menstruation commenced at the age of fifteen. The courses had always been regular except during pregnancy; the duration was from five to seven days; the quantity rather small (six or seven diapers used), the interval between the periods four weeks; pain was very slight. The patient had never lost "lumps" before.

There was an interval of seven years between the two pregnancies. The bowels had been rather confined during the last three weeks.

There was no history of *previous illnesses* except that

the patient said she had "rheumatic fever" after her first confinement, which causes her to lose her milk.

The *family history* was good. There was no history of malignant disease; the father died at sixty-six of stricture; the mother, sister, and four brothers were alive and healthy.

On admission, the *present state,* as far as it could be taken, was as follows.

The temperature was 102·6°, the pulse 135, the respiration 34. The patient was extremely ill and in a fainting condition, the pulse being very weak. The fundus of the uterus was felt to be considerably enlarged, the cervix open to admit several fingers; its posterior lip somewhat hard; on its anterior surface was felt something like a growth, but it was tougher than ordinary malignant growth and by the speculum was seen to be of a dirty green colour. There was a horribly offensive discharge.

Fingers were introduced into the cervix, and several pieces of what was thought to be putrid placenta, horribly offensive, were removed from the neighbourhood of the internal os. There was no bleeding; the finger could not be passed through the internal os, and a small piece of "placenta" which could just be felt through it could not be removed. The patient was copiously douched with 1 in 2000 sublimate solution before, during, and after operation without loss of blood. The patient was too ill to have the uterus dilated. Three iodoform bougies were passed into the uterine cavity, and injections of Liquor Iodi (ʒij to Oj) were ordered every four hours.

On September 3rd, at 3 p.m., the temperature was 103·6°. Three more iodoform bougies were introduced into the uterus, and the iodine injections continued as before.

On September 4th the abdomen was a little distended, but free from tenderness: the fundus of the uterus lay a little to the right of the middle line, and rose to a height of four inches above the pubes; it was smaller than before, and was soft, almost boggy, to the feel.

Several small pieces (apparently decidual) were removed during the examination, and at 5 p.m. several pieces similar to those removed from the cervix were brought away by the finger from the cavity of the uterus, which was douched with 1 in 2000 sublimate solution, and two iodoform bougies were then inserted. The temperature at 7 a.m. was 100·4°, the pulse 118.

On September 5th the patient was very weak, but free from pain; the temperature 102°, the pulse 140: the discharge was still very offensive. The uterus was douched with iodine solution through a catheter, and some small pieces of putrid tissue came away. Iodoform emulsion was then injected into the uterus.

On September 6th the patient seemed rather less weak. The temperature was 101°, the pulse 120. Boracic acid injections were substituted for iodine injections every four hours. The discharge was rather less in amount, but still very foul. Another small fragment of putrid tissue came away during the application of the douche. Two iodoform bougies were introduced into the cervix. This morning there was a slight pain on inspiration in the right axillary region, and doubtful friction sounds were heard in that situation.

The temperature at 3 p.m. was 103·8°, the pulse 140. The patient passed a fragment of putrid tissue about three inches long.

On September 7th the patient felt much better, had a better colour, and said she was hungry. She had been kept hitherto on spoon diet, but had some fish to-day. The boracic acid douches and the iodoform bougies were used as before. The pain in the right axilla had quite disappeared.

On September 9th the condition was about the same. No more lumps were passed. The discharge was still fœtid. The temperature was 101·2°, the pulse 124. The douches were continued.

On September 10th a small shreddy fragment of tissue was passed. The temperature reached 101·6°.

On September 11th the discharge was diminishing, and the patient felt stronger. The temperature reached 102·2°.

On September 12th the uterus was douched through a catheter, and several fœtid shreddy fragments came away. Iodine injections were substituted for the boracic. The patient was free from pain and tenderness.

On September 16th the condition was practically unaltered. An enema was given yesterday, the bowels having been confined for three days. The patient was ordered oysters and chicken and bacon.

On September 18th the fœtid discharge was still present. The temperature was 101°.

On September 19th the patient had three rigors—at 11 a.m., 4 p.m. and 5.30 p.m. At 11 a.m. the temperature was 103·2°, at 4·30 p.m. 104·6°, at 6 p.m. 105·2°, at 7 p.m. 105·2°. At 3.45 p.m. a speculum was passed, a catheter introduced into the uterus, and a solution of 1 in 2000 sublimate injected, the discharge being still very fœtid. Three iodoform bougies were inserted. During these proceedings the patient began to shiver violently, and the temperature rose as just mentioned. Through the speculum two small black masses about half an inch long were seen projecting from the os; they had a sloughy appearance somewhat like malignant growth, and were thought to be pieces of sloughing mucous membrane.

On September 20th the uterine cavity was again douched with 1 in 2000 sublimate solution, and two iodoform bougies were inserted.

On September 21st the douches were resumed every four hours.

On September 23rd there was pain near the right nipple on breathing, and well-marked friction was heard in that situation.

On September 24th Dr. John Williams resumed the care of the wards, and made the following note:—"The patient is very sallow and very anæmic; the tongue is quite clean; the patient says she is better. The pulse is

120, small, weak, compressible, regular. Some friction sounds are heard to the right of the nipple. There is no tenderness of the abdomen, and the fundus of the uterus cannot be felt. The anterior lip of the uterus is normal; the finger can be passed into the canal as far as the first joint; it is rough and ragged; the posterior lip is also rough and ragged, but firmer than it was three days ago; there are evidently sloughs to come away, for portions of them come away on the examining finger."

On September 25th the pain over the right lung had disappeared after the application of poultices. It was found to-day that the patient could not move the right arm or leg; the tongue was protruded in the middle line. There was no paralysis of the face. Sensation and speech were unaffected. The urine contained a trace of albumen, and a loud murmur could be heard over the cardiac area.

On September 26th the patient was transferred, on account of the paralysis, to the care of Dr. Bastian, to whom I am greatly indebted for the post-mortem notes and the specimens exhibited.

On September 27th the pulse was 124, respiration 40. There was an occasional slight, short, ineffectual, painful cough. The breath-sounds were harsh over the front of the chest; friction was heard over the middle of the right axilla. The heart apex-beat was felt in the fifth space in the nipple line, but was more distinct in the fourth space. There was a blowing systolic murmur at the apex conducted into the axilla, and a very harsh systolic murmur at the pulmonary cartilage; a loud rough systolic murmur could also be heard at the aortic cartilage.

On September 28th and 29th the paralysis continued, and on the 29th œdema of the right leg and ankle set in. Crepitation was heard in the left axilla. The urine was of sp. gr. 1010, free from albumen.

On September 30th the œdema of the right limb extended to the thigh, and the patient, who had become progressively feebler, died at 10.30 p.m.

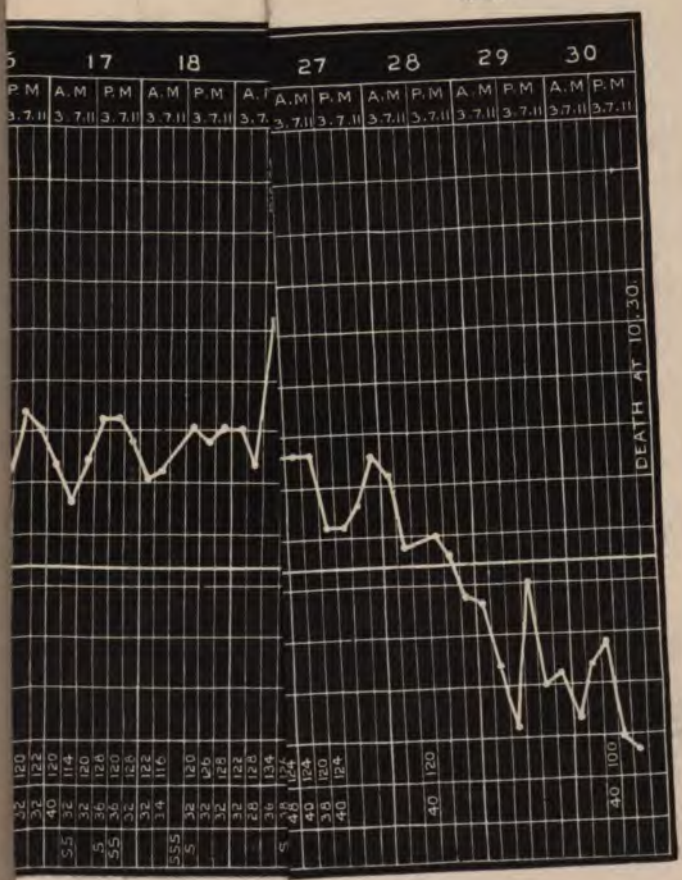
17
18
27
28
29
30
A.M
P.M
3.7.11
DEATH AT 10.30.

Abstract of Notes on the Necropsy, thirty-six hours after Death.

The *right pleura* contained several ounces of yellowish fluid; the *left pleura* contained rather less fluid, and there were a few adhesions.

The *pericardium* contained two or three ounces of fluid: there were no adhesions. A few extravasations were seen about the right auricle.

The *heart* was of medium size, unusually well covered with fat, especially over the right auricle. The right auricle and ventricle contained rather loose dirty red clots, in part discoloured, but not firmly adherent anywhere to the parietes. The tricuspid and coronary valves were healthy. The left auricle contained some loose dirty red clot. The mitral orifice was of medium size. The left ventricle contained some dirty red clot, partly adherent about the apex. The segments of the mitral valves were thicker and more vascular than normal, especially the free border, and on the right segment there were a few vegetations, probably not of recent date. There was no congestion of the valves about the base of the vegetations. The muscular tissue of the valve was unusually pale, as also the cut surface. The consistence of the muscular substance of the valve did not seem to be diminished. The aortic valves showed slight general thickening. There were no vegetations about the sinuses of Valsalva. The heart tissues were healthy and of normal elasticity.

The *liver* was of medium size, the colour paler than natural; in some parts of the surface the capsule was thickened. There were no localised patches of disease seen in any part of the organ; the cut surface was extremely pale throughout, the consistence distinctly less than normal. The gall-bladder contained a medium amount of fluid bile.

The *spleen* was small and flaccid. There was some

thickening of the capsule. The cut surface showed a pale dirty red pulp, with no localised areas of disease. The substance was throughout softer than natural.

The kidneys.—The left organ was of medium size, very flaccid; the surface extremely pale throughout, except for a small area of congestion. The capsule stripped off freely, leaving the surface quite smooth. The right organ presented similar characters. There was no evidence of thrombosis or of embolism.

The *brain* showed the parietal and frontal regions of the left side mottled by large irregular patches, due to minute injection of the vessels of the pia mater. In the midst of this the large veins running from before backwards were completely thrombosed (the cause of the paralysis). The occlusion extended into the longitudinal sinus, in which there was a large amount of decolourised clot. (Detailed description of the condition of the rest of the brain omitted.)

The lungs.—On the surface, and to a smaller extent throughout the substance of both organs, nodular patches in size varying from a pea to a walnut were found. Of these there were from thirty to fifty in each lung. The nodules were of a pale yellowish-white colour on section, and infiltrated with blood. They were mostly rounded and sharply defined, the surrounding lung tissue being paler than normal and œdematous. One large mass of the size of a walnut was found broken down in the centre, discharging a dirty, foul-smelling fluid (Fig. 1). In one lung two large masses were found, 1 inch to 1¼ inches in diameter, and projecting half an inch from the surface, which had been torn during the removal of the lung from the chest. The surfaces of these masses presented an appearance similar to what old writers called fungus hæmatodes; on section these masses were similar in appearance to those already described. The tissue of these growths were somewhat spongy in character, light in colour, and mixed with extravasated blood. On section of other portions of the lungs the pulmonary vessels in

many parts were found to be completely distended with pale decolourised clots, the consistence of which was not firm. These clots stood out from the cut surface of the lung; some of them were one-fifth of an inch in diameter. At the root of the right lung the pulmonary artery was found to be completely occluded by a very firm, colourless clot. From the main bronchus there issued a considerable quantity of frothy fluid; the lining membrane was very pallid.

The *uterus* measured 4½ inches in length, 2½ inches in breadth, and 1½ inches in thickness. The cervix measured 2 inches in length, the cavity of the uterus was 3½ inches in length; the posterior wall of the body was 1⅛ inches in thickness.

On opening the uterus along the posterior wall there was found a gangrenous cavity at the right side and posterior aspect of the fundus. This cavity was as large as the last joint of the thumb, and contained soft and shreddy gangrenous growth easily breaking down. The cavity, which had evidently formed by the breaking down of the growth, extended to within one-tenth of an inch of the peritoneal surface (Fig. 2). At the left side of the posterior wall of the fundus was found gangrenous growth in the shape of shreds and nodular elevations of a dirty green colour. The lower margin of this growth, which evidently occupied the placental site, was sharply marked off from the mucous membrane of the rest of the body of the uterus, which was smooth and of a dirty green colour. The cervix was also the seat of a fungated and ulcerated growth in a gangrenous condition; it occupied the whole of the lateral and posterior walls, and on the right side had extended rather above the internal os. The growth had nearly perforated the cervical wall, and had extended to within one-tenth of an inch of the lower surface of the portio vaginalis.

The right *ovary* contained at its inner extremity a corpus luteum, measuring half an inch by a quarter of an inch, of a pale yellow colour, and without a central cavity. The tissue of both ovaries was pale.

FIG. 1.

A section of the two lungs placed side by side, showing secondary growths, of which one is breaking down in the centre.

FIG. 2.

The uterus has been opened posteriorly, showing the growths in the body and cervix; the lower part of the body and the anterior wall of the cervix are not affected by the growth.

The *Fallopian tubes* presented a normal appearance, except that the peritoneum over them was slightly congested. The fimbriæ were very red, but free from adhesions. A little fluid (? pus) exuded from the left tube on squeezing, and from the right a considerable quantity.

There was no lymph in the peritoneum, and only a little serous fluid.

No growths except those described were found in any part of the body.

Microscopic Examination.

The growth of the body of the uterus (Plates II and III). —Under a low power the surface of the growth is found to be shaggy, and covered with blood and fibrin. The growth itself is of loose texture, and is made up of isolated multinucleated masses of large cells (the so-called "syncytium"), and of a loose tissue between the syncytial masses containing individual cells similar to those of the syncytium; in this tissue hæmorrhages, and in places aggregations of leucocytes, are seen. The syncytium is often extensively vacuolated. The growth is penetrating into the muscular wall.

Under a high power (one-sixth) the syncytium, which in places has the appearance of a huge multinucleated cell, is evidently made up of a number of large cells aggregated or fused together. In parts, the outline of the cells can be indistinctly made out. The ground substance of the syncytium is not uniform; it is coarsely granular, and stains of a brownish-purple colour with logwood; in some cases it has slight linear marking, and is often extensively vacuolated. The nuclei of the component cells are oval or rounded, or of irregular shape (according to the plane of section), of very large size, and stain a deep blue-black with logwood. The loose tissue between the syncytial masses is a delicate reticulum of connective tissue, in the meshes of which are large cells

similar to those making up the syncytium. The loose tissue is, in parts, permeated by a fine fibrinous reticulum in which red and white blood-corpuscles can be seen. The individual cells forming the new growth are of remarkable size and of various shape, many being elongated or short-fusiform, others being oval or round; some are of irregular shape and branched; a few are of delicate fusiform shape. The nuclei are very large, stain deeply with logwood, and contain a few or many dark granules, especially near the periphery. At the growing edge the growth passes irregularly but rather abruptly into the fibro-muscular tissue of the uterus. There is no preceding small-cell infiltration. A few of the individual large cells may be found lying isolated at a greater depth than the "syncytium."

The cells of the superficial parts of the growth stain badly (necrosis).

The fibro-muscular tissue beneath the growth had the œdematous appearance usually met with in the septic uterus.

The growth of the cervix (Plate IV).—The appearances in the cervix resemble those in the body of the uterus except that the hæmorrhages and leucocytes are more abundant. Vacuolation of the syncytium is marked, and the vacuoles are sometimes filled with blood-corpuscles.

The growth in the lungs (Plate V).—In the lungs the same appearances are found as in the uterus, with modifications produced by the alveolar structure, which is still apparent in the small growth (one-eighth of an inch in diameter) from which the section was taken. There is very little inflammatory reaction about the growth. The syncytium is met with, but less in frequency and magnitude than in the uterus. The cell nuclei generally do not stain so well as in the uterus. Hæmorrhages and leucocytes are met with in abundance throughout the section.

Remarks.

This case, which occurred in 1889, is, I believe, the first case of deciduoma malignum which has been observed in this country. My interest in it was aroused during life by the repeated discharges of growth (which was then thought to be putrid placenta), and by the resemblance of the cervix to that affected by malignant growth, although the patient was only twenty-seven years of age; and, after death, by the growth discovered in the uterus and lungs. I obtained good microscopic sections of the lungs, showing the secondary growth to be apparently a large-celled sarcoma; but the portion of the uterus I examined was in such a putrid condition that the sections did not stain well, and the primary growth could not be satisfactorily described. I therefore did not publish the case, but noted it as one of malignant disease developing at the placental site, of which the only other cases then known to me were Chiari's *; and I hoped to be able in the future to obtain another case, in which the primary growth could be more satisfactorily examined.

Disappointed in this hope after more than six years, I asked my friend Mr. Lawrence, the Curator of University College Museum, to kindly make further sections from the Museum specimens. By cutting the fresher portions near the edge of the growth Mr. Lawrence has been able to obtain the beautiful sections exhibited, for which I am greatly indebted to him. They show typically the growth known as deciduoma malignum in the body and cervix of the uterus, and in the lungs. From the greater extent of the growth in the body, and from a comparison with other cases, there is no doubt that the primary growth originated in the body, and that the cervix and lungs were secondarily affected. Secondary growth in the cervix has, as far as I know, hitherto only once been

* Hans Chiari, "Ueber drei Fälle von primären Carcinom im Fundus und Corpus des Uterus," 'Medizinische Jahrbücher,' Wien, 1877.

observed in this disease,* though it has been met with in the vagina in thirteen cases.

I do not purpose entering into the question as to whether the growth originated in the decidua or in the chorionic villi—a question which, I believe, cannot be answered by a consideration of this case. Perhaps I may allude, however, to the interval of seven years between the two pregnancies as possibly pointing to an abnormal condition of the endometrium. But before the pathogeny of the disease can be thoroughly known, microscopic investigations will need to be made of the unseparated, adherent, hydatidiform, and ectopic placenta, and of placental polypus.

A great advance has been made in gynæcology during the last seven years by the further light which foreign observers have thrown upon this interesting disease. The growth appears to be a sarcoma, and the large cells and the "syncytium" present such remarkable appearances that diagnosis from fresh scrapings would appear not to be difficult. I would urge the importance of a careful microscopic examination of all masses passed during the puerperium.

The diagnosis must be made early, seeing that in my case death took place within ten and a half weeks, and there was a suspicion of growth in the lung in seven weeks after delivery.

It is in the hope that this record will prove of interest, and will stimulate others in this country to diagnose and treat by vaginal hysterectomy this otherwise fatal disease that I now fulfil the promise made last year to lay the case before the Society.

Dr. Spencer illustrated his paper by a series of lantern slides of photographs and photomicrographs.

* R. Klien, 'Arch. f. Gyn.,' xlvii, p. 243.

DESCRIPTION OF PLATES II—V.

Illustrating Dr. Herbert Spencer's case of Deciduoma Malignum.

PLATE II. A microscopic section of the growth in the body of the uterus, showing a piece of the tumour penetrating in the shape of a wedge into the muscular wall, which is seen on each side enclosing the apex of the wedge. Extensive masses of syncytium are seen, and (on the left) the abrupt line of demarcation between the syncytium and the uterine tissue is shown. (Low power, 1 in. obj.)

PLATE III. A microscopic section of the growth in the body of the uterus, showing syncytium and individual cells and inter-cellular reticulum. (High power, $\frac{1}{6}$ in. obj.)

PLATE IV. A microscopic section of the growth in the cervix of the uterus, showing extensive masses of syncytium (in places vacuolated and filled with blood); also infiltration of leucocytes, of which a large collection is seen at the upper part of the section. (Low power, 1 in. obj.)

PLATE V. A microscopic section of the growth in the lung, showing intra-alveolar growth; several small masses of syncytium are seen. (High power, $\frac{1}{6}$ in. obj.)

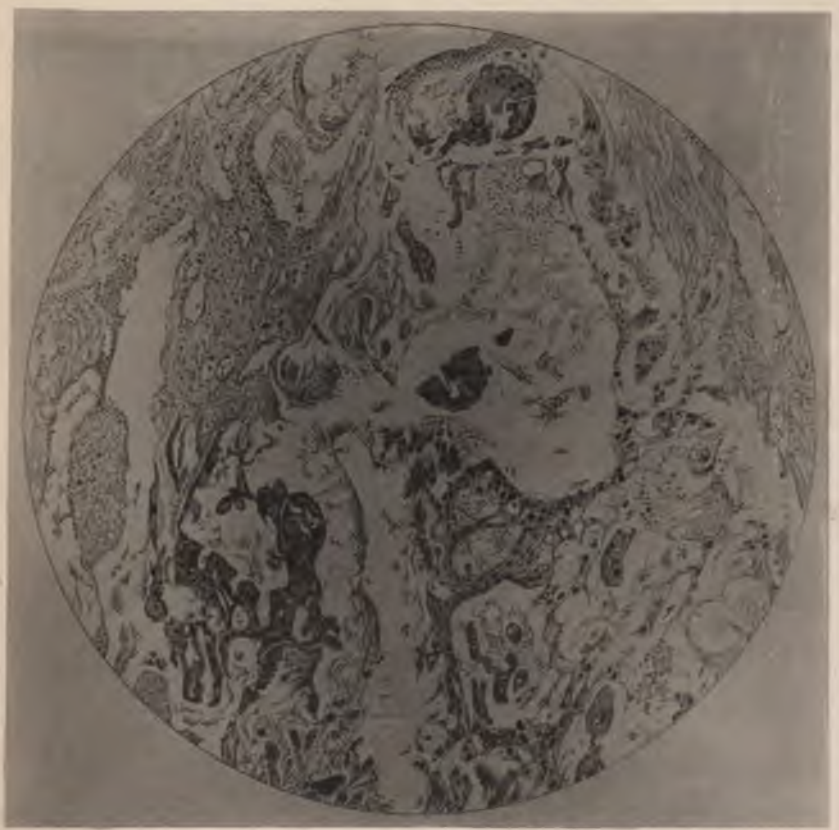

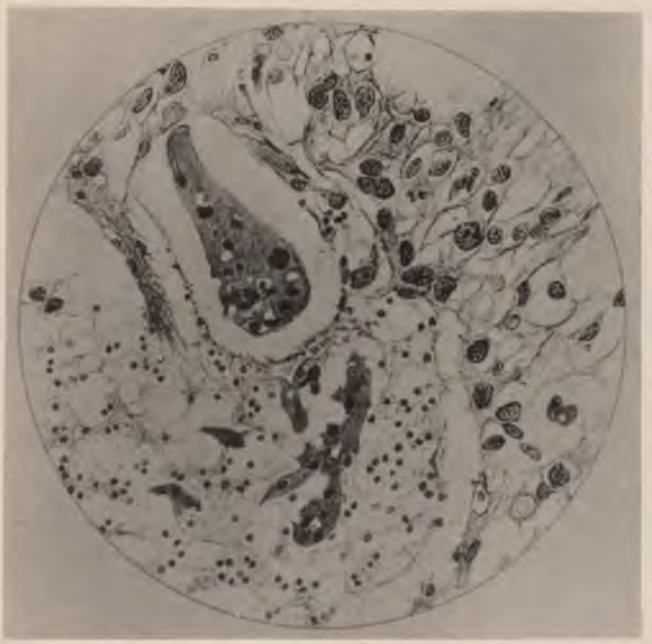

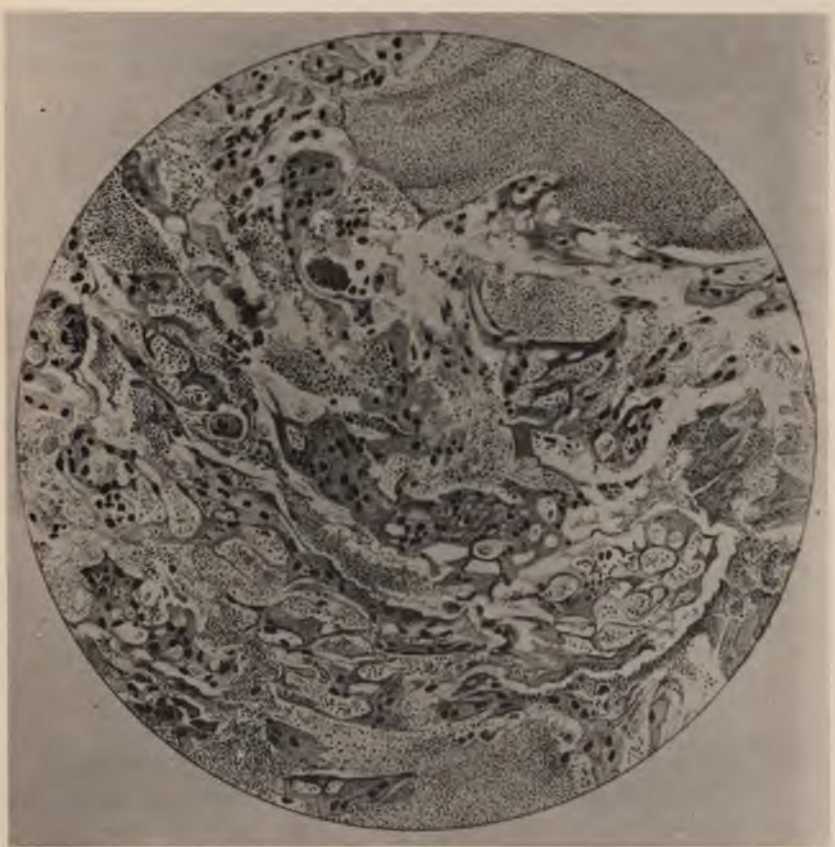

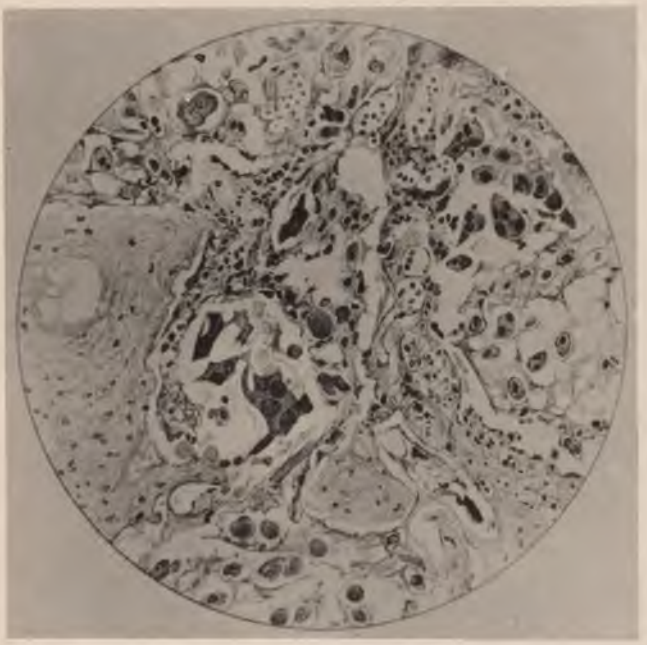

DECIDUOMA MALIGNUM: A CRITICISM.

By T. W. Eden, M.D., M.R.C.P.

(Received March 2nd, 1896.)

(*Abstract.*)

The author refers to the number of cases of malignant uterine growths occurring subsequent to gestation which have been recently recorded, mostly by German observers. The most important cases are those of Sänger, Gottschalk, Marchand, and Whitridge Williams.

Sänger introduced the term "deciduoma malignum." He thought that in his case the tumour arose in the decidua, and was composed largely of so-called "decidual cells." The author believes that cells precisely like those found by Sänger occur in the uterus under various conditions, and do not prove the origin of the growth in the decidua.

Gottschalk believes that in his case the growth arose from a "sarcomatous transformation" of the stroma of retained chorionic villi. The author shows that there is doubt as to the occurrence of a preceding gestation in this case, and points out that the structures figured by Gottschalk as sarcomatous villi bear very little resemblance to villi at all. Further, a sarcomatous change in the stroma would not account for the budding of the plasmodial layer described by Gottschalk.

Whitridge Williams' case possesses the general characters of a sarcoma; tumours were present in the uterus, vagina, and vulva, and it is not clear which was the primary growth. Williams relies for his diagnosis upon the presence in the tumours of plasmodial masses which he believes to be syncytial in origin.

Marchand records two cases, in both of which he found similar syncytial masses; he also claims to have found cells derived from the fœtal ectoderm. In one case, represented as a tubal gestation in a girl of seventeen, there was no anatomical evidence of pregnancy discovered; the tubal mass may therefore have been a primary malignant growth.

The author believes that plasmodia, not unlike those figured by Williams and Marchand as syncytial masses, are frequently found in sarcomatous growths in other parts of the body, and doubts whether there is sufficient evidence to justify the view that they arise from placental relics.

A case recorded by Meyer is referred to, in which there seems to be proof of the origin of a malignant growth in retained myxomatous villi (hydatidiform mole).

A GREAT deal of attention has been directed during the last few years to the subject of malignant uterine growths arising during the puerperium. The subject has proved very engrossing to German gynæcologists, and there is already an extensive literature of the subject. About twenty-eight cases have now been recorded, mostly under the name "deciduoma malignum." Several of these cases are clearly ordinary forms of uterine cancer, and need no special attention. The remainder all possess the general characters of sarcomata. They are rapidly growing tumours, with a marked tendency to hæmorrhage and necrosis, containing no well-formed vessels, tending to perforate neighbouring veins, forming metastases with great rapidity, by propagation along venous channels, and occurring at all ages from seventeen to fifty. In their histological characters, however, they differ considerably. A very important point is the frequency with which they are found to succeed the occurrence of a vesicular (hydatidiform) mole; in thirteen of the twenty-eight cases such a mole had immediately preceded the development of the malignant growth. This circumstance seems to have suggested the idea that they may in these cases have originated in retained portions of the altered villi; and

from this point it was easy to proceed to the theory that such cases as were not preceded by the vesicular mole may have arisen from normal villi retained at the placental site. This theory of the origin of malignant growths in retained placental relics has greatly stimulated the study of malignant uterine tumours, and especially of those arising in connection with gestation or the puerperium.

When we consider the normal life history of the placenta we must, I think, admit that there is nothing altogether improbable in such a theory. The placental villi live as parasites upon the maternal blood, they invade the mucous and muscular tissues of the uterus, they perforate venous channels, and they may be detached and carried as emboli to the lungs, as has been proved by Schmorl in a case of puerperal eclampsia.* That is to say, they possess characters which, in new growths, we are accustomed to regard as evidences of malignancy. We know that in the case of the vesicular mole, the altered villi continue to proliferate after the death of the fœtus, and that they may excavate the muscular wall deeply, even to the point of perforation. In fact, the vesicular mole shows the characteristics of malignant growths more markedly than do normal chorionic villi. There is, however, no evidence that normal villi ever continue to develop after the death of the fœtus. The assertion has been frequently made that in extra-uterine pregnancy they may do so, but the increase in size of the placenta which undoubtedly occurs in some cases, has been proved to be due to hæmorrhage into its substance, and not to actual growth.† And I believe there is no evidence whatever that a retained uterine placenta ever continues to grow after the death of the fœtus. It is, therefore, much more difficult to believe that malignant growths may arise from retained normal villi than from relics of a vesicular mole.

* 'Path. anat. Untersuchungen über Puerperal-Eklampsie,' 1893.

† 'Ectopic Pregnancy,' Clarence Webster, 1895.

But when we are asked to believe in the existence of a class of new growths which, in their histogenesis, differ essentially from all others, considerations of probability do not carry much weight; in such a case we are certainly justified in asking that the novel pathological theory shall be adequately supported by the facts. It is because, it seems to me, the facts upon which the present theories are based are singularly inadequate, that I have ventured to lay a short discussion of them before the Society.

The first case of deciduoma malignum was recorded by Sänger in 1889. Many of the cases published by subsequent writers are imperfectly recorded, and we need only pay special attention to those of Sänger, Gottschalk, Marchand, and Whitridge Williams. These observers' cases are the most important (1) because they are fully recorded, and (2) because they represent the various stages of development of the present theory of the histogenesis of these growths. A full consideration of all the cases will be found in the writings of the two last mentioned.

Sänger's case* was that of a woman aged twenty-three, a multipara, who aborted at the eighth week in consequence of a fall from a railway carriage. The abortion was incomplete, and hæmorrhage persisted for three weeks; in the fourth week, when first seen by Sänger, there was also high fever. The uterus was curetted, and the hæmorrhage ceased entirely,—without any improvement in the patient's general condition, however. An extensive inflammatory exudation rapidly developed around the uterus, the uterus itself underwent progressive enlargement, and finally a large swelling appeared in the left iliac fossa, which was thought to be an abscess, but was found to contain no pus. There was no operative interference, and the patient died with signs of pulmonary metastasis seven months after the miscarriage.

Sänger found the growth to be a sarcoma, and believed

* "Ueber Sarcoma uteri deciduo-cellulare," 'Cent. für Gyn.,' 1889.

that it developed in the decidua because it contained numbers of large cells identical with "decidual cells," and also plasmodia resembling the decidual giant-cells. On account of its supposed decidual origin, Sänger proposed for it the name "deciduoma malignum." No villi were found in it, and he did not suggest that fœtal structures played any part in its development. Since then almost every malignant uterine growth discovered in the puerperium has been called "deciduoma" in Germany.

Very little objection can be taken to Sänger's interpretation of his case, and there is nothing strikingly novel about it. The only point I would venture to criticise is the importance he attaches to the presence of the so-called "decidual cells." Now decidual cells possess no specific characters whatever; they are merely modified connective-tissue corpuscles, and cells almost precisely like them are found in many connective-tissue tumours in other parts of the body. They are not, even in the uterus, confined to the decidua, for they may occur in the mucosa of the non-pregnant uterus under such varied conditions as mechanical irritation * and phosphorus poisoning.† And Helme has shown ‡ that cells precisely like them occur in the muscular wall of the puerperal uterus of the rabbit and other animals during the normal process of involution. The presence of such cells in Sänger's tumour does not, therefore, prove that it originated in the decidua, for their occurrence in the uterus under normal conditions is not confined to the decidual membrane. In fact, decidual cells ought not to be considered as pathognomonic of pregnancy; the decidua is pathognomonic of pregnancy, but not the "decidual cell."

Gottschalk's case § was quite different from Sänger's.

* Calderini, "Decidua-ähnlicher Zellen durch mechanischer Reiz erzeugt," 1888.

† Overlach, "Die pseudomenstruirende Mucosa uteri nach acuta Phosphorvergiftung," 'Archiv für mikr. Anat.,' Bonn, 1885.

‡ "Observations on the Uterus during Pregnancy and the Puerperium," 'Trans. Royal Soc. of Edin.,' 1889.

§ "Das Sarcom der Chorionzotten," 'Archiv für Gyn.,' Bd. xlvi.

The patient was a 5-para aged 42, who aborted at the sixth week, in February, 1892; there was severe hæmorrhage in the puerperium, and the uterus was curetted. The bleeding recurred, and curetting was twice repeated during the next four months. Still it recurred, and the uterus becoming markedly enlarged, was explored, and masses of soft friable material, said to resemble placental tissue, were removed with the finger on two occasions. Recurrence, however, was very rapid, and hysterectomy was performed in August—six months after the miscarriage. The patient remained well until the following January, when a large tumour was discovered in the right hypochondrium; this was found to be irremovable by operation, and she died in March, thirteen months after the original miscarriage. At the autopsy metastases were found in the lungs, spleen, and right kidney.

Gottschalk's interpretation of the case is that it was a malignant growth arising at the placental site from retained placental villi. The primary growth was made up of masses of branching structures resembling rather plump chorionic villi. Under the microscope they were seen to consist of an outer layer of nucleated plasmodium, corresponding to the trophoblast of young villi, and a stroma composed of masses of large round cells, with neither blood-vessels nor lymphatic spaces. In many places the plasmodium was budding. No vessels were found in the growth, only irregular blood-spaces. The mucosa and the muscularis were extensively invaded, and at the periphery the walls of the maternal veins were perforated by growing buds. The general mucosa was in a state of benign hyperplasia. The metastases were composed of exactly the same structures as the primary growth.

Gottschalk's view is that we have here a case of sarcoma of the stroma of the chorionic villi. The plasmodial layer he regards as unaltered by disease; the malignant change affects the stroma only. This theory seems entirely inadequate to explain the alleged fact that all the structures of the villi—plasmodial and cellular—were in

a state of active growth. A sarcomatous change affecting the connective tissue only would not lead to proliferation of the epiblastic covering of the villi, any more than sarcoma of a gland leads to proliferation of its epithelial tubules. If the villi multiplied by budding as in the normal placenta, a sarcomatous transformation of the stroma is quite insufficient to account for it.

But there are serious objections to accepting the view of Gottschalk that the structures he describes are derivatives of chorionic villi. His drawings show only the most superficial resemblance to villi, and it is quite impossible for the reader to say what they are. Indeed, the divergence between Gottschalk's descriptions and the illustrations which accompany them is so great, that it is impossible for anyone to feel convinced by them except the author.

Another serious element of doubt in the case concerns the supposed abortion for which the patient first sought advice. She missed one period, and two weeks later had a smart hæmorrhage: no traces of an ovum were discovered, but it was assumed that there had been a miscarriage. It is, however, somewhat rash to assume that a woman of forty-two, who has a smart uterine hæmorrhage six weeks after her last regular period, must of necessity have miscarried. In Gottschalk's theory it is of course absolutely necessary to assume that there had been a miscarriage, and that villi had been retained in the uterine wall, giving rise to the subsequent malignant growth. But he has not proved this fundamental point; he assumes it.

The cases recorded by Whitridge, Williams, and Marchand resemble one another very closely, and present many points of difference from those of Sänger and Gottschalk.

Williams' case* occurred in a 6-para negress aged thirty-five, who passed through a normal pregnancy and labour; in the second week of the puerperium a small painful nodule

* 'Johns Hopkins Hospital Reports,' vol. iv, No. 9.

appeared in the right labium majus; by the fifth week this nodule was as large as a hen's egg, and began to slough. She was sent to a hospital on account of the onset of rigors, and the clinical diagnosis then made was "sloughing hæmatoma with septicæmia." The patient died three months after confinement, apparently of septicæmia. The pelvic organs were sent to Williams for examination, but apparently he did not see the case during life. The post-mortem showed, in addition to an extensive sloughing tumour of the vulva, (1) a small secondary growth in the vaginal wall; (2) two small growths in the uterus, the larger measuring only $1\frac{1}{4}$ inches × $\frac{7}{8}$ inch × $\frac{3}{4}$ inch; (3) secondary growths in the left ovary, lungs, spleen, and kidneys.

From a microscopic examination of these tumours Williams came to the conclusion that the case was one of so-called deciduoma malignum. Such a result could scarcely have been anticipated from the clinical history of the case. The diagnosis during life was "sloughing hæmatoma of vulva," and as far as the facts are stated the existence of a uterine tumour was not discovered until the autopsy was made. At the time of the patient's death the uterine growths were both small and inextensive, and there are no clinical reasons for regarding them as primary. The clinical course of the case seems to indicate that the labial growth was the primary one, and that the uterine and other visceral growths were metastases; the general features of the case being quite typical of rapidly growing sarcoma. It must be remembered, therefore, that Williams' interpretation of the case rests entirely upon the histological observations, which, according to their author, show that the growths were all mainly composed of elements derived from the placenta.

Before discussing the microscopic appearances it will be convenient to refer to Marchand's cases.*

The first case was that of a girl aged seventeen, who came under Ahlfeld's observation with a bleeding tumour

* 'Monatsschrift für Geb. und Gyn.,' 1895.

of the vaginal wall; the tumour was scraped and the scrapings sent to Marchand for examination. In a few days it reappeared, and the scraping was repeated. A large abdominal tumour rapidly developed, and the patient died within three weeks after the first operation. The autopsy revealed the presence of a mass the size of a fist on the left of the uterus, which was found to be a distended and ruptured tube containing a necrotic mass resembling placental tissue, which appeared to be growing from the wall of the tube. No chorionic villi or fœtus could be found in this mass on the most exhaustive examination, but Marchand appeared to entertain no doubt that it was a tubal gestation on account of the dilatation of the tube, which, he says, resembles precisely that found in tubal gestation. There was a deep sloughing cavity in the vaginal wall, but no metastases were found in other organs. The immediate cause of death appeared to be pulmonary embolism.

As in the preceding case, so here, the author believes the growths to be composed histologically of placental elements. He therefore regards the tubal growth as a mole which has undergone malignant transformation of a kind entirely new to pathology. But here, again, the clinical history gives no support to such a view. How can it be clear, when neither chorionic villi nor fœtus could be found, that we are dealing with a tubal gestation at all? And how is it possible to exclude the alternative that there was a primary malignant growth of the tubal wall, causing dilation of its lumen, and leading ultimately to perforation? For Marchand's theory it is absolutely necessary that there should have been a gestation in the tube; and if that fundamental point be left open to doubt, then the entire interpretation of the case is doubtful.

Marchand's second case was that of a 9-para aged thirty-four, who suffered from severe hæmorrhage in the third week of the puerperium, after a normal pregnancy and labour. A large quantity of blood-clot and tissue

was removed. Four months later the hæmorrhage recurred, and again large masses of soft tissue were removed from the uterine cavity. Still the hæmorrhage continued, and she was then examined under anæsthesia. The uterus was found enlarged, retroverted, and adherent to the floor of the pouch of Douglas. In attempting to replace it with the sound it was perforated, so that vaginal hysterectomy had to be performed on the spot. The patient recovered, and six months after the operation remained in good health.

The clinical history of this case seems quite clear, and no objection can be taken to it. The growth was evidently much less malignant than in the two preceding cases.

As far as can be judged from drawings and descriptions the microscopic appearances in these three cases closely resembled one another. Hæmorrhage and necrosis were very marked features; the tumour was nourished by large irregular blood-spaces, no definite vessels being discovered, and there was scarcely any trace of stroma or intercellular tissue found in any part of the growths. The metastases in every instance closely resembled the primary growth in their general characters. No chorionic villi, and no structures in the least resembling them, were found; this is explicitly stated both by Williams and Marchand.

The structures which it is claimed are derived from placental elements may be divided into two groups. (1) Plasmodial masses, *i. e.* masses of multinucleated protoplasm arranged in a reticulum of anastomosing bands, or in irregular isolated masses. These structures, it is stated, are identical in their microscopic characters with the superficial plasmodial layer of the chorionic villi, and they are therefore regarded as derived from that structure, and termed, in accordance with the latest histogenetic theory, the "syncytium." (2) Large numbers of polymorphous cells with large deeply staining nuclei, which occupy the meshes of the plasmodial reticulum. These cells Marchand regards

as derivatives of the fœtal ectoderm chiefly on account of the microscopic characters of their nuclei.

In order to make these theories clear, it will be necessary to refer for a moment to the histogenesis of the cellular covering of the chorionic villi.

In June last I demonstrated to the Society the fact that young chorionic villi possess a double covering,—the superficial layer, consisting of a multinucleated plasmodium, in which no cell outlines could be distinguished; and a deep layer of distinct cells with definite outlines. The histogenesis of these two layers, it was stated, had been a subject for great dispute, and the question did not at present admit of final settlement; but the most probable view seemed to be that the plasmodium represented this fœtal epiblast, and the cellular layer was merely a specialised stratum of the connective-tissue corpuscles of the stroma. I may, perhaps, be allowed to quote the following passage from my recent paper on "The Development of the Placenta." *

"Several observers appear to have proved that in the dog, cat, and mouse the superficial (plasmodial) layer is in reality a maternal tissue. They trace the formation in the decidua of masses of deeply staining multinucleated protoplasm, which they have named the syncytium. These plasmodia occur as isolated masses or as large areas or tracts, and appear to be formed mainly from the superficial and glandular epithelium. Their characters are identical with those of the superficial layer of the chorionic epithelium, and the syncytium may be traced passing in direct continuity from the decidua to the surface of the villi. These observers, therefore, term the superficial layer the chorionic syncytium, and regard it as a maternal structure.

"The only observers who have attempted to prove a similar origin of the superficial layer in the human placenta are Kossmann and Merttens. Merttens' observations must, however, be regarded as extremely unsatis-

* 'Journal of Path. and Bact.,' January, 1896.

factory. They were made upon a sixteen days' ovum obtained by curetting from a patient suspected of malignant disease of the uterus, who had suffered for some time from a profuse discharge. Kossmann's observations therefore stand alone."

"And it must be remembered, moreover, that the part played by the superficial layer in the formation of new villi is one of the strongest arguments in favour of the view that it is a fœtal, not a maternal structure. It seems impossible to conceive of a tissue of maternal origin taking the initial and fundamental steps in the development of new villi from parent stems. Much greater importance must in any case be allowed to facts such as these, than to analogies drawn from the region of comparative anatomy."

A corollary of the syncytial theory is that the deep cellular layer of the villi represents the fœtal ectoderm. This must of necessity follow if the plasmodial layer be maternal, for the epiblast layer must be represented somewhere. There is, however, no direct evidence in favour of this view, and several reasons might be urged against it. Williams and Marchand accept the syncytial theory, and when they say that they find syncytial structures in these growths they mean that they find a tissue derived from the serotina, and forming an important part of the structure of the placenta; a tissue, further, which is peculiar to the uterus, and developed in no other part of the body. According to Marchand the second group of elements composing these tumours, the polymorphous cells, are derived from the deep ectodermal layer of the villi; they are therefore composed entirely of placental elements, partly fœtal and partly maternal in origin. Williams leaves the question of the histogenesis of the polymorphous cells in his tumour an open one.

It must be remembered that neither of these observers has attempted to demonstrate the transition from placental villi to the structures composing these tumours. That important link in the evidence is entirely wanting

Neither is there any evidence given that proliferation of the uterine epithelium plays any part in the development of these tumours; in two of the three cases the only definite change in the mucosa was sloughing over the necrotic area of the growth. The theory, therefore, rests entirely upon the microscopic characters of the plasmodia and the cells.

Upon the nature and arrangement of the plasmodial structures both observers rely chiefly for support for their theory. Of course plasmodia have been proved to occur with considerable frequency in sarcomatous growths in many parts of the body, but the arrangement of plasmodia in a reticulum certainly seems peculiar. However, it is not at all clear from the drawings and the descriptions that they are not actually formed by fusion of tracts of cells belonging to the second group of structures. Both writers agree that there are many transition forms between the two, and they figure individual cells in the act of fusion with plasmodial masses. This admission, it seems to me, weakens the whole theory, for there is absolutely nothing about the cellular elements by which they can be certainly distinguished from sarcomatous cells. If the plasmodia are merely masses of fused cells, then the syncytial theory is quite superfluous; the growths are nothing different from sarcomata.

It is evident that the present theory of "deciduoma malignum" differs widely from that of the observer who first introduced the term. His view was that the growths were composed of decidual elements; the present theory is that they are composed of elements partly fœtal and partly maternal in origin. The later development certainly seems to be inadequately supported by facts, and we are, I think, justified in asking that if this theory is to become credible two points must be established beyond doubt: (1) the connection of the growth with a preceding gestation; (2) its development from structures which may be definitely recognised as placental relics.

Addendum to Paper on Deciduoma Malignum.

By T. W. Eden, M.D., M.R.C.P.

Since sending in my paper to the Society I have had an opportunity, through the kindness of Dr. Kanthack, of examining a number of sections of secondary growths from a case of sarcoma of the testis. The examination of these sections has convinced me that the appearances supposed to be characteristic of deciduoma malignum may in reality be found in rapidly growing sarcomata from other parts of the body.

I am able to show to the Society sections of two of the secondary growths in this case, one from the liver and one from a lymphatic gland. The greater part of these growths is made up of masses of round cells and very large extravasations of blood, with extensive deposits of fibrin; red blood-cells are also found scattered among the tissues in all parts. Lying amidst the round cells are numerous plasmodial masses, which show almost all the points laid down by writers on deciduoma malignum as characteristic of the "syncytium." They are masses of nucleated protoplasm, irregular in shape, varying greatly in size and containing numerous deeply staining nuclei, arranged irregularly, but mostly in the centre. They contain numerous vacuoles, and some of these contain red blood-cells, which appear to have entered them from surrounding hæmorrhages. Many of the masses are obviously formed by fusion of clusters of the round sarcoma cells, and the process of fusion can be distinctly traced.

The syncytial theory seems, therefore, entirely unnecessary to account for the presence of similar plasmodial masses in malignant uterine growths. There can be little doubt that the great majority of the cases of so-called deciduoma malignum ought really to be regarded as rapidly growing sarcomata, and classed as such.

MAY 6TH, 1896.

F. H. CHAMPNEYS, M.A., M.D., President, in the Chair.

Present—46 Fellows and 10 visitors.

Books were presented by Sir H. W. Acland, Mr. Doran, the Editors of the 'King's College Hospital Reports,' La Société des Sciences Médicales de Lyon, Society of the New York Hospital, Dr. Allchin, and Mr. Bland Sutton.

Arthur Corrie Keep, M.D., C.M.Edin., and J. Hillier Chittenden, L.R.C.P.Lond., were admitted Fellows of the Society.

The following gentlemen were elected Fellows of the Society :—Louis J. E. Carré, M.D. ; Rolf Creasy, L.R.C.P. (Windlesham) ; J. Lockhart Downes, M.B., C.M.Edin. ; Frank Edward Easton, L.R.C.P.Lond. ; W. Campbell McDonnell, L.R.C.P.Lond. ; A. Lyons, M.B.Lond. (Thames Ditton) ; and Patrick Fraser MacGregor, M.B.

The following gentlemen were proposed for election :—Frank Belben, M.B., F.R.C.S. ; and James Keogh Murphy, L.R.C.P. (Kilgobbin, Ireland).

———

TWO UTERI REMOVED BY VAGINAL HYSTERECTOMY FOR CANCER OF THE CERVIX, THE DISEASE BEING APPARENTLY AT THE SAME STAGE IN EACH.

Shown by A. H. N. Lewers, M.D.

Dr. Lewers showed these specimens. In No. 1 recurrence took place within three months. In No. 2 no recurrence has taken place, though more than twelve months have elapsed since the operation. He thought those present would agree that in both cases the disease seemed to be equally advanced, so far as could be ascertained by inspection. The point of interest in them was that the after history was so different. In the one recurrence took place almost immediately, while in the other more than a year had elapsed since the operation, and the patient was perfectly well. Dr. Lewers had examined her quite recently. These cases illustrated the difficulty of deciding, in certain cases, as to the desirability of operating. In doubtful cases, so long as the disease seemed to be limited to the uterus, he thought it better to operate.

CYSTIC MYOMA OF UTERUS WEIGHING OVER FIFTEEN POUNDS.

Shown by Alban Doran, F.R.C.S.

Mr. Doran observed that a large uterine fibroid was a form of tumour which could usually be diagnosed without difficulty. In this case it was otherwise. The patient was forty-nine, short and robust. For some time she had been under the care of Dr. Grier, of Mevagissey, for gall-stone colic, and Mr. Doran was

shown several biliary calculi which she had passed. A large tumour filled the right side of the abdomen, and was in close relation to the liver. There was resonance all over the left side, where no tumour could be felt under chloroform. The parietes between the umbilicus and pubes were hardly stretched; the measurement was 7½ inches, whilst above the navel the tumour pressed on the abdominal walls, and a space of 10½ inches intervened between the ensiform cartilage and umbilicus. The girth at the umbilical level was 48 inches. The uterus was to a certain extent moveable, but did not move when the tumour was pushed sideways. Though it was thought that a tumour of pelvic origin was possible, it seemed very probable that the growth might be connected with the liver. A Langenbuch's incision was therefore made on the right side, but though the tumour adhered to the parietes near the liver it was found to arise from the pelvis by a very thick and long pedicle, which was simply the cervix and lower part of the uterus greatly elongated. On extruding the mass on the right side through a median incision, a second lobe slipped out from the left side of the abdomen behind intestine and extremely thick omentum. The serre-nœud was applied without much difficulty, and the great bilobed tumour cut away. It was a soft cystic fibroid, the solid part weighing 15 lbs. 3 oz. The patient made a good recovery.

Mr. Malcolm said he had seen the patient with Mr. Doran, and taking into consideration the fact that a gall-stone had been passed by the patient and seen by Mr. Doran, the physical signs led him (the speaker) to form the opinion that the tumour was probably an enlarged gall-bladder. The objection to this diagnosis was that the tumour extended very low towards the pelvis without being tense. He had altogether failed to detect the tumour on the left side. The difficulty was due to the facts that the tumours did not extend into the pelvis, and that they were so very soft that they could not be detected through the intestines, which thickly covered them everywhere except in the region below the liver.

PLACENTA, CORD, FŒTUS, AND MEMBRANES.

Shown by Robert Wise, M.D.

Dr. Wise showed the placenta, cord, fœtus, and membranes from an abortion in the fifth month. The placenta contained infarcts. A section from one of these infarcts under the microscope was shown to be composed of placental tissue and blood-clot, the branching chorionic villi and decidual cells being well seen in the section.

Tarnier has recently stated that apoplectic infarcts of the placenta are often entirely independent of fibrous infarcts. The umbilical cord showed a false knot.

TWO SOLID OVARIAN TUMOURS.

Shown by J. D. Malcolm.

Mr. Malcolm showed two solid ovarian tumours of irregularly oval shape, and about the size of large oranges, which he had removed from the broad ligaments of a patient, thirty-five years of age, on October 21st, 1895. The right ovary consisted of an ordinary multilocular cystoma. The solid growth on this side was attached to the outer portion of the base of the cystoma, and extended very deeply into the broad ligament, from which it was with difficulty removed. On the left side the ovary appeared normal, except that the solid growth was attached to its outer end. It was, like the other, deeply buried in the broad ligament. There was about half a pint of fluid free in the peritoneal cavity. Microscopic sections showed the solid tumours to consist of an epithelial growth of a papillary type. The tumours had the appearance of being malignant both to the naked eye and under the microscope.

A LARGE SOLID OVARIAN TUMOUR.

Shown by J. D. Malcolm.

Mr. Malcolm showed a large solid ovarian tumour weighin g 8 lbs. 12 oz., which had been known to exist for eighteen months before its removal by operation on March 7th, 1896, when the patient was forty-five years of age. This growth had become firmly adherent to the anterior abdominal wall, to the left Fallopian tube, and to the bladder. There were about six pints of fluid free in the peritoneal cavity. Microscopically this tumour was a sarcoma of a myxomatous type, large areas of the growth having undergone a mucoid change, by which cysts had been formed in it.

A SOLID OVARIAN TUMOUR.

Shown by J. D. Malcolm.

Mr. Malcolm showed a solid ovarian tumour, the size of a small cocoa-nut, removed from a woman thirty-seven years of age on March 30th, 1896. The tumour had been deeply embedded in adhesions, but there was no fluid free in the peritoneum in this case. Mr. Targett had examined the specimen, and had found that it was a fibroma with patches of mucoid softening in it, but without any indication of malignancy. This and the tumours noted above were shown with a view to publishing the after-histories of the cases at a future date.

A SIMPLE MAIEUTIC FOR THE INDUCTION OF MISCARRIAGE OR PREMATURE LABOUR.

Shown by PETER HORROCKS, M.D.

THREE bags of different degrees of thickness were shown. No. 1 (Fig. 1) was so thin, that when fixed on

FIG. 1.

Smallest maieutic, natural size.

FIG. 2.

Maieutic fixed on the end of a catheter.

the end of a catheter it did not appreciably alter the thickness of the catheter. Hence if a No. 5 or No. 6 gum-elastic catheter were used, it could be introduced quite easily into the uterus at any stage of pregnancy, without any anæsthetic and without pain. It was passed beyond the internal os. By means of hydrostatic pres-

sure, through a funnel and india-rubber tubing, about 12 drachms of some solution were introduced into the bag. Tr. Iodi, two drachms to a pint of water, was perhaps the best solution to use. Many other solutions were mentioned. Pains began quickly, and the natural forces were set to work. The bag was expelled in a few hours, and then the amnion finished the dilatation in from twelve to thirty-six hours. In Fig. 3 the maieutic is seen *in situ*.

FIG. 3.

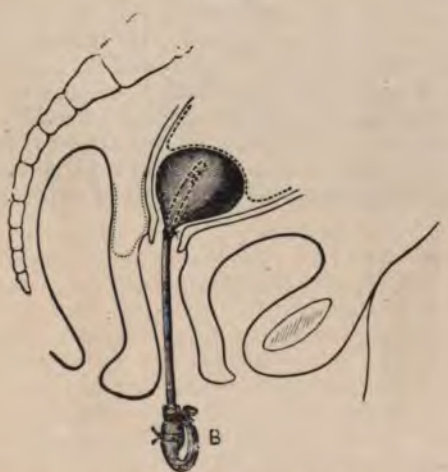

Maieutic in position with the tubing tied and cut short.

If the pains went off after the expulsion of No. 1 bag, No. 2 could be introduced, which would hold about 5 ounces of fluid. No. 3 could follow, holding about 10 ounces. In this way it was quite easy to get the uterus emptied without using the much stronger bag of Champetier de Ribes, and if done with all aseptic precautions it was perfectly safe.

Dr. HERMAN had used for inducing labour a small india-rubber bag, devised for the purpose by Mr. J. W. Taylor, of Birmingham (see 'Brit. Med. Journal,' Nov. 10, 1888), and found it answer

well. But this bag was only for inducing labour, not for also accelerating dilatation, like the bags now shown by Dr. Horrocks.

Mr. GANDY inquired of Dr. Horrocks whether he dilated the cervix previously to introducing the rubber ball, and if he passed it well into the cavity of the uterus.

The PRESIDENT said that he had, both at St. George's and at St. Bartholomew's Hospitals, been for many years in the habit of using the ordinary children's penny air-balls for inducing premature labour. The neck of the ball (which was quite well made) was tied on to a catheter; the catheter was connected with india-rubber tubing, and the ball could easily be distended, either by gravitation or by a syringe, to any desired size. It was well, before inserting it, to distend it to the size and tension desired, and then to measure the water which ran out on emptying it. This quantity could then be injected. He thought that a flaccid bag was better than one which was bound to be of a fixed size like those exhibited, as it was less likely to displace the presenting part, which would easily make the shape of a flaccid bag concavo-convex. He found it very efficient, it was always procurable, and he did not think there was any necessity for a special manufacture. It was easily introduced in the grip of a speculum forceps.

ADJOURNED DISCUSSION ON DECIDUOMA MALIGNUM.

Dr. A. A. Kanthack remarked that in all essential points he agreed with Dr. Eden's criticism. It was necessary to approach a question like this from the point of view not of the specialist, but of the general pathologist. He would therefore criticise the various theories and cases recorded, and more especially the cases exhibited at the Society, from his standpoint. It was evident that the "deciduoma" is a malignant tumour, all agreed upon that; but some traced its origin to decidual cells, others to syncytial masses, and at least one other authority even to the connective tissue of the chorionic villi. On analysing the published accounts it would be found that according to their nature these deciduomas were either sarcomas, in which case they were said to have developed from the decidual cells, or carcinomas owing their origin to the syncytium. It was evident, then, that "deciduoma," apart from its hybrid nature, was a bad term, because it was not inclusive. He wished to suggest to the seekers of new names two other names to cover the carcinomas, viz. "syncytioma" or "trophoblastoma." He himself firmly believed that the deciduoma was a typical sarcoma, characterised by features common to many forms of sarcoma. It was certain that most of the deciduomas described or shown were sarcomas. He agreed with Dr. Eden that Dr. Williams' specimen, described in the 'Johns Hopkins Hospital Reports,' was an undoubted sarcoma, and certainly not a carcinoma. Dr. Williams himself did not seem quite satisfied about it being a carcinoma, yet, in order to prove it to be a deciduoma, he was compelled to argue a sarcoma into a carcinoma. Prof. Spencer had described his case as a deciduoma consisting chiefly of syncytial masses, and he laid great stress on the growth in the lung. The latter was secondary to the uterine growth and certainly a sarcoma, and not even an extraordinary sarcoma. The uterine growths were curious, but presented nothing incompatible with sarcomas met with in other regions of the body. Prof. Spencer himself, although insisting on the syncytial nature of these growths, agreed with him to call them sarcomas—a serious admission from a believer in deciduomas. Dr. Rutherford Morison's case no one would consider anything else than a sarcoma containing in certain situations large plasmodial cells (syncytial masses). Dr. Hebb's

specimen also was acknowledged to be a sarcoma, the secondary growths in the lungs showing so-called syncytial masses. All these specimens are sarcomas, characterised by the presence of syncytial masses, or, according to the same observers, developed from syncytium. The plasmodial syncytial masses were said to be characterised by these three points: (*a*) absence of cell outline; (*b*) deeply staining nuclei; (*c*) vacuolation. Now Dr. Kanthack maintained that similar plasmodial masses, formed by cell fusion, occurred in many rapidly growing sarcomas, and that it was illegitimate to argue from morphological analogy that these plasmodial masses were derived from syncytium. He had shown with Dr. Eden specimens to illustrate this, sections of a sarcoma of the testis with secondary hæmorrhagic deposits in the liver, spleen, lymphatic glands, where decidua and syncytium could be excluded. But supposing these plasmodial masses were syncytial in nature, some authors assumed that syncytium is metamorphosed uterine epithelium, and it followed that, this being so, one would have a sarcoma developed from maternal epithelium —which was absurd. Others assumed—and there was but little room for doubt that this was the correct view—that syncytium is epithelial tissue of fœtal origin, fœtal ectoderm; thus one would have a sarcoma developed from fœtal epithelium—which was equally absurd. Prof. Spencer did not recognise this *reductio ad absurdum*, and described his specimen as a sarcoma, which of course it was; Dr. Williams did recognise the *reductio*, and argued a true sarcoma into a carcinoma developed from both maternal and fœtal epithelium. But even if his view were correct, what evidence was there that a carcinoma could ever develop from fœtal epiblast? Such pathological views were too revolutionary to be acceptable without a protest. At any rate, a sarcoma containing plasmodial masses could not have developed from epithelial syncytium.

Some writers had described their specimens as sarcomas developed from decidual cells. The latter were connective-tissue cells changed under the unknown proliferative stimulus of pregnancy. As Dr. Eden had well said, the decidual cell was not characteristic of pregnancy, although the decidua was. Connective-tissue cells could assume the shapes and sizes of decidual cells under proliferative stimuli other than impregnation, *e. g.* under the stimulus which was at work in a sarcomatous rejuvenescence. Cells exactly like decidual cells could be found in many sarcomas, and large-celled sarcomas could appear in the uterus quite independently of pregnancy. He had recently examined such a case for Dr. Champneys (a woman aged fifty-three) which clearly showed cells exactly like decidual cells. Again, he had seen individual connective-tissue cells in the uterine mucous membrane, which had become very large, and were almost decidual in character, when the lesion was a chronic inflammation or a membranous

dysmenorrhœa. Since a decidual cell did not differ from hypertrophied connective-tissue cells, as met with in many forms of sarcoma, it was necessary before calling a large-celled sarcoma a deciduoma that (1) pregnancy must be rigorously proved to have existed (this condition has remained unfulfilled in many cases); (2) the pregnancy must have existed before the sarcoma appeared. He thought that in some cases, if not in many, it might be assumed that the sarcoma had existed before the pregnancy, and had been the cause of the abortion or hydatiform degeneration, the pregnancy in its turn having acted as a proliferative stimulus on the growth of the sarcoma.

When Gottschalk assumed that the sarcoma had developed from fœtal connective tissue, it might be asked whether there could be such a thing as a congenital sarcoma; and again, why were there no metastatic deposits in the fœtus? Dr. Williams did not accept Gottschalk's view, and considers the tumour described by the latter to be a syncytial cancer, or possibly a carcinoma derived from Langhans's layer, *i. e.* a carcinoma developed from fœtal ectoderm—which was absurd.

This analysis, therefore, forced them on all sides into untenable absurdities. The views advocated involved a serious *petitio principii.* Why should not the malignant disease have been the cause of an abortion where the latter had existed? Dr. Spencer asked the Society to believe that the growth in the cervix was secondary to that in the fundus at the placental site; there was no evidence for this view, for all he knew the growth might have begun in the cervix, *i. e.* in the region where syncytium was not found. There was nothing surprising in the fact that pregnancy and sarcoma should coincide. Some observers, in order to reconcile their speculations in embryology with their pathological interpretations, had been forced to fall back upon the combination of sarcoma and carcinoma, on the sarcoma carcinomatodes—a most dangerous ground, on which the modern pathologist feared to tread. There was no proof that the deciduoma malignum was anything special or specific; in most cases it was a sarcoma differing in nothing from a sarcoma elsewhere, or possibly modified simply by the concurrent stimulus of pregnancy; there was no proof that pregnancy, abortion, or the retention of decidua or chorionic villi had caused the malignant growth. He saw no reason for accepting a novelty based partly on insufficient embryological knowledge and unsound pathological deductions, or partly suggested by specialistic prejudice.

Dr. J. C. Webster expressed his pleasure at being able to attend this meeting of the Society. As he had seen no specimens of the so-called deciduoma malignum save those shown by Mr. Rutherford Morrison and Dr. Spencer, he felt justified in limiting his remarks to certain points which he had noticed in his examination of various published cases, referring in particular to

some embryological considerations in which he was particularly interested. Like many others in this country, he had been much surprised at the appearance of this new term made in Germany. That the disease was of malignant nature seemed evident. Apart from the novelty of the name, he did not think there was anything in the clinical symptoms which had not been before recognised in cases of primary malignant disease of the uterus. Nor was the connection of malignancy with pregnancy or the puerperium anything unknown. The startling element in the new disease seemed to him to lie in the pathology and ætiology of the condition, or rather in the discordant views expressed by writers. Thus the following statements are made as to the nature of the new growth, viz. that it is sarcomatous, that it is carcinomatous, that it is made up of sarcomatous and carcinomatous tissue.

As to the tissue of origin of the new growth the following are mentioned :—Maternal—epithelial elements of mucosa; connective-tissue elements of mucosa; muscle of uterine wall. Fœtal—epiblastic elements of villi; mesoblastic elements of villi; combined epiblastic and mesoblastic elements of villi. Maternal and fœtal elements combined.

It is very evident that speculation has been rampant in the minds of writers, that so many varying statements could be made in reference to the newly described disease, or else we would need to admit the existence of a good many different varieties of the affection. Taking together all the cases which have been published, from the microscopic appearances described, three distinct types are to be made out :

1. In some the tumour and metastasis is composed of cells, sarcomatous or carcinomatous in shape.

2. Others are composed of cells as in No. 1, along with masses of plasmodial tissue like the syncytium found normally in connection with the placenta.

3. Others are made up of the above constituents with the addition of villous structures exactly resembling the villi of the placenta as they are found normally, or in the condition known as vesicular mole.

In regard to the first type, of which Sänger's first described specimen is an example, the following remarks may be made. It is difficult to decide as to whether certain new growths in the uterine mucosa are carcinomatous or sarcomatous. Gusserow, Hegar, and Klebs pointed this out many years ago. Moreover there is no doubt that they may occur together. According to Virchow and Klebs, mixed malignant growths occur together in the uterine mucosa more frequently than in any other tissue of the body. When these growths occur in a mucosa which is under the influence of a recent or present gestation the difficulty of determining the exact nature of microscopic appearances is great. One who is well accustomed to the varied conditions found nor-

mally in the mucosa during pregnancy and the puerperium is best able to study these conditions.

Another question of great interest and importance is this. Is it probable that sarcomatous growth from the connective-tissue elements of the uterine mucosa will tend to show a large cell formation under the influence of a past or present gestation? This seems very likely. Apart from this influence there is no such tendency in sarcoma of the uterus so far as is known. The well-known rapidly growing uterine sarcoma, unconnected with pregnancy, is of the small round-cell type.

There is no proof that cells of decidual structure can occur in the uterine mucosa apart from the past or present influence of gestation. Ruge described them in a case of endometritis, and Overlach in a case of phosphorus poisoning, but Uyder showed that the possibility of the occurence of a past abortion could not be excluded. There is nothing remarkable, therefore, in the fact that malignant growths with large cells should be found in the uterine mucosa when the genetic influence cannot be excluded. In regard to the second type there has been much speculation, These tumours and their metastases are composed of syncytium, along with other cells of doubtful nature.

The following statements are made as to their origin:—1. Maternal entirely: connective-tissue elements, or both connective tissue and epithelium; 2, fœtal entirely: epiblast of villi, or both epiblast and mesoblast; 3, maternal and fœtal.

Leaving out of account the cells of doubtful nature, the syncytium is worthy of some notice. Undoubtedly, in the published cases, this structure, as represented in the drawings of the tumour tissue, bears great resemblance to the syncytium found in connection with the chorion and decidua in uterine and in ectopic pregnancy.

The nature of the syncytium of pregnancy has been long discussed. Some state it to be formed from the epithelium of the uterine mucosa; others say that it is a fœtal structure, epiblastic in nature, the outermost layer, in fact, of the early ovum. The fœtal origin cannot now be denied. It has been clearly pointed out in different manuals, especially by van Beneden, Hubrecht, and Dewal. The importance of the labour of these authorities in the investigation of this matter cannot be too highly emphasised. Among some recent German workers their work has received very scant attention. The maternal origin of the syncytium was advocated in the days when there was no such careful technique in microtomy as is found now-a-days, and it is hard to break away from traditional views. We are greatly indebted to those who have used the hand-lens and dissecting knife, but the study of delicate embryological tissues must be carried on with more refined methods.

Moreover in studying these difficult matters it is essential to

examine serial sections from a series of specimens of different ages. The study of a detached specimen is of very little use unless the comparative method be adopted.

On such an occasion it would occupy too much time to give all the reasons for considering the syncytium of pregnancy to be of fœtal origin. These Dr. Webster hopes to publish separately soon, when he brings forward the results of his investigations in this region of human embryology, which he has been carrying on for six years. One important point may be noted which is worthy of consideration by those who believe in the maternal origin, viz. that, whereas the decidua serotina and the vera undergo the same early changes, syncytium is found on and in the former at a very early stage, but never in relation to the vera until the chorion læve has touched it. At the sixth week of pregnancy, for example, syncytial masses are found on the serotina, and in its substance. At the same period the vera is entirely free of this tissue, its epithelium being only flattened or broken up, no appearance of plasmodial alteration being found.

There can be no doubt that from the very beginning the outer layer of the chorionic epiblast is of the nature of the syncytium. It early becomes applied to the decidua, with which it comes into contact. It can penetrate the substance of the serotina, even extending into the muscular part of the uterine wall. It is probably largely instrumental in destroying the degenerating remains of the epithelium originally covering the serotina, and it can penetrate maternal vessels.

If, then, it can be established that the syncytium formed in connection with these malignant growths is the same as that of pregnancy, and if it be also found in metastatic growths, it must be admitted that, whatever be the origin of the other cells in the tumours, the syncytial part is due to the malignant development of fœtal epiblast parasitic on the uterine mucosa resulting from the product of conception.

However, another question is to be settled before such a conclusion is formed, viz. to what extent does plasmodial formation take place in connection with the growth of sarcomata entirely unconnected with the influence of pregnancy? Dr. Kanthack states that this change is fairly common in sarcomata of different tissues of the body. This is an important point to establish in order to discredit a belief in the development of these tumours in the uterus from the syncytium of pregnancy.

Dr. W. E. Fothergill said that most of the points in the pathology and literature of the subject on which he had any definite opinion had been referred to by Drs. Kanthack and Clarence Webster, with whom he completely agreed. He would like, however, to put in a broad and simple way the points in question. Of the twenty-eight or nine authors with whose works he was acquainted, few agreed in opinion, and still fewer used

the same nomenclature. Some of them did not make it clear what they meant by cancer and sarcoma, and others did not even make any definite distinctions between mother and fœtus. There are doubtless four tissues from which it is logically possible that the growths in question can arise, namely, maternal—decidua, (1) connective, (2) epithelial; fœtal—chorion, (3) epithelial, (4) connective. Now malignant new growths arising from (1) the decidual cells—that is, from decidual connective—are sarcoma uteri, and those arising from (2) maternal epithelium are carcinoma uteri (or epithelioma or adenoma, as the case may be). Whether caused by pregnancy or any other circumstance, most of the growths described are one or other of these or a mixture of the two. There is no excuse for applying a new name to these, and the only result of their publication should be to attract attention to pregnancy as a factor, somewhat overlooked, in the causation of malignant change in the uterus. Chiari, in 1877, described cases of this nature, doubtless correctly, as carcinoma uteri. To say now that these were cases of "deciduoma malignum" is supererogation. So much for growths of maternal origin. But if it can be proved that (3) fœtal epithelium or epiblast can live and grow within the maternal tissues, we doubtless have to do with a new pathological entity. Marchand raises hopes of a simplification when he says that all the forms recently described and variously named are derived from epithelium; but in another place he plunges again into confusion by dividing this epithelium into two kinds, (*a*) syncytium and (*b*) the epiblast of the chorion. Now after the work of Hart and Gulland, after what Dr. Webster has said this evening, and after the recent work of Dr. Merttens, no one can doubt that the syncytium is fœtal epiblast, and that Marchand's classes (*a*) and (*b*) are all identical in origin. One observer only—Gottschalk—has stated that (4) fœtal connective is concerned in the growths under discussion, and as he also includes (1) maternal connective and (2) maternal epithelium, he does not add much to our knowledge. It is safe to ignore (4) fœtal connective as an origin for these growths, so that the question is reduced to this. Can fœtal epiblast—call it syncytium or anything else—form new growths in the uterus and produce metastatic growths elsewhere? At present there is no proof that this can occur. Ordinary placental relics do not live after the death of the fœtus. In ectopic pregnancy it has been shown that growth of the placenta after the death of the fœtus does not occur. Vesicular degeneration of the chorion is the most suggestive condition, and it is in connection with this that the required proof is most likely to be found. When it is found, the new "chorionic carcinoma" will be welcomed, but not before. When it is recognised, it certainly will not be under the deceptive and unnecessary misnomer, "deciduoma malignum."

Dr. Lewers referred to a case of circumscribed sarcoma of the

uterus which he had recorded in the Society's 'Transactions' (vol. xxviii, p. 78) ten years ago. He showed the specimen again on this occasion (see Plate VI), as it presented some points of resemblance to that in Dr. Spencer's case. Thus there were growths in the body of the uterus, and also partly in the body and partly in the cervix. There were also numerous secondary growths in the lungs, and two sarcomatous nodules in the vagina. Dr. Lewers suggested that if a patient in whom the uterus was affected with circumscribed sarcoma, as in the specimen shown, should become pregnant, there would be a very close resemblance between the case, perhaps even amounting to identity, and cases described as deciduoma malignum. There was no intrinsic improbability in the suggestion that a patient with a sarcoma of the uterus might become pregnant, provided, as in the specimen shown, the endometrium was not involved.

Mr. Bland Sutton said he considered the subject to be one of great importance, and had carefully considered it from the point of view of our knowledge concerning tumours in general. In accordance with the current classification, the tumour to which Sänger and Pfeiffer had independently drawn attention was clearly a malignant tumour of the connective-tissue type, and this being the case it should rank as a species of the genus sarcoma; it certainly corresponded clinically and pathologically with this genus.

Although sarcoma is a generic term for malignant tumours arising in connective tissue, it must be borne in mind that whilst connective tissue is ubiquitous it is widely modified in different regions of the body. For example, the neuroglia of the brain and the delicate sustentacular framework of the retina form striking contrasts to periosteum and the tough fascial sheath of muscles. A long and close study of the clinical and histologic features of sarcomata teaches that each species and variety is strangely modified by the organ in which it arises, and that the simple classification founded on the shape of the component cells is totally inadequate. Virchow hit upon a very important fact when he found that every tumour had a physiological prototype, and so true is this that we know for absolute certainty that a glioma does not arise primarily in the uterus, or a myoma in the shaft of a long bone, nor an odontome in the optic thalamus. So useful is Virchow's great generalisation that if one were asked to enumerate the tumours likely to be expected in a particular organ, it would be merely necessary to make a list of the various tissues composing it in order to answer the question. Take, for instance, the uterus, which contains muscle-cells held together by connective tissue, and permeated by blood and lymph vessels. Its walls are also occasionally traversed by a functionless (Gartner's) duct. The uterine cavity is lined with mucous membrane with characteristic glands embedded in a peculiar

connective-tissue stroma, which is liable to remarkable changes, which are without parallel in the body, whereby it forms a curious membrane known as a decidua. A very ordinary knowledge of the histologic characters of tumours would lead the pathologist to believe that the uterus would be the seat of myoma, adenoma, carcinoma, cysts from Gartner's ducts, and at least two species of sarcomata, one arising in the coarse connective tissue of the uterine walls, the other in the stroma of the endometrium. A sarcoma arising in the wall of the uterus would be of the round- or the spindle-celled species, but one arising in the endometrium would contain round and spindle cells; but if the sarcoma started to grow at a time when the decidua was in a high state of development, as during the first three months following the formation of an oösperm, we should expect decidual cells to be in a majority.

When Mr. Sutton first read the careful records furnished by Sänger and Pfeiffer this was the way in which he considered the matter, and the evidence these two observers adduced satisfied him that, out of the common forms of malignant disease of the uterus, they had clearly identified a species distinct in its histology and clinical course; hence, in writing an article on "Tumours" for Treves' 'Surgery,' he felt justified in inserting *Deciduoma* as a new species of sarcoma.

Of course he had kept careful watch with the hope of meeting a case of deciduoma, but so far unsuccessfully; and it seems probable that true examples of this tumour are rare, for a study of many cases recorded as deciduomata has served to convince him that some at least do not deserve the term, but this in no way detracts from the merit of Sänger and Pfeiffer's important observations.

It may be asked, and with reason, why should a tumour with apparently such striking features remain so long undetected? The question is easy to answer. It may perhaps seem presumptuous, but he made bold to say it is true, that there are not six members present to-night so familiar with the microscopic features of uterine deciduæ that they would be able to recognise them with the same facility that they would fine sections of bone, muscle, or nerve! Herein lay much of the difficulty and doubt which encompass the whole question.

This discussion will have good results: some of the able workers which this Society now boasts will devote their energy to a complete and routine study of the histology of malignant tumours of the uterus; work done in this way will settle the question more thoroughly than a long series of academic disputations.

Mr. Sutton's own views on this question are simple. He is of opinion that a deciduoma is a sarcoma arising in decidual tissue. Concerning other varieties supposed to originate in chorionic villi, he preferred to maintain an attitude of active scepticism. Their

occurrence was possible, but their existence had not as yet been satisfactorily demonstrated.

Mr. Alban Doran said that he had concluded before the beginning that the matter was at an end, and he saw he had been right, for it was not half over yet. So said Lord Castlereagh of another disputed question where too much had been taken for granted by those who had advanced it; and his Irish paradox applied to the deciduoma malignum theory. Mr. Doran spoke for Mr. Rutherford Morison, and felt at least sure that Mr. Morison's case was the disease which the Germans had termed deciduoma malignum, whatever the correct interpretation of the malady might be. Coincidence had not been taken into account. Millions of young women bore children; simple sarcoma of the uterus was a recognised and a very rare disease, which occurred in young subjects; therefore it was natural that simple sarcoma should occasionally occur in young women after gestation. The normal process very possibly influenced the development of the neoplasm. Hence deciduoma malignum might simply mean sarcoma growing with unusual rapidity on account of recent gestation. There was one reason, however, at least, why we must not absolutely deny the possibility of the true decidua-celled sarcoma described by German authorities. Apfelstedt and Aschoff described quite recently ('Archiv f. Gynäk.,' vol. l, 1896) a case of secondary deposit in the labium laid open three months after the delivery of a vesicular mole. The tumour contained the characteristic structures which made up a mole of that kind. Decidual tissue was not more complicated; its diffusion by metastasis was therefore conceivable. Undoubtedly, on the other hand, there had been too much enthusiasm abroad about deciduoma malignum, and its existence had been too often assumed. In the 'Centralblatt für Gynäkologie' for May 2nd, 1896, two observers scrutinised a report of a patient aged thirty-eight, who died, six months after delivery, of malignant disease of the uterus over twenty years ago; there were metastases in the lungs, &c. The original report recorded this case as an example of epithelial cancer, yet the authors of the later memoir declared it to be true deciduoma malignum. They proceeded to a case of their own where a vesicular mole was delivered, and one year and eleven months later the uterus was removed for a bleeding tumour. The patient, in good health six months after the operation, was forty-two. The tumour was described as deciduoma malignum. The age of the patient was against the existence of any tumour of the sarcoma type. Apfelstedt's secondary vesicular-mole tissue tumour occurred, it was true, in a woman of the same age, but we were not certain of the true character of this remarkable tumour. In the President's (Dr. Champneys') case of hydatid mole with metastases in the lungs ('Practitioner,' January, 1896) the patient was only eighteen. The Obstetrical Society,

Mr. Doran concluded, could not consider that the existence of this new disease as distinct from sarcoma had been soundly proven.

The PRESIDENT said that it had been a pleasure to see at the meeting so many distinguished visitors, and to hear them speak. He did not doubt that the debate, which had brought much special experience, tempered with general knowledge and a logical spirit, to bear upon the subject, would prove useful. Without committing himself to the numerical statement of Mr. Bland Sutton—that those who possessed the necessary knowledge at this meeting were less than six—he quite agreed with him in principle, that statements on so difficult an organ as the placenta, even if healthy, were to be received with great caution unless the competence and good judgment of the observer were well known. In the pathology of the placenta this was still more true. In reading the cases which had been reported he often wondered, as in the case of any other "new" disease, what such cases had been called before. He supposed, but was not sure, that most of them would have been regarded as forms of cancer or sarcoma. It was interesting to hear that German observers were ignoring English, Dutch, and French observers. It was only an instance of "Continental insularity;" the least insular portion of Europe in this respect was the British Isles. The conclusion of the debate seemed to be that the question is far from being settled, and that it is yet too soon to add a new disease to the list.

Dr. HERBERT SPENCER, in reply, said that the case he had recorded was a well-marked example of the disease known as deciduoma malignum. While expressing his opinion that it *appeared* to belong to the sarcomata, he had not discussed the pathogeny of the disease, believing that further research was necessary in the directions indicated in his paper before this could be finally settled. In the case of a disease which the most distinguished pathologists hesitated whether to call a sarcoma or a carcinoma dogmatic statements should, he thought, be avoided. Dr. Kanthack recognised the difficulty of distinguishing between these two forms of malignant growth in the peritoneum, and he appears to have distinguished between sarcoma and decidual tissue in the case he quotes by means of the age of the patient, fifty-three, which excluded pregnancy. Dr. Spencer did not know whether there were other facts to guide Dr. Kanthack in coming to this conclusion, but the mere fact of the patient being fifty-three years old would not exclude pregnancy. Dr. Kanthack, in assuming that the syncytium of the chorionic villus is epiblastic, had himself committed a *petitio principii* of which he accused others. It was unnecessary to criticise the opinion that the sarcoma preceded the pregnancy until it was stated on what the opinion was based; he (Dr. Spencer) knew of no facts in support of it, while the history of the cases, and the well-known fact that primary

carcinoma of the body of the uterus is practically unknown in association with pregnancy, were strong evidence against it. Whether the disease belonged to the sarcomata or the carcinomata was a matter of slight importance; so also was the name by which it was designated. The really important question was whether we had to deal with an ordinary malignant growth in the uterus, or whether we had to do with a malignant growth which developed from the products of conception (whether fœtal or maternal). He (Dr. Spencer) thought all the facts were in favour of this latter view. He had notes of forty cases of this disease, in every one of which there was a history of antecedent or coincident pregnancy (with one doubtful exception), and in eighteen (45 per cent.) of which the pregnancy terminated by the passage of a hydatid mole. In every case the growth affected the body of the uterus (in two cases the cervix as well). In one case (Apfelstedt and Aschoff's) a typical hydatid mole was found in a metastasis in the labium; in another (Müller's) a row of cystic tumours formed in the vaginal wall. In most of these forty cases the appearance presented by the syncytium was characteristic: it was in the case he had recorded most remarkable, forming the principal part of the tumour, and it was entirely different from anything he had ever seen in any other uterine growth. To overlook these important and striking facts, and to deny the existence of the disease because it was at variance with the preconceived ideas of pathologists, was not a philosophic attitude to adopt. Let the critics bring forward one case of sarcoma of the uterus occurring in a patient outside the child-bearing period of life and showing the syncytium, it would then be time enough to consider the question of mere coincidence. In reply to Dr. Kanthack's suggestion that the growth in the case recorded might have been primary in the cervix and secondary in the body of the uterus, he (Dr. Spencer) thought that the greater extent of the growth in the body, the fact that nothing abnormal was noticed in the cervix during labour or in the puerperium, and that masses were spontaneously passed twenty-five days after labour, and were also subsequently artificially removed from the body of the uterus, sufficiently negatived that suggestion.

Dr. Eden said he was very glad to find that Dr. Kanthack and Dr. Clarence Webster shared the doubts he had expressed as to the identity of the plasmodial masses found in cases of "deciduoma malignum" with the placental syncytium. The question of identity depended upon one point, viz. whether the placental syncytium possessed any specific characters by which it could be distinguished from masses of nucleated protoplasm derived from different sources. He believed that it did not possess any such characters, and considered, therefore, that the plasmodial masses found in these growths could not be identified as syncytium merely from their microscopic appearances. There

seemed to be no good reason why the great majority of the cases should not be classified as sarcomata. But in three instances the new growth was asserted to be composed mainly or largely of proliferating chorionic villi. One of these cases, recorded by Apfelstadt and Aschoff, was a very remarkable one. It was a case of malignant disease of the uterus following the spontaneous evacuation of a vesicular mole; both the primary tumour and a metastasis in the labium majus were found to consist of clusters of vesicles having the structure typical of the vesicular or hydatidiform mole. He believed this case to be unique, and in the absence of confirmatory observations it must be received with some reserve. But if experience should prove that malignant growths, consisting of proliferating placental villi, may arise in the uterus, and spread by the ordinary channels of metastasis, such tumours would form a distinct addition to our pathology. It was obvious, however, that the term "deciduoma malignum" was quite an unsuitable designation for new growths composed of placental villi.

Report of Committee on Mr. Rutherford Morison's and Dr. Spencer's specimens of Deciduoma Malignum, and Mr. Malcolm's specimen of Sarcoma of the Uterus.

We, the undersigned, have met, and, after examining the specimens named above, have drawn up and signed the following report:

1. We are of opinion that these cases are sarcomata, and therefore of connective-tissue origin, and they contain plasmodia identical in characters with the so-called "syncytial masses" described by writers on deciduoma malignum. And the presumption is that they have arisen in maternal, not in fœtal tissues; but there is no definite evidence before us bearing upon this point.

2. The specimens are remarkable from a histological point of view for the presence in them of numbers of large cells and plasmodial masses. These elements, however, are by no means confined to cases of uterine sarcoma, but they may occur in sarcoma arising in other parts of the body. Sections of secondary growths in the liver and lymphatic glands, from a case of sarcoma of

the testis, containing precisely similar structures, were shown to the committee conjointly by Drs. Kanthack and Eden.

3. Secondary growths in Dr. Spencer's and Mr. Malcolm's cases showed the same character as the primary growth. There were no sections of secondary growth from Mr. Rutherford Morison's case.

We are of opinion that there is nothing in the histological characters of these specimens to justify the supposition that they are of decidual origin, and the term deciduoma malignum is therefore an inappropriate one.

A. A. KANTHACK.
J. BLAND SUTTON.
J. H. TARGETT.
HERBERT R. SPENCER.
ALBAN DORAN.
T. W. EDEN.
W. S. A. GRIFFITH, *Convener.*

We are of opinion also that the drawings of decidual tissue shown by Dr. Griffith should be added to the report of the committee.

NORMAL DECIDUA.

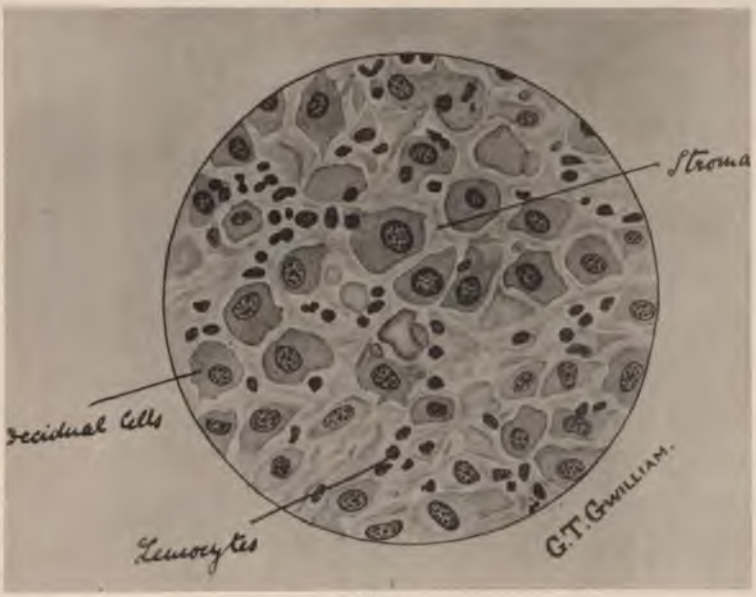

Fig. 1.

Fig. 2.

SECTION OF DECIDUAL CAST.

(See Vol. XXXVI, p. 335.)

JUNE 3RD, 1896.

F. H. CHAMPNEYS, M.A., M.D., President, in the Chair.

Present—38 Fellows and 1 visitor.

Dr. John Phillips presented the Weekly Epitome of Current Medical Literature, published in the 'British Medical Journal' from July to December, 1894.

Rolf Creasy, L.R.C.P.Lond. (Windlesham), and A. Lyons, M.B.Lond. (Thames Ditton), were declared admitted.

The following gentlemen were elected Fellows of the Society:—Frank Belben, M.B., F.R.C.S.; and James Keogh Murphy, L.R.C.P. (Kilgobbin, Ireland).

Mark Sharman, M.B., C.M.Glasg. (Rickmansworth), was proposed for election.

HYDROSALPINX AND SMALL OVARIAN CYST REMOVED BY ANTERIOR COLPOTOMY.

Shown by Dr. AMAND ROUTH.

THIS specimen was removed from a nulliparous woman of thirty-three years of age. There was also infra-vaginal elongation of the cervix, which was amputated by Schröder's method at the same time. As the uterus was

retroverted, and the left ovary also prolapsed, anterior vaginal fixation of the uterus was at the same time effected. There was slight pyrexia for a few days, and a swelling formed in the right broad ligament, believed to be a hæmatoma.

CASES OF FIBROMA OF THE OVARY AND OVARIAN LIGAMENT REMOVED BY OPERATION; WITH A SERIES OF AFTER-HISTORIES OF CASES REPORTED IN THE 'TRANSACTIONS' SINCE 1879.

By Alban Doran, F.R.C.S.

(Received February 1st, 1896.)

(*Abstract.*)

Fibroma of the ovary.—Two cases in the author's operative practice are first recorded; one typical and recently in hand, whilst in the second the tumour was removed in 1889, and though it seemed to present some of the microscopic characters of sarcoma, no recurrence has occurred.

Eleven cases are tabulated; they include the above, whilst the remainder were reported, when recent, in the Society's 'Transactions' since 1879, the author adding after-histories. This is done on account of the question of recurrence; since in four (Nos. 1, 8, 9, and 10) at least, malignancy was suspected, yet the after-histories proved innocence.

Most of the eleven bore the naked-eye characters of a fibroma. The suspicious microscopic elements in Nos. 1, 8, 9, and 10 were apparently connective-tissue cells between bundles of white fibre. Myomata of the ovary are not considered in this communication. In only one case (No. 1) was the disease bilateral. One (No. 4) exceeded ten pounds in weight; but older writers, in days when operation was deferred long after diagnosis, recorded heavier fibromata.

In 2 the patient was under twenty; in 4 under twenty-five; in 1 no age was reported, but the patient was young. In 3 she was between twenty-seven and thirty-six; and in 1 (No. 7), under the author's care, she was fifty-two. Thus the

disease is relatively frequent in youth, yet may develop after the menopause.

The tumour was observed in most cases about eighteen months before operation. In the only instance (No. 1) where there was no operation, the patient died of double pleurisy with ascites six years after the tumour was first detected. In six (Nos. 1, 2, 3, 7, 8, and 11) extreme hardness was noted on clinical examination; none seem to have been actually soft. Calcification was observed in one case (No. 2). Dysuria was a prominent symptom in two cases (Nos. 3 and 11); indeed in one of them (No. 11) an acute attack occurred a year before the tumour was detected. In more than half the cases the catamenia were regular. In three at least (Nos. 3, 7, and 11) the uterine cavity was abnormally long, though no uterine myoma existed.

In ten out of the eleven the tumour was removed by ovariotomy. In none was the operation very difficult, and all recovered. In seven no adhesions were found. The pedicle was always anatomically normal and long enough to be secured with ease. In two cases (Nos. 3 and 11) it was twisted, without causing the pain and other symptoms so prominent in twisted dermoids. In the eleven cases free fluid was found in the peritoneum in at least five (Nos. 1, 7, 8, 9, and 11). The author discusses this question at length.

The after-histories of the ten operation cases are, without exception, favourable. Eight remained free from recurrence two to twelve years after the operation. The two which remain recovered rapidly, but are quite recent cases.

Though always hard and heavy, fibroma of the ovary causes less pain than dermoid or any other solid or semi-solid ovarian tumour. A markedly hard and painless tumour, moving separately from the uterus, in a very young woman, is most probably an ovarian fibroma. Pedunculated subperitoneal uterine myoma is practically unknown in early womanhood, whilst dermoids, very common in youth, are seldom uniformly hard; and the hardest usually set up the most pain. Sarcoma of the ovary, relatively frequent in girlhood, is nearly always soft and associated with amenorrhœa and cachexia. Ovariotomy is the only treatment for fibroma of the ovary. The abdominal wound

bleeds very freely, as in cases of uterine myoma; it must not be made too short, else it may be badly bruised during extraction of the hard tumour.

Fibroma of the ovarian ligament.—Three authentic cases of this rare disease are tabulated. Two (Nos. 1 and 2) are certainly fibromata with cystic cavities; one (No. 3) is said to be sarcoma, but its extreme hardness and slow growth do not favour that theory. This tumour grows to a large size, the author's (No. 1) weighing over sixteen pounds. In all three the disease was unilateral and the adjacent tube and ovary free from the new growth. When large, the tumour may become œdematous and soft. Ascites and adhesions do not readily develop. In all three cases the patient was in the prime of sexual life. Menstruation was regular in every case. Diagnosis is hardly possible. The uterus may be enlarged, yet free from fibroids.

All three tumours were removed, In two cases (Nos. 2 and 3) the tumour alone was taken away, the ovary and tube being saved; but one (No. 3) died on the fourth day. There seems to be no tendency to recurrence, the author's case (No. 1) and M. Doléris' (No. 2) being both still alive and healthy six years and a half after the operation.

S. F—, aged 24, single, was sent to me on October 8th, 1895, by Mr. Naughtin, of Gloucester Place, W., on account of a tumour which had been noticed for about five months. A year previously she suffered from a sudden attack of retention of urine, relieved by the catheter.

The patient (No. 11 in the tables) was somewhat emaciated. Since an attack of influenza in 1890 she had been subject to cough, and there was clinical evidence of dilated bronchus. A moveable tumour of stony hardness occupied the lower part of the abdomen, reaching as high as the umbilicus in the median line, whilst a very irregular process extended much higher to the left. The hymen was intact, the uterus lay behind the growth, the sound passed 3¼ inches upwards, and the uterus could be moved

independently of the tumour. The period was rather free, and appeared about every thirty days.

I suspected fibroma of the ovary, as that tumour is seen in young women far more frequently than a pedunculated uterine fibroid. The great length of the uterine cavity in a virgin suggested, however, the possibility of the latter disease. Again, some dermoid ovarian tumours feel very hard.

On October 30th I operated with the assistance of Dr. Frederick McCann. The abdominal wound bled very freely, as is so often the case when a uterine fibroid exists. The tumour formed an irregular rocky mass. I made the incision just 4 inches long, as otherwise it would have been bruised by the hard tumour during extraction, and would very probably have suppurated. The pedicle was twisted half a turn to the right. It was fairly long, and very narrow. The Fallopian tube was œdematous. I secured the vessels in the outer border, then transfixed the main part of the pedicle, and tied it with No. 4 silk. There were a few ounces of pale red, clear serum in the pelvis, which I removed by the sponge. The wound was closed with eight deep and two superficial sutures.

The patient's convalescence was slow, owing to the bronchiectasis from which she suffered. Great quantities of thick yellow sputum were expelled after a fit of coughing on several occasions. There were no unfavourable symptoms at the seat of operation. I am glad that I did not make the wound too short, since, if it had been bruised during the extraction of the hard tumour, the subsequent coughing might have entailed suppuration. It healed by first intention, though the patient was sickly, and the cicatrix was very strong two months after the operation, when I saw the patient in excellent health.* Menstruation had continued normal; the right ovary appeared healthy at the operation.

The tumour weighed 3 lbs. 5 oz., which, since it

* In May, 1896, after these notes were written, the patient was doing well; she had gained flesh.

measured only 7 inches in its long and 6 in its short diameter, is a considerable weight. The mesosalpinx bore the same relation to the tumour that it normally does to the ovary. The ovarian ligament was very thick. The ovarian fimbria of the tube ran on to the surface of a thin-walled cyst on the upper part of the tumour. This cyst contained an ounce of clear, pale green watery fluid. Its pathological homologies could not be determined, the tumour being so far developed. It might have originated in the mesosalpinx, or have arisen from the tumour.

The surface of the tumour was somewhat irregular, white, and marked with blood-vessels. On section it was found extremely tough, much more so than a uterine myoma, which its cut surface resembled. Under the microscope it exhibited the usual characters of a fibroma, and showed few free connective-tissue elements.* I exhibit this evening some sections which Mr. Targett kindly prepared for me at the Royal College of Surgeons.

There remains a case of fibroma of the ovary under my care of special interest, since I referred to it when Dr. Handfield-Jones reported a similar case before the Obstetrical Society. One point of similarity was the suspicion of sarcoma, based upon microscopical, not clinical evidence. In both cases the after-history has shown that neither tumour was malignant.

My patient (see No. 7 in the tables) was fifty-two years old, and had borne eight children, the youngest being eleven years old. I saw her, in consultation with Dr. Rutherfoord, on March 26th, 1889. She stated that eighteen months previously she had noticed a hard lump in the right iliac fossa. The tumour was spherical, but it became more irregular. Six weeks before we examined

* The words of Mr. Targett's report are: "This tumour appears to be composed entirely of fibrous tissue, arranged in wavy bands, which interlace with one another. For the most part the fibres are nucleated, but here and there are bands which have become *fibroid*, and show no nucleation. It is moderately vascular, chiefly large vessels."

her, a sanious vaginal discharge was observed; it recurred occasionally afterwards. The menopause had occurred five years since. A solid, very hard and irregular mass filled the hypogastrium. It was apparently three-lobed. The cervix uteri was broad, and the sound passed three inches upwards. Then we found, contrary to expectation, that the uterus moved quite independently of the tumour, and behind it.

I removed the tumour on March 30th, 1889. I made a free incision and then determined its relations with ease. Atmospheric pressure held it rather firmly in the pelvis, but its extraction was easy. The pedicle was broad and anatomically normal, consisting of the tube and the mesosalpinx. The ovarian ligament was extremely thick. There were several ounces of clear red serum in Douglas's pouch. The infundibulo-pelvic ligament was œdematous. There was no difficulty in securing and dividing the pedicle, which sprang from the right side of the uterus. The left ovary was atrophied.

The patient informed me last November (six years and a half after the operation) that she was in robust health.

The tumour is preserved in the Museum of St. Bartholomew's Hospital (Pathol. Series, No. 2925, B.) When fresh it weighed a little under three pounds. It closely resembled the fibroma already described. In its interior was a large area of broken-down tissue, but there were no cysts either on its surface or deeper. The microscopic sections showed a dense stroma of pure fibrous tissue, with a distinct area of young connective tissue. On this account I suspected that the tumour might be a fibro-sarcoma, as did Dr. Handfield-Jones. But his patient was free from any sign of recurrence three years after the operation, and must have fared as well as mine. This question of apparent malignancy is one of the reasons why I have prepared this communication, seeking the after-histories of other cases well known to the readers of recent volumes of the Society's 'Transactions.'

Having related these cases of fibroma of the ovary in my own practice, I will now turn the attention of the Society to its own reports of similar cases during the past twenty years. These records throw some light on the subject of fibroma of the ovary. Afterwards something will be said on fibroma of the ovarian ligament.

For this purpose I have tabulated eleven cases of fibroma of the ovary. They all represent work brought before the Society, inclusive of the cases which I have just discussed. No. 3 was never actually published in the 'Transactions,' but some reference was made to this case in the course of discussion by Sir John Williams, who kindly sent me a note about it, as well as after-histories of other cases (Nos. 2 and 5), which are to be found reported in our archives. Other fellows of the Society have been equally kind in supplying me with after-histories. The table will therefore, I trust, prove of some use, particularly in reference to the question of suspected malignancy. In all cases, let it be observed, the suspicion proved unfounded.

In most of the eleven cases the tumour bore all the characters of a true fibroma, as recognisable without the microscope. The cellular elements detected in Nos. 1, 8, 9, and 10, were probably nothing more than part of the connective tissue between the bundles of fibres. In one, Dr. Dreschfeld's report (loc. cit., p. 278) that the tumour was a fibroma is probably correct after all. That distinguished pathologist had the advantage of examining a fresh specimen of the tumour. Mr. Knowsley Thornton and myself, who drew up a report at the request of the Society (loc. cit., p. 314) specially noted "that the tumours, owing to post mortem changes, and to the action of alcohol, are not in a satisfactory condition for accurate examination of their more delicate cell structures." We admitted "small open lymph-spaces . . . . bounded by large rounded masses of myxomatous tissue."* We found epithelial cells, but we prudently stated that "pro-

* Since that report was published, Dr. Coe's well-known researches on

bably these cells are the remains of the epithelial structures of the ovary, the possibility that they denote incipient carcinomatous degeneration also suggests itself, but the post mortem softening of the tumours makes us unwilling to express a too positive opinion on this point." I am now doubtful about the "oat-shaped spindle-cells," and the "small patches of round and oval cells in the ordinary stromal tissue." I suspect that they represent connective tissue altered by decomposition, and I doubt very much that we were justified in calling the tumour a "mixed sarcoma." Let us beware of examining growths in a state of decomposition. Lastly, the tumours existed for six years, yet were still small at the end of that period—a fact not in in favour of malignancy.*

Of Nos. 7 and 8 I have already spoken. Dr. Handfield-Jones and myself were suspicious, though the tumours are in both cases stony hard, which rendered malignancy of the sarcoma type very unlikely. The after-history showed that the tumours were clearly innocent fibromata. The same observation probably applies to No. 9. The spindle-cells and round-cells may be accounted for as in No. 1. A sarcoma weighing nine pounds usually recurs very rapidly, yet there was no symptom of recurrence thirteen months afterwards. No. 10 may probably be explained in the same way. The patient was operated upon in 1891, and remains free from recurrence.

From the above evidence we must conclude that innocent fibromata often bear connective-tissue elements which suggest sarcoma-tissue, but after-histories prove that these elements do not denote malignancy.

In all the eleven cases except No. 1 the tumour was unilateral.

"geodes" and other appearances seen in these tumours appeared in the 'American Journal of Obstetrics,' vol. xv, 1882.

* With regard to cases where no operation was performed, I must refer to Dr. James Crawford's note ('Transactions,' vol. xxxvi, 1894, p. 190). The patient was forty-nine, and had committed suicide. At the post-mortem a pure fibroma of the left ovary, weighing 6½ ounces, was detected.

As to weight, No. 4 weighed nearly eleven pounds. The earlier ovariotomists removed yet larger tumours of this class, but in these days abdominal growths are more often detected when quite small, whilst the advantages of early operation are fully recognised.

Leopold many years ago showed that fibroma of the ovary may occur in very young women. These tables confirm his researches. In two out of the eleven cases the patient was still in her teens. In four (and probably in five, No. 5 being quite young) she was under twenty-five. In three she was between twenty-seven and thirty-six. The average is very much upset by my own case (No. 7) where the patient was fifty-two. Yet the disease showed all the features seen in the younger cases, and the patient remains in good health and free from recurrence nearly seven years after the operation. The truth is evident that fibroma of the ovary, never common, has been repeatedly observed at early ages where uterine fibroid disease is all but unknown; yet it is not essentially a disease of youth, since it may occur after the menopause, and in such cases the tumour appears to be as free from malignancy as when it develops early in sexual life.

As might be expected, this kind of tumour grows slowly. On an average, it was observed eighteen months before operation or death in these eleven cases. This fact is, however, of little value for diagnostic or prognostic purposes, since in No. 4 a tumour nearly eleven pounds in weight had only been detected six months before operation; but its size, when first discovered, is not given; whilst in No. 7 a three-pound tumour increased very little in eighteen months; and in No. 11, where the tumour was of the same weight, it had been first noted five months before operation and had also grown but little afterwards. Most important, as regards the question of growth, is Case 1. Two small pelvic tumours had been detected over six years before the patient died of pleurisy. Yet at the necropsy the tumours were found to be still

small. I remember examining them in 1879; they were of about the same size as in my cases, Nos. 7 and 11. Thus, No. 1 showed very slow growth in six years. This proved, as no operative interference was ever undertaken during the long period that the tumours were observed, that fibroma of the ovary is naturally a slow-growing kind of neoplasm. It also supports very strongly the theory, which I have already discussed, that the tumours were innocent and not sarcomata.

In six (Nos. 1, 2, 3, 7, 8, and 11) hardness was observed before death or operation. Nos. 8 and 11 were described as "stony hard," No. 7 as "very hard," and none were said to be soft. Calcification was noted in one case (No. 2) only. It is not so common in fibroma as in myoma; yet on palpation I find that a non-calcified ovarian fibroma feels as hard as a calcified uterine fibroid. As bimanual palpation is not always easy in plump and muscular young subjects, the hardness may occasionally be overlooked.

In two of the eleven cases (Nos. 3 and 11) dysuria was recorded; in No. 3, as the tumour was large, this complication might have been expected; but in my own case (No. 11) it is interesting to remember that an acute attack occurred a year before the tumour was detected, and when removed the tumour was small.

The catamenia seemed but little affected. In more than half they were regular. In several there was free show; but there seemed no evidence to prove that the phenomenon was due to the tumour, nor that fibromata also existed in the uterus. A pedunculated uterine myoma is not accompanied by menorrhagia, unless there be similar interstitial or submucous growths, or some independent uterine affection. This fact is very well known, and we therefore can well understand that the period is not appreciably influenced by an ovarian fibroma.

The uterine cavity was found to be over 2½ inches in Nos. 3 (3½ inches), 7 (3 inches), and 11 (3¼ inches). In none of the three was there myoma of the uterus. The enlarge-

ment was of the kind not rare in cases of ovarian tumour. It probably existed in other cases. The clinical interest of this fact is evident. It very naturally leads the surgeon to suspect that the tumour is a pedunculated fibroid, and is the greatest cause of error in diagnosis. The youth of the patient, however, will in most cases counteract this tendency to take an ovarian for a uterine growth.

In ten out of the eleven cases the tumour was removed by ovariotomy. In not one of the ten was the operation attended with any real difficulty, and all recovered. In two (Nos. 4 and 9) there were omental adhesions. In one (No. 3) there were adhesions to the parietes, cæcum, and colon. In the remaining seven there were no adhesions. But in Nos. 3, 4, and 9, the tumours were large and heavy, the adhesions representing a complication of little gravity under the circumstances. They seem in no case to have been very firm, and merely resulted from slight inflammatory irritation, frequent when a patient in good general health goes about with a heavy abdominal tumour.

The pedicle was normal in all the eleven cases; that is to say, it consisted of tube, mesosalpinx, and ovarian ligament. In two (Nos. 7 and 11) where I was the operator, and closely inspected the pedicle, the ovarian ligament was very distinctly hypertrophied, but bore no separate fibroma. This hypertrophy may have been present in others, possibly, I believe, in all. My personal attention, however, had recently been turned to the question of tumours of the ovarian ligament when I removed No. 7.

Twisting of the pedicle was detected in two (Nos. 3 and 11). In both cases the patient was young (twenty-seven and twenty-four), and single, and only in one of them (No. 3) was there a distinct complaint of pain. They both sought relief because they had tumours and were single rather than on account of severe pain. In No. 3 there were adhesions, but they seem to have been easily separated; in No. 11 I found none. The experienced operator cannot fail to be struck with the absence

of pain in this complication, when fibroma of the ovary exists. In dermoid ovarian tumours twisting of the pedicle is extremely common, but it is usually associated with severe or at least very distinct pain and with troublesome adhesions. Yet fibromata are far heavier and quite as liable to roll about.

Closely associated with this complication in clinical interest is the question of peritoneal effusion. Whilst torsion of the pedicle is very common and troublesome in dermoids, effusion is relatively rare. On the other hand, free fluid was distinctly noted in five out of the eleven cases of fibroma of the ovary (Nos. 1, 7, 8, 9, and 11), and I suspect that it existed in several others, as the sponges may take up a few ounces unobserved (see No. 9, where we find the note: "*Little* or no excess of peritoneal fluid."). In No. 1, the unoperated case, there was marked ascites. In none of the others was there clinical evidence of effusion. The serum was detected at the operation, and seems to have been reddish in all instances.

Thus fibroma of the ovary irritates enough to cause more or less effusion. We know well that in malignant tumours of the pelvic organs ascites is almost the rule, and sets in early. When papillomata develop on the free surface of the ovary, or on the mucous membrane of a Fallopian tube with its ostium still unobstructed, very free peritoneal effusion may occur. The perforation of the outer wall of a papillomatous ovarian cyst by two or three small intra-cystic growths is quite sufficient to set up free effusion, as I have repeatedly observed in my own cases. From this we may conclude that it is the free secretion of papillomata of the ovary and tube that causes the effusion by irritating the peritoneum.

A typical ovarian cystoma is seldom associated with ascites, even when the tumour is large and still moveable and the patient young and active. Adhesive peritonitis or twisting of the pedicle are the commonest complications. The same observations apply even more thoroughly to

dermoids, and, above all, as far as effusion is concerned, to parovarian cysts. Yet Jeannel of Toulouse, when performing the radical operation for a strangulated hernia in a patient where there was much ascites, discovered a simple parovarian cyst floating freely in the fluid contents of the peritoneum. The pedicle appears to have been long, and as the ascites never returned after the operation, M. Jeannel concluded that it was set up by the movements of the freely pedunculated tumour.

Yet not only do small long-pedicled ovarian tumours rarely cause ascites, but pedunculated uterine myomata are also slow to produce that complication. We all know how common is this morbid growth, yet we find women going about for years with masses of these subperitoneal myomata, without the least evidence of ascites. During an abdominal section intestinal adhesions are occasionally seen, yet the peritoneal cavity is usually found quite dry.

Subperitoneal fibroids make us at once think of the subject of this communication, yet though in physical characters and position ovarian fibromata and pedunculated uterine myomata are very similar, the ovarian tumour is far more prone to cause ascitic effusion.

I feel inclined to say, as Olshausen said in 1886, "The cause of the ascites in such cases remains, as a rule, obscure." * The surface of an ovarian fibroma is smooth and free from any secreting growth; the tumour itself is heavy, and certainly may roll about freely in the peritoneal cavity. Hence I must assume that the tumour is just irritating enough to the peritoneum to set up effusion but not so irritating as to cause adhesive peritonitis. In respect of the latter complication, the weight of the growth and its consequent tendency to gravitate at every change of position must be remembered. The anterior aspect of a dermoid keeps much more closely in contact with the parietes, and therefore has a better chance of adhering. Adhesions were observed in Cases 4 and 9 in this series, where the fibroma was big and could not easily fall back

* 'Krankheiten der Ovarien,' 2nd edit., p. 418.

out of contact with the parietes. In No. 3 there were more troublesome adhesions, but the pedicle was twisted and the mobility of the tumour thereby impaired.

Before dismissing this subject of peritoneal effusion, I will turn attention to Case 1. The ascites and double pleural effusion would at once have been noted as infallible evidences of malignancy. This clinical complication has, however, been observed in papilloma of the tube, where the after-history has shown that the patient may survive for years the amputation of the diseased tube, without the least vestige of recurrence.

The after-histories of the ten operation cases were without exception favourable. Not only did all recover, but eight were free from recurrence two to twelve years after operation (Nos. 2—8 and 10). The most certain are No. 6 (four years), No. 10 (four and a half years), No. 4 (eight years), and No. 3 (twelve years). The remaining two operation cases (9 and 11) recovered, and were in good health within a few months of the operation.* There remains No. 1, where the tumour had been observed for six years, and the patient died of pleurisy. This case is, in itself, a plea for early operation.

Thus we see that fibroma of the ovary causes less pain than dermoid or any other solid or semi-solid ovarian tumour, yet it is always hard and heavy. A very hard, painless tumour, moving separately from the uterus, in a very young woman, is most probably an ovarian fibroma. Pedunculated subperitoneal uterine myoma is practically unknown in early womanhood, whilst dermoids, very common in girls, are seldom uniformly hard; and the hardest usually set up the most pain. Sarcoma of the ovary, relatively common in girlhood, is nearly always soft. It is associated with amenorrhœa and marked cachexia. Ovariotomy is undoubtedly the right treatment for fibroma of the ovary at any age. It is a safe, easy, and extremely successful operation under these circumstances. The ab-

* I must here refer to Dr. Horrocks' two doubtful cases of solid ovarian tumour ('Transactions,' vol. xxxvi, 1894, p. 192).

dominal wound bleeds freely ; as in cases of uterine fibroid it must not be made too short, else the hard tumour will bruise it, and delay subsequent union.

I will now turn to an undoubtedly rarer disease.

Fibroma of the Ovarian Ligament.

The first case occurred in my own operative practice, six weeks after I removed the tumour in Case 7. It is reported in the 'British Medical Journal,' 1889, vol. i, p. 1287, as a "Fibroma of the ovarian ligament, weighing over sixteen pounds; removal; recovery." I exhibited the tumour itself at a meeting of this Society. The patient was thirty-two, and the operation was performed in May, 1889. The enormous tumour, made all the more bulky by œdema, sprang from the right ovarian ligament, which was greatly elongated and hypertrophied, as in the other cases. The pedicle was an inch and a half long. I specially noted during the operation that not only was the ovary free from fibromata, but the uterus was also small and bore no trace of any myomatous growths. The sound passed three and a half inches before the operation, and though the uterus moved separately from the tumour, I was surprised to find it free from fibromata. In November, 1895, Dr. Waugh, of Toddington, Beds, wrote to me saying that this patient was in very good health, and there was nothing to indicate a recurrence.

This case is interesting as being the first recorded instance of the removal of a true tumour of the ovarian ligament. Doléris operated on a case six weeks afterwards (see No. 2, Tables of Fibroma of the Ovarian Ligament). This patient remains in perfect health.*

* M. Doléris deserves my special thanks for the trouble which he has taken in order to make sure of the after-history of Case 2. He writes: "Paris, le 8 Février, 1896. Mon cher confrère,—J'ai mis un peu de temps à vous répondre en raison des démarches très longues nécessitées pour retrouver mon operée de 1889. Je puis vous dire aujourd'hui qu'elle est en très bonne santé. Elle ne se ressent nullement de son ancienne maladie, ni dans

Penrose recently removed a "sarcoma" of the ovarian ligament (ibid., No. 3). He simply states that "microscopical examination shows the specimen to be a sarcoma." The patient was thirty-one years old; she was struck on the left side eight years before operation, and the tumour had been noticed for two and a half years. The operation was performed during pregnancy. It was "a round tumour, freely moveable, *stony hard*, somewhat irregular in outline, about the size of a child's head . . . occupying the site of the left ovarian ligament." The ovary, as in my case, was not involved in the new growth. Unfortunately the patient died a few days after the operation.

I cannot help thinking that, had the patient survived, the growth might not have recurred. The history of a blow is not rare in association with sarcoma, but coincidences must be taken into account, as plenty of women with benign tumours may have struck their sides. The growth of the tumour was slow. It weighed 5 lbs., and was "stony hard." I have never heard of a heavy malignant tumour of any pelvic organ being stony hard; the description strongly suggests fibroma, which, as we have seen, is usually very hard when seated in the ovary. I believe that Dr. Penrose's pathologist may have taken young connective tissue amidst the fibres for sarcomatous elements, as I was inclined to do in Case 1 in the ovarian fibroma cases. In my own case, the sixteen-pound tumour, which actually sprang from the ovarian ligament, looked highly malignant until it became evident that it was a very œdematous congested fibroma. The after-history has settled its innocence.

My operation, as well as Doléris' and Penrose's, shows that clinically and also surgically a fibroma of the ovarian ligament is ovarian. I have given reasons elsewhere* for believing that pathologically this form of tumour is

son état général ni dans son état local. Elle a seulement un peu engraissé. Cela démontre que la tumeur n'avait aucun charactère malin.—DOLÉRIS."

* "On Myoma and Fibroma of the Uterus," &c., 'Trans. Obstet. Soc.,' vol. xxx, 1888, p. 419.

uterine. Strictly speaking, however, I wrote in reference to myomata, though the fibromata and myomata are closely related pathologically, and yet more so clinically, in the female organs. Nor can I forget that within a year after my opinion was published, I operated on a case of fibroma of the ovarian ligament where the tumour was gigantic, yet the uterus free from any similar growth.*

I cannot find any more authentic records of fibroma of the ovarian ligament. From what has just been written, and from the table of the three cases, it will be seen that the disease is very rare, and that there was no doubt of the nature of the growth in Nos. 1 and 2, whilst the alleged malignancy in No. 3 was open to question. The tumour may grow to a very large size; in my own case it exceeded sixteen pounds in weight. In all cases the disease was unilateral, and the adjacent tube and ovary free from the new growth. The tumour when large (No. 1) may become œdematous and soft. The tendency for ascites to develop is slight. In Nos. 2 and 3 there were no adhesions; in No. 1 the tumour adhered to the parietes and omentum, but the tumour was large (compare No. 3 in the Fibroma of the Ovary table) and the patient worked hard.

In all three cases the patient was in the prime of sexual life (thirty-two, twenty-seven, and thirty-one years old), far from puberty or the menopause. Menstruation was regular in every case. None were diagnosed, and correct diagnosis seems impossible. The uterus may be enlarged though free from fibroids (No. 1). Whether in No. 1, where the tumour was so large, the uterine enlargement

* Purely pathological evidence on this question is conflicting. In 1887 I discovered a fibro-myoma about half an inch in diameter in the left ovarian ligament. The uterus was the seat of a fibro-myoma, the ovary was free from any new growth ('Trans. Path. Soc.,' vol. xxxviii, 1887, p. 245). On the other hand, since I prepared this memoir, Olshausen exhibited at Berlin "a pure myoma of the ovarian ligament, as large as a bean, discovered accidentally during abdominal section for removal of a fibroma (*sic*) of the ovary." Gottschalk has seen a similar case ('Centralbl. f. Gynäk.,' 1896, p. 279). Of the above conditions, association with a uterine tumour is, of course, the more serious for the operator when the ovarian ligament growth is so large as to demand removal.

I. *Fibroma of the Ovary.*

No.	Operator and reference.	Age, married or single.	Symptoms and duration before operation.	Menstrual history.	Operation.	Characters of the tumour.	After history.
1	Cullingworth, 'Trans. Obst. Soc.,' vol. xxi, 1879, pp. 276, 314	36, W.	Swelling over 6 years; small nodular tumours in pelvis; last 3 months ascites, double pleurisy, with effusion into left pleura	Regular till 9 mos. before death; then slight metrorrhagia 6 mos.; amenorrhœa last 3 mos.	None. Death from the pleurisy	Fibroma according to Dreschfeld (see text).	—
2	Sir J. Williams, 'Trans. Obst. Soc.,' vol. xxv, 1883, p. 35, and private communication	18, S.	Painless, hard, moveable swelling about 2 years; rapid increase last 6 weeks; reached to ensiform cartilage; uterus 2½ inches, freely moveable	Did not appear till 17; then regular, but missed a period before operation	Ovariotomy; pedicle thin and long; no note of opposite ovary; no ascites	"A calcifying fibroma of the ovary;" 8 inches longest diameter; firm to touch, soft at certain points	Was in good health 2 years later.
3	Id., unpublished case, April, 1883	27, S.	11 months swelling, pain, dysuria; hard tumour rising above umbilicus; uterus 3½ inches	Regular, scanty, painful	Ovariotomy; twisted pedicle; adhesions to parietes, cæcum, and colon; no ascitic fluid	A fibroma, lobulated and nodulated; hæmorrhagic area inside; ovarian ligament ran into a kind of hilum	In excellent health 12 years after the operation.
4	C. H. Carter, 'Trans. Obst. Soc.,' vol. xxix, 1887, p. 190, and private communication	20, S.	Swelling noted about 6 months; last 6 weeks abdominal girth increased 1 inch	Amenorrhœa 3 mos., then regular; health improving	Ovariotomy, right ovary; broad pedicle, wide omental adhesion	Round, smooth, very hard, fibro-myoma, 10¾ lbs. in weight	Alive and well 8 years after operation.
5	Sir J. Williams, 'Trans. Obst. Soc.,' vol. xxix, 1887, pp. 247, 513, and private communication	? (a young woman)	?	?	Ovariotomy; opposite ovary healthy	A pure, or almost pure, fibroma, 7 lbs. 7 oz.; partly cystic; pedicle twisted and thrombosed	Well about 2 years afterwards.

6	J. Knowsley Thornton, reported by Doran, 'Trans. Obst. Soc.,' vol. xxx, 1888, p. 426, and private notes	20, married at 15	Abdomen gradually increased in size for several months	Regular	Ovariotomy; tumour on left side; right ovary healthy	A pure fibroma. See microscopical drawing, pl. iii, fig. 5, loc. cit.	Well 4 years later; bore a child. See loc. cit., p. 426, footnote.
7	Doran, 'Trans. Obst. Soc.,' vol. xxxi, 1889, p. 126. Full report in present article	52, M.	18 months lump in right iliac fossa; slow growth; a *very hard* mass formed in hypogastrium; uterus 3 inches, quite separate; no ascites noted	Ceased 5 yrs.; never copious; sanious discharge 6 wks. before operation	Ovariotomy; pedicle broad, chiefly made up of ovarian ligament (right); left ovary atrophied, not removed; several ounces clear red serum in pelvis; no adhesions	A very hard, smooth tumour, 3 lbs.; a fibroma with broken-down tissue in its interior. See text	Quite well over 6½ years after operation.
8	M. Handfield-Jones, ibid. (see 7), and private communication	21, M., one child 18 mos. old	18 months lump in right iliac region; reached above umbilical level; *stony hardness;* no ascites noted	Regular, no pain	Ovariotomy; good pedicle, no adhesions (right side); pint of clear fluid in peritoneal cavity	Stony-hard tumour, "principally a fibroma;" sarcoma suspected. See text	"Alive and well 3 years after operation."
9	Dakin, 'Trans. Obst. Soc.,' vol. xxxvi, p. 313, and private communication	36, M.	1 year moveable lump; abdomen increasing 9 months; tumour felt like a cyst; no ascites	"Not affected"	Ovariotomy; right ovary removed; left normal, not removed; omental adhesions; "little or no excess of peritoneal fluid"	Solid tumour, 9 lbs. 6 oz.; "mixed spindle and round-celled sarcoma"	No sign of recurrence 13 months afterwards.
10	Cullingworth, 'Trans. Obst. Soc.,' vol. xxxvi, 1894, p. 314 (operation Apr. 1891), and private communication	19, S.	Tumour discovered during a vaginal examination for menorrhagia	Menorrhagia	Ovariotomy; solid right ovarian tumour, no adhesions; opposite ovary healthy, removed (see original report)	Pronounced, "after repeated examinations, to be an undoubted example of a spindle-celled sarcoma"	No sign of recurrence 4½ years afterwards.
11	Doran, present article	24, S.	Noticed 5 months (but acute dysuria 1 year, see text); *very hard* irregular mass in hypogastrium; uterus 3¼, quite separate; ascites not noted	Regular, rather profuse	Ovariotomy; pedicle (right side) twisted, ovarian ligament hypertrophied, no adhesions; opposite ovary healthy; pint of clear red serum in pelvis	Irregular hard tumour, weight 3 lbs. 5 oz.; one cyst on surface	Well 2 months later.

II. *Fibroma of the Ovarian Ligament.*

No.	Operator and reference.	Age, married or single.	Symptoms and duration before operation.	Menstrual history.	Operation.	Characters of the tumour.	After history.
1	Doran, 'Brit. Med. Journ.,' 1889, vol. i, p. 1287 (noted 'Trans. Obst. Soc.,' vol. xxxi, 1889, p. 200)	32, W.	Abdomen swelling 2 years; latterly rapid increase; no sign of ascites; uterus 3½ in., pushed low down in pelvis (it contained no fibroids)	Regular, moderate show	Ovariotomy; omental and parietal adhesions; tumour sprang from hypertrophied right ovarian ligament; left appendages also removed; no free fluid	A soft œdematous fibroma, over 16 lbs. in weight; pseudo-cysts in interior; right ovary and tube normal; left ovary atrophied, contained small cysts	Quite well 6½ years later.
2	Doléris, 'Bulletins et mémoires de la Soc. Obstét. et Gynéc. de Paris,' 1870, p. 21, and private communication, Feb., 1896	27, M., 2 pregnancies	Detected 1 month before operation, when hypogastric pains had set in. (2 years before, careful examination after labour, no tumour.) Very fat subject; tumour hard to define	Very regular, one day only; menorrhagia during lactation 2 years before	Removal of tumour only, by ligature of its pedicle, which sprang from ovarian ligament; uterus free from fibroids; ovary and tube healthy; reddish ascitic fluid	A fibro-myoma as big as an orange; cystic cavities; pedicle 2 inches long before section, as thick as little finger	Quite well over 6 years later.
3	Penrose, 'Amer. Journ. Obstet.,' vol. xxxii, 1895, p. 956	31, M., 5 children, and pregnant at operation	Detected 2½ years before operation, during 5th pregnancy. At date of operation a "*stony-hard*" tumour, about size of child's head, lay to left of pregnant uterus	Quite regular	Removal of tumour; ovary and tube not involved	A *hard* tumour 5 lbs. in weight. "Microscopical examination shows the specimen to be a sarcoma" (but see text)	Died 4 days after operation, of peritonitis.

was a true secondary condition, I cannot say. It is possible, but such a theory requires the support of wider clinical experience, which I hope that others may record.

All three were removeable by operation. In my own case (No. 1) the corresponding tube and ovary were removed. In Nos. 2 and 3 the tumour alone was taken away, but No. 3 died of the operation. Here, again, more experience is wanted. That an operation is needed there can be no doubt. The advantages of leaving the appendages remain to be seen. I am not sure that Doléris and Penrose did not operate on correct principles. The pedicle of the tumour in Nos. 2 and 3 was probably favourable for the application of the ligature, whilst, had the broad ligament been transfixed, and had the ovary and tube been amputated as well, the stump of the pedicle must of necessity have been dangerously short, since the ovarian ligament was taken up by the pedicle of its tumour, which came close up to the uterus. In my own case I secured the pedicle of the tumour, which I then cut away, but I saw that the ovary was cystic, and therefore removed it. Altogether I was glad to take away the thick, succulent stump of the pedicle of the tumour along with the appendages. I succeeded in making a good normal pedicle, and that involved the securing of the enlarged ovarian vessels. My case, however, was exceptional. I suspect, nevertheless, that when the tumour is very large a short "normal" or ovarian pedicle involves less risk than a thick, succulent tumour pedicle, so the appendages are best taken away; the ovarian vessels should be separately secured with the greatest care. When the tumour is small, Doléris' and Penrose's practice would probably be the safer course.

There seems to be no tendency to recur; my own case and Dr. Doléris' having both survived the operation over six years and a half, and remained in good health.

I have scrupulously avoided any mention of true myoma or fibro-myoma of the ovary or ovarian ligament,

as I find that the discussion of fibroma alone is quite sufficient for a single communication.

Dr. MACNAUGHTON JONES showed sections of a fibroma of the ovary, to illustrate several of the points referred to in Mr. Alban Doran's paper. The case was an interesting one, occurring in a young girl of 22; and in its painlessness, mobility, and feeling of density, gave the idea of a pedunculated myoma. The tumour was discovered accidentally, as the patient had never complained of any pelvic symptoms save menorrhagia. She had consulted him for anæmia and gastric symptoms. The tumour lay between the bladder and uterus, in the middle line. It was about the size of an orange, and encapsuled. Mr. Bland Sutton was present at its removal. The patient made a perfect recovery. He intended to publish full particulars of the case.

Dr. HANDFIELD-JONES narrated the clinical history of a case of fibroma of the left ovary which he had operated upon. In this instance the patient's age was 58, and formed a contrast to most of the recorded cases, these latter occurring for the most part in young women. The tumour had been under observation for several years before operation, and had shown very little tendency to increase in size. The patient had made a good recovery, and had not any recurrence of the growth. There was nothing in the clinical history nor in the morbid anatomy of the tumour to suggest the probability of the growth being malignant in nature, though some of the microscopical sections made from the tumour showed appearances somewhat similar to a spindle-celled sarcoma. Probably operation would have been deferred for some time if the rapid growth of a multilocular cyst springing from the opposite ovary had not rendered immediate interference imperative.

Dr. PETER HORROCKS pointed out the present unsatisfactory state of our knowledge of the histological differences between fibromata and sarcomata and allied conditions. This difficulty was shown in a case of his own exhibited at this Society. The tumour was shown as a case of fibroma of the ovary, and the microscopical appearances of sections seemed to several pathologists to indicate its fibromatous nature; and yet Mr. Bland Sutton on looking at the sections pronounced them to be typical of a sarcoma. Similarly Mr. Doran in the cases brought forward was obliged to state that several of his so-called fibromata of the ovary were pronounced or suspected to be sarcomata by other pathologists. Hence Mr. Doran appeared to rely for his diagnosis not on the histology of the growth, but on the after-history of the case. If it recurred it was sarcoma, and if it did not, it was fibroma. He did not think that this deduction was

scientific. Even if true as a matter of fact, which he doubted, it was not a conclusion which had been logically derived from the premises. After all, fibromata were collections of connective tissue and sarcomata were essentially connective-tissue tumours; and judging by fibromata under the skin and elsewhere, it was highly probable that they might remain pure fibromata in their histology, and innocent in their action for years, and then become sarcomatous and malignant. Some day this might be explained, and in all likelihood it would be found that the fibroma became sarcoma, and so malignant, by the sperm action of some microbe.

Dr. CULLINGWORTH said that whilst agreeing with the preceding speakers as to the high value of Mr. Doran's paper, he felt obliged to take exception to one or two of his statements. It was stated in the second paragraph of the abstract, in reference to four of the tabulated cases, that "the after-histories proved innocence." This seemed to him an utterly untenable position to take up. If the non-recurrence of a new growth after its removal was to be taken as evidence of its non-malignancy, no more hopeless surgical doctrine could be promulgated. It amounted to saying that no case of malignant tumour could be cured by operation.

The other statement to which he ventured to take exception was that "in early womanhood pedunculated subperitoneal uterine myoma is practically unknown." It might be and no doubt was correct to say that pedunculated subperitoneal uterine myoma was rare in early womanhood, but that was a very different thing from saying that it was "practically unknown." He supposed most of those whose experience extended over several years had met with one or more instances.

The paper had a special interest for him, as the first case in Mr. Doran's table was one that he had himself brought before the Society seventeen years ago. He had, in his communication at that time, given an abstract of most of the cases that had been recorded, and a summary of what was then known on the subject. The communication was printed in the Society's 'Transactions' for 1879, and was illustrated by a lithographic plate of the preparation, and a woodcut showing diagrammatically how difficult it might be to arrive at a correct diagnosis. The case was one of fibroma of both ovaries. A glance at the woodcut (which he now handed up to the President) would show that one of the tumours lay directly in front of the uterus, and the other directly behind it; the uterus being firmly impacted between them. It was not to be wondered at that he had regarded the tumours during life as uterine myomata. But that case presented a point of still greater interest. Relying on an elaborate report of the microscopical appearances of the tumours by so distinguished a

pathologist as Dr. Dreschfeld, of Manchester, he spoke of them as fibromata. In the discussion that followed, most of the speakers were disposed to doubt the correctness of this diagnosis and to regard the tumours as malignant on account of there having been an effusion of fluid both into the peritoneal and pleural cavities. It was interesting in this connection to note that free fluid was found in the peritoneum in at least five of the eleven cases tabulated in Mr. Doran's paper. The result of the discussion, however, was that the tumours were referred for microscopical examination and report to a committee consisting of Mr. Knowsley Thornton and Mr. Doran. These gentlemen pronounced that the tumours were not fibromata, but sarcomata. Their report was received with some astonishment in Manchester, where Dr. Dreschfeld's opinion on points of pathology was seldom disputed. The Fellows would understand that it had not been without a certain feeling of satisfaction that he (Dr. Cullingworth) had listened that evening to Mr. Doran's announcement that he had now seen reason to change his opinion. He begged to thank Mr. Doran for his frank admission. It was by such means that knowledge was advanced.

With regard to Case 10 in the table, there was again a difference of opinion as to the nature of the tumour, affording a signal illustration of the difficulties of histological interpretation to which Dr. Horrocks had alluded. Mr. Shattock, the curator of the museum at St. Thomas's Hospital, and one of the highest pathological authorities in this country, had made repeated microscopical examinations of this tumour, and had pronounced it to be an undoubted example of a spindle-celled sarcoma. But, because there had now, after five years, been no recurrence of the growth, Mr. Doran declared that it could not be a sarcoma. He regretted that through an oversight he had omitted to inform Mr. Shattock that Mr. Doran's paper was to be read that evening, otherwise he had no doubt Mr. Shattock would have been present to support his own opinion. He believed, however, that in view of the doubts that Mr. Doran had expressed, Mr. Shattock had made fresh sections and had re-examined the tumour. If that were so, he would ask permission to append the result in the form of a foot-note to the report of his remarks in the 'Transactions.'*

Dr. Herbert Spencer quite agreed with the author of the paper that these hard growths were of a simple nature; they were fibromata or fibro-myomata and not sarcomata, notwithstanding the appearances under the microscope, which often resembled those of a spindle-celled sarcoma. He had made observations on four of these cases,—one observed at

* Mr. Shattock made a number of fresh sections, and reported that he must still regard the tumour as a fibro-sarcoma.

a post-mortem examination, which showed there were no secondary growths; the other three operation cases, which were free from recurrence after considerable periods, in one instance after four years. In one of his cases the opposite ovary was developed into a large ordinary multilocular cystic tumour.

With regard to the diagnosis, he had made it in one case, and demonstrated it as a case of ovarian fibroid before operation by the hardness of the growth and by tracing bimanually the pedicle to the uterus at the spot where the ovarian ligament is attached. The youth of the patient formed no certain means of diagnosing an ovarian from a uterine fibroid. He (Dr. Spencer) had twice removed the uterus for fibroids in women of no more that twenty-eight years of age. Pleural effusion he had thrice met with in cases of simple ovarian cysts. He had also on three or four occasions met with small fibroid tumours of the size of a marble in the walls of multilocular ovarian cysts. He had not met with any record of these little tumours affecting ovarian cysts, but they were not so very rare.

THE PRESIDENT asked Mr. Doran:—(*a*) Whether he considered survival to prove non-malignancy, and if so, whether he would make this statement of both forms of malignant disease, or whether he referred only to sarcoma; if so, what he would say about cases, *e. g.*, of cancer of the uterus in which no recurrence has taken place. (*b*) Whether he maintains that fibroids of the uterus before the age of twenty-five are "practically unknown," or as Mr. Cullingworth suggests, only "very rare." The matter is one of importance.

Mr. ALBAN DORAN, in reply, observed that Dr. Macnaughton Jones' case was typical in every respect like his own No. 11, whilst Dr.-Handfield Jones' was like his own No. 7, typical except that the patient was elderly. Dr. Handfield-Jones in relating his case had shown that when a tumour was not removed it was the duty of the medical attendant to watch it very carefully. For a fibroma of the ovary might be mistaken for a small pedunculated fibroid, a less troublesome form of tumour, and Dr. Jones' case of the former disease showed that cystic changes might develop in the opposite ovary. In Mr. Doran's case of fibroma of the ovarian ligament, the corresponding ovary was already cystic. Drs. Horrocks and Cullingworth had dwelt on the important question of malignancy and innocence. Mr. Doran felt certain that not many years ago too much stress was laid on the term "spindle-cells." Young pathologists mistook any normal cellular structures with elongated nuclei for the cells which made up the true and very malignant sarcoma so often seen in the bones and fasciæ. Hence the connective-tissue cells in the fibroma of an ovary have often been reported as "small spindle-celled sarcoma."

He regretted that no general pathologist was present; the recent discussion on deciduoma malignum had shown the value of the opinion of experts. Dr. Horrocks said that the after-history of many years of immunity did not prove innocence. At the most it could only signify that the fibroma might have become malignant if left alone, but that it was not so when removed. He dwelt a little further on the question, arguing that if a class of tumours appeared histologically very malignant yet proved clinically innocent, they must be reckoned as essentially innocent. Fibroma of the ovary was histologically innocent, and the alleged malignant features might well represent misinterpretations. Mr. Doran now agreed with Dr. Cullingworth that Case 1 was a fibroma; in 1879 he thought that it was a sarcoma, believing too much seventeen years ago in spindle-cells and in the gravity of ascites in association with abdominal tumours. He would like to know of a monograph on pedunculated or any other form of myoma of the uterus in women under twenty-five. Dr. Herbert Spencer must be congratulated on having diagnosed fibroma of the ovary by detecting a thickened ovarian ligament during bimanual palpation. In some cases, however, the ligament was very short and hidden under bulging prominences of the tumour, so that its detection would be impossible. The small fibrous bodies which Dr. Spencer described, might, Mr. Doran thought, have been Patenko's corpora fibrosa, but Dr. Spencer had reason to believe that they were true fibromata. In conclusion, Mr. Doran maintained that when a tumour was diagnosed as ovarian fibroma, it was the duty of the surgeon to remove it. If on microscopic examination it appeared to possess malignant characters, and if the patient survived the operation for many years, he must not conclude that he had triumphed over malignancy. Mr. Doran felt sure that many readers had taken fibroma for sarcoma, and that he himself had overlooked the sources of fallacy on which he had just dwelt, when he stated in 1884 in his 'Tumours of the Ovary,' that he had never found a solid ovarian tumour to be formed of pure fibrous tissue, and that sarcoma of the ovary was less malignant than sarcoma elsewhere.

ANTERIOR COLPOTOMY.

By John Phillips, M.A., M.D.(Cantab.), F.R.C.P.,

ASSISTANT OBSTETRIC PHYSICIAN, KING'S COLLEGE HOSPITAL; SENIOR PHYSICIAN, BRITISH LYING-IN HOSPITAL; EXAMINER IN MIDWIFERY TO UNIVERSITY OF CAMBRIDGE.

(Received February 10th, 1896.)

(*Abstract.*)

The author considers that to Dührssen belongs the credit of calling attention to this operation. Any one who has performed either vaginal hysterectomy or fixation cannot but be struck with the ease with which the pelvic organs can be examined through the opening in the anterior vaginal cul-de-sac. Full details of the operation as carried out by Dührssen, Mackenrodt, and the author are given, with short histories of four cases, in the first of which vaginal fixation only was originally intended. The advantages and disadvantages of this mode of treatment are given, also a list of those cases in which this operation seems indicated. A word of warning as to its performance concludes the paper.

Anterior colpotomy may be described as the operation for opening the peritoneal cavity through the anterior vaginal cul-de-sac. As an operation *per se* it has only of late come into prominence, but as an early stage of two other procedures it has been well known for some time. It is the initial step of vaginal hysterectomy and for vaginal fixation (hysteropexy). Priority of claim would therefore be as difficult to confirm as it would be useless to investigate. I believe, however, that A. Martin

(Berlin) * was the first to bring the matter before the profession in this country, although he expressly states in his paper that he is indebted to Dührssen; for he it was who first performed and described the operation in Germany. Martin gives a full account of his methods in a paper published in the 'Monatsschrift für Geburtshülfe und Gynäkologie,' August, 1895, p. 109.

During the performance of either vaginal hysterectomy or fixation, it cannot but strike the operator how very easily in the majority of cases, the uterine surfaces, the tubes and ovaries, and the true pelvis can be explored through the opening in the anterior cul-de-sac; the longer the index finger the more complete the knowledge obtained. Personally, I have always pulled down tubes and ovaries on both sides where possible in total extirpation, and examined them by palpation and inspection, irrespective of their subsequent removal or not.

Operation.—The patient should be prepared as for abdominal section, both as regards diet and attention to the state of the bowels and urine. Hot vaginal douches of 1 in 2000 sublimate solution should be administered twice daily for a week. The steps of the operation itself are sufficiently simple. The patient being anæsthetised and placed in the dorsal decubitus, with the legs flexed and supported by a crutch, the mons Veneris and vulva should be carefully shaved, and then washed with soft soap and water, followed by a solution of 1 in 1000. The vagina should be thoroughly scrubbed with a round-headed brush with a similar solution; this is a precaution particularly to be observed in nulliparous women, in whom the rugæ are usually more marked. Should there be any suspicion of a septic or fœtid uterine discharge the purifying process will be better carried out after curetting, which should be performed by means of a sharp flushing curette

* 'Brit. Med. Journ.,' Jan. 4th, 1896, p. 10. *Vide* also 'Brit. Med. Journ.,' Jan. 11th, 1896, p. 78, for papers by John W. Taylor, and Archibald Donald, read before the meeting of the British Medical Association, July —August, 1895.

after slight cervical dilatation; the uterine cavity being then packed with iodoform gauze. Introducing a Sims' speculum into the vagina, the anterior lip of the cervix is seized by means of a volsella; strong downward traction is exerted upon the uterus by means of it. A transverse or slightly convex incision (the convexity forwards) should now be made by means of a knife or cautery through the mucous membrane over the anterior portion of the utero-vaginal junction. The length of this must necessarily vary; from 2½ to 3 inches should be sufficient. Martin fixes the cervix by means of a combined uterine probe and volsella; he applies another pair of forceps just under the urethral orifice, and placing the anterior vaginal wall on the stretch, makes a *longitudinal* incision into the anterior cul-de-sac. The longitudinal incision is also adopted by Mackenrodt as less liable to injure the ureters. The cellular tissue between the bladder and the cervix being opened up, the index finger or the index and second fingers should be inserted into the opening, and gradually break it down by a series of side-to-side sweeps until the peritoneum is reached; by this means the ureters are pushed aside. The peritoneum should now be cut through with curved scissors. Many recommend a straight retractor to keep the bladder out of the way; my own opinion, based upon personal experience, is that it is not only unnecessary, but hampers the operator. Withdrawing the Sims' speculum for the time, but not removing the volsella, the index finger is inserted into the peritoneal cavity, and the uterus, broad ligaments, tubes, and ovaries can be palpated with great ease: any adhesions may be broken down. Re-inserting the Sims' speculum, the ovaries, tubes, and uterine fundus can be brought through the opening and examined by inspection. If it is considered necessary to remove any of the parts, the broad ligament on one or both sides can be ligatured, and the pedicle cut. The vaginal flaps should be searched for bleeding vessels, and then carefully brought together by sutures. The uterine packing may be removed, and

the vagina stuffed with iodoform gauze. The after-treatment is as for vaginal hysterectomy.

I propose here to give a short outline of four cases in which the above operation was performed; these, with twenty-six cases of total hysterectomy for uterine cancer, are my experience so far of opening the anterior vaginal cul-de-sac and in which the ovaries and tubes were examined.

Case 1.—A single woman, with one child four years of age. She had been under my care for three years with a fixed, retroverted, and subinvoluted uterus, and an enlarged and tender left ovary. Her chief complaints were profuse leucorrhœa (of which there was ocular proof) left-sided pain, and intense dysmenorrhœa for six to seven days preceding the onset of the flow. Temporary relief had been obtained by prolonged rest at three distinct intervals, with curettage twice. As her living depended upon her following her occupation (ironing) I decided to do a vaginal fixation after freeing the uterus from its adhesions.

June 10th, 1895.—I opened the anterior cul-de-sac and found the adhesions at the back of the uterus easily broken down. The patient vomited and strained a good deal under the anæsthetic; as a consequence a piece of omentum and the left ovary came into view. It was this latter phenomenon which first called my attention to the feasibility of examining the ovaries and tubes apart from extirpating the uterus. These organs were inspected, and being found normal, were returned; curettage followed by vaginal fixation was carried out, and the operation concluded. The patient made an afebrile recovery, has since lost her dysmenorrhœa, and the uterus remains anteverted; there is slight increase of frequency in micturition.

The above case seemed to indicate that certain diseases of the pelvic organs might be treated with advantage in this manner, rather than by the abdominal method, which

was frequently followed by intestinal obstruction later in the patient's life, due to the formation of adhesive bands. I called attention to this fact in a paper on "The remote Effects of Peritoneal Adhesions, subsequent on Removal of the Ovaries" ('Lancet,' 1892, vol. ii, p. 607, with figure), and subsequent observation entirely confirms the views there put forward.

Case 2.—A nullipara, aged 30, who had been suffering from pelvic pain dating from an attack of pelvic perimetritis six years previously, and had been under observation during the whole time. I had tried everything without avail, the ovaries remaining fixed and very tender; locomotion was always attended by an exacerbation of the suffering; menstruation was represented by a few hours discharge only. September 25th, 1895, I performed anterior colpotomy. The tubes and ovaries were separated with much difficulty; the right adnexa were found healthy, and were therefore replaced; the substance of the left ovary was much torn, and it was deemed safer to remove it. The patient has up to now been free from pain, and is able to walk about in comfort. It is of course much too soon to form any opinion on the ultimate result of the operation.

Case 3.—A young married lady had been under my care for two years with an enlarged and prolapsed left ovary; it had become fixed, as the result of a local inflammatory attack, eighteen months ago, since which time her sufferings had been much increased. Her chief complaint was the intense pain accompanying sexual intercourse; this I can well imagine, as an ordinary vaginal examination produced considerable pain and general prostration. She was treated by a prolonged period of genu-pectoral posture and sexual abstinence; a soft ring pessary aggravated her pain. I could not make up my mind to recommend any operative measure until the question of anterior colpotomy arose. Thinking this a fair case for

it, on December 16th, 1895, I opened the anterior cul-de-sac, breaking away the left ovary from its adhesions in Douglas's pouch. On inspecting it, it was very hard and irregular, and its surface studded with small cysts the size of a pea; I therefore removed it. The right tube and ovary were quite healthy. The patient made a normal recovery, and has entirely lost her dyspareunia.

Case 4.—A multipara, aged 35, came under my care with a small right ovarian cystoma, the size of a Tangerine orange. On January 22nd, 1896, I opened the anterior cul-de-sac, and brought the tumour down with some difficulty into the vagina. The cyst ruptured during the necessary manipulations; the pedicle was tied and cut, and the operation concluded in the usual way. She made a good recovery.

This method of removing even such a small ovarian cyst as this was to my mind much more difficult than ovariotomy as usually performed, and I do not think I should be inclined to repeat it. Martin says, a tumour up to the size of two fists can be removed by the anterior vaginal incision.

The *advantages* of this method appear to be—

1. No hernia of cicatrix, and less liability of formation of adhesions with the omentum and intestines.
2. Greater simplicity, and performed with greater rapidity.
3. The post-operation sickness is much less, and the convalescence shorter.
4. No bleeding of consequence, except occasionally from the vaginal flaps.
5. No drainage-tube required.

The *disadvantages*, on the other hand, are—

1. Much greater difficulty in making the vagina antiseptic, especially if there be any fœtid uterine discharge.
2. Greater risk of wounding the bladder, ureters, and coils of intestines.

3. If the swelling is adherent in the left and posterior quarter of the pelvis, the rectum may be lacerated.

The cases which appear to be suitable for this operation are:

1. Chronic ovaritis, with adhesions, and accompanied by much pelvic pain.
2. Early unruptured tubal gestation.
3. Small ovarian and dermoid cysts.
4. Adherent retroverted uterus, with subsequent performance of vaginal fixation.
5. Small fibroids on anterior or fundal surfaces.
6. Small intra-ligamentous and parovarian cysts.

The patient must have a normal pelvis (neither flattened nor of male type), and a fairly distensible vagina; the thinner the patient, and the broader the pelvis, the easier the operation. It is certainly unsuitable in—

1. Large ovarian or fibroid tumours.
2. Old-standing pyosalpinx with adhesions.
3. Extra-uterine gestation at or after rupture.
4. Pelvic abscess pointing upwards on to abdominal wall.

With regard to recommending the operation, it must be borne in mind, firstly, that the peritoneal cavity is opened, with its possibly grave after results; and secondly, that removal of the ovaries and tubes whether by vagina or abdomen, must always be looked upon as a mutilation, and hence the same care and anxious thought should be exercised as before resorting to abdominal section. If this precaution be neglected, nothing but abuse of an otherwise valuable procedure will result.

Dr. Amand Routh was glad that the author had brought forward this important subject. There was little to criticise in his remarks, but much to commend, especially in the warning added to the paper against performing the operation in cases best dealt with by other means. He thought that the two difficulties of the operation were the separation of the bladder, and

the turning out of the uterus. As regards the former, he believed that a combined transverse and longitudinal vaginal incision gave the best results, both as affording more room, and as permitting the bladder to be displaced upwards out of the way of the operator. It was not always easy to turn out the uterus, and he had found that the best way was to antevert it *per rectum*, or by a uterine repositor fitted with a rack and screw. To retain the uterus outside, whilst further steps were being taken, especially when vaginal fixation was going to be done, he advocated passing ligatures through the uterine tissue, and holding the uterus steady with them, rather than fixing it with a volsella, which was apt to tear the tissues.

Mr. Malcolm said he considered that the difficulty of keeping the vagina aseptic was a very serious objection to this plan of treatment. The removal of intra-peritoneal disease by anterior colpotomy could only be performed in the simpler cases. As these cases had practically no mortality when operated on through the anterior abdominal wall, it did not appear that treatment through the vagina could improve the results of the operation.

The President, referring to the indications for the operation mentioned by Dr. Phillips, said that in his opinion the cases which would be easily performed from below would be generally such as did not require operation. Where there were adhesions it seemed to him rather risky to separate these without the chance of sight. An early unruptured tubal gestation was extremely easy to remove in almost all cases ; but here the difficulty lay in the diagnosis, and generally a better view could be got from above. Small ovarian and dermoid cysts were much in the same case. As regarded the liberation of a retroverted adherent uterus with subsequent vaginal fixation, that depended upon the advisability of such an operation *per se* rather than on the particular mode of its performance, and was hardly to be discussed incidentally; again, small fibroids on the anterior or fundal surfaces generally required no treatment. They were subperitoneal and small, *ex hypothesi*. A fibroid causing bleeding (that is, not subperitoneal), or pressure symptoms (that is, large), could not be safely treated thus. Small intra-ligamentous and parovarian cysts, as well as pelvic abscess pointing below, were treated often best from below, but were diagnosed best from above ; a combination of the two methods might sometimes be best. In the case of pelvic abscess, however, it was probably safer to open it without disturbing the peritoneum. With regard to Mr. Malcolm's remarks on the greater safety of abdominal than of vaginal section it must be remembered that, as far as sepsis was concerned, vaginal section was one of the safest proceedings in surgery, as shown by the results of vaginal hysterectomy.

CASE OF DERMOID OVARIAN CYST IMPACTED IN THE PELVIS WHICH WAS REMOVED BY ABDOMINAL SECTION DURING THE NINTH MONTH OF PREGNANCY.

By Thomas H. Morse, F.R.C.S.Eng., Norwich.

A multipara, aged 30, whose last labour had occurred rather less than two years before and had been quite natural, was again pregnant, and as far advanced as the end of the eighth month, when Mr. C. E. Muriel, under whose care she was, discovered that the pelvis was almost completely blocked with a semi-solid tumour, and that the os uteri could only with great difficulty just be reached with the index finger passed up close behind the pubes. Examination by the rectum showed that the tumour was not attached to the sacrum, but appeared to be firmly fixed in the pelvis.

Delivery being impossible, I proposed to remove the tumour by abdominal section, and if possible to get the wound soundly healed before labour commenced.

On November 6th, 1895, the patient having been moved to the Surgical Home in this city, ether was administered by Mr. C. J. Muriel. Mr. C. E. Muriel and Mr. Warlters assisting me, I made an incision eleven inches long in the middle line, the centre of the incision being at the umbilicus, and drew out the whole fundus of the pregnant uterus; then by passing my hand in behind the uterus nearly as far as my elbow I could feel the tumour firmly fixed by adhesions in Douglas's pouch; these were by degrees torn through all round, and then by passing my hand beneath it I lifted the tumour out of the abdomen; it was the right ovary, and was just large enough to completely fill the pelvis. The pedicle was three inches long, and was twisted upon itself one whole turn from left to right. This was ligatured and the tumour cut away. The uterus, which had been outside the abdomen

for a space of about five minutes, had been carefully kept wrapped up in hot sponge cloths, and was now replaced with some difficulty, as there did not appear to be skin enough to cover it; however, by dragging upon the two sides of the abdominal wound it was eventually accomplished, and the wound united with twenty-one sutures, the whole operation lasting twenty-five minutes.

On opening the tumour it proved to be a dermoid cyst containing hair and sebaceous matter, with some blood and pus, the walls becoming gangrenous, and I have no doubt but that it would have burst during labour.

The patient made an uneventful recovery, and normal labour followed twenty-five days later, Mr. Muriel applying the forceps to prevent unnecessary strain on the recent cicatrix. The child was living and of full size, and for the second time both mother and child made an uneventful recovery.

Dr. Boxall asked whether pigmentation of the cicatrix had been observed. He had recently operated for the removal of a dermoid ovarian cyst during labour, and was surprised to find not only that the scar in the middle line but the marks of the stitches on either side of it also were becoming pigmented.

JULY 1st, 1896.

F. H. Champneys, M.A., M.D., President, in the Chair.

Present—31 Fellows and 5 visitors.

Books were presented by Mr. A. W. Hutton, Dr. Eden, Professor Kleinwächter, and the Cincinnati Hospital Staff.

Sidney Edward Barrett, B.A., M.B., B.C. Cantab., was admitted a Fellow of the Society.

James Keogh Murphy, L.R.C.P. (Kilgobbin, Ireland), was declared admitted.

Mark Sharman, M.B., C.M.Glasg. (Rickmansworth), was elected a Fellow.

MICROSCOPICAL SECTIONS OF UTERUS SHOWING CHORIONIC VILLI AND DOUBTFUL SARCOMA.

Shown by Leonard Rempry, M.D., B.C.

The specimens were illustrated by two coloured plates, one representing what appeared to be sarcoma, and the other well-marked chorionic villi.

The patient was admitted to St. George's Hospital on June 7th, complaining of hæmorrhage for seven weeks,

and gradual but considerable loss of flesh. Her last child was born on January 21st, 1895, and had been suckled continuously till admission, that is, sixteen and a half months. The bleeding began towards the end of April, 1896, gradually. No pregnancy had been suspected, and both the patient and her doctor were quite convinced that there was no abortion before or during the loss of blood. The hæmorrhage went on for three weeks to a moderate degree, then became greater and floodings were of constant occurrence—facts compatible with the presence of some growth in the uterus.

On vaginal examination the os was large, admitting the finger, so that a mass the size of a strawberry could be felt. Dilatation allowed a more complete investigation, and the mass was found not to have a distinct pedicle, but to be continuous with a flattened excrescence situated only on the posterior wall of the uterus, rising very nearly to the summit of the fundus. The whole mass was removed by curetting. Examination by the microscope indicated that there was sarcoma and also placental remains present in the scrapings. On this report the uterus was removed by vaginal hysterectomy a few days after. The evening of the meeting was the thirteenth day, and the patient was stated to be convalescing comfortably.

Dr. Remfry proposed that further investigation of the specimens should be referred to a committee, as there had not been time to make a more complete report.

Dr. Eden said he had no doubt that the structures shown in Dr. Remfry's specimens were chorionic villi. There was never any difficulty in recognising chorionic villi embedded in blood-clot when they were fresh, but there might be difficulty when they were old. Occasionally rings of fibrin were found to bear a superficial resemblance to villi, but the latter could always be distinguished by attending to two points, viz. the presence in them of traces of the plasmodial covering, and of the characteristic connective-tissue stroma. It was remarkable that villi which had been apparently retained in the uterus for eighteen months should be relatively so well preserved.

THE ÆTIOLOGY OF GONORRHŒA.*

By Frederick John McCann, M.B., C.M.Edin., M.R.C.P.Lond.,

PHYSICIAN TO OUT-PATIENTS AT THE SAMARITAN FREE HOSPITAL FOR WOMEN AND CHILDREN.

Part I.

(*Abstract.*)

In the following paper previous observations have been examined, and an attempt made to throw additional light on this complex question.

Many workers have confined their attention chiefly to one group of cases, or have drawn conclusions from a single case—methods which are eminently fallacious.

As a true understanding can only be arrived at by studying the gonococcus as it occurs in the discharges, abscesses, and the like in the male suffering from gonorrhœa, in the female, and in the eyes of the newly born, together with cultivation and inoculation experiments, an investigation has been carried out on these lines, the results of which are detailed in these papers.

Method of Investigation.

1. Description of the platinum needle used to obtain pus.
2. Cover-glasses and cover-glass preparation.
3. How to obtain the pus.

Form of the gonococcus.—A diplococcus, each half bean-shaped or reniform, concave surfaces looking towards one another. Generates by fission. Highly refractile envelope.

Size of the gonococcus.—The majority measure over 1 μ in length. Size not of much importance as an aid to diagnosis.

* This paper was illustrated by lantern slides and photo-micrographs.

Action of staining reagents.—Fuchsin the best stain: (1) rapid action; (2) small risk of over-staining; (3) strong solutions may be used. Contrast stains; alcoholic solution of eosin and methylene blue give good results. Eosinophile bodies. Gram's method not a conclusive test. Diplococci simulating the gonococcus.

The detection of gonococci in the tissues of the host.—Method of preparing and staining sections. The essential points to be remembered in staining specimens, whether cover-glass preparations or sections, are—(1) Use fresh staining reagents. (2) Filter all stains before use. (3) Allow specimens to stain for a definite time until sufficient experience is gained to differentiate the exact colouration required.

The relation of the gonococcus to the pus cells.—Gonococci are seen lying free either in colonies or as separate and distinct diplococci. They never form chains. They surround the pus cells and lie on their surface. The greater number are contained within the pus cells. Arrangement in relation to the nucleus not characteristic as stated by Bumm and others.

The gradual process of pus-cell destruction is traced and described in detail.

The relation of gonococci to epithelial cells; and the stages of epithelial cell destruction.

Parts affected by the gonorrhœal poison in the male and female. Gonorrhœal ophthalmia.

The occurrence of true *gonorrhœal vaginitis;* pregnant women especially liable to be thus affected.

The *vulvo-vaginitis* of infants and children. Convenient classification:—(1) Gonorrhœal; (2) non-gonorrhœal. The special organism of infantile vulvitis.

Gonorrhœal arthritis—Theory of mixed infection.—Reasons for accepting this theory.

"*Latent gonorrhœa.*"—Explanations of the chronicity of gonorrhœa in the female.

The sound and other instruments as causes of the upward spread of the gonococcus, ending in implication of the Fallopian tubes and ovaries.

The diagnostic importance of the presence of the gonococcus.—Is this organism the cause of the disease known as gonorrhœa?

Recognition of the gonococcus by the aid of the microscope.

1. Form: Not characteristic. Size: Not reliable.

2. Action of staining reagents. Useful as a confirmatory test. Value of Gram's method.

3. Arrangement of gonococci in relation to the pus-cell nuclei.

(Although no one of these three signs is characteristic, yet when they occur together there is strong presumptive evidence that we are dealing with the gonococcus.)

4. Gonococci are present in the pus of every untreated case at some period.

5. Secretion free from gonococci does not cause a gonorrhœal inflammation.

6. Secretion containing gonococci even in small quantities affects sensitive mucosæ with absolute certainty.

If no gonococci be found we cannot say the disease has not been gonorrhœal. Value of clinical evidence.

Before concluding that gonococci are absent from a discharge, certain sources of error must be avoided.

1. Small, ill-developed examples may be observed (Involutionsformen).

2. Owing to the scarcity of gonococci in the pus, they may be overlooked, especially where only one or two preparations are made.

3. Where numerous other organisms are present, *e. g.* in pus from the cervix uteri, the gonococci may be hidden.

4. The gonococci may be embedded in the mucosa, appearing only at intervals in the secretion.

The practical importance of Neisser's discovery. Medico-legal aspects.

Methods of cultivating the gonococcus are fully detailed.

Inoculation experiments are added.

Introduction.

The discovery by Neisser in 1879 of a characteristic organism in gonorrhœal pus stimulated observers in this country and abroad to devote their energy to this special field of pathological inquiry. Although numerous workers

in Germany have advanced our knowledge of the subject by their painstaking investigations, still more requires to be elucidated before we can arrive at definite conclusions.

Scepticism has done much in the past to moderate the views and teaching of the enthusiastic bacteriologist; yet the objections of those who profess total ignorance of the subject of bacteriology, and who have never endeavoured to become acquainted even with the elements of the science, have had a deterring influence on useful methods of inquiry and upon investigators whose opportunities for research are limited.

The value of examining for bacteria in discharges as an aid to more complete diagnosis is becoming universally recognised. In cases of supposed gonorrhœa great assistance may be obtained from a microscopic examination of the discharge, and it is well, especially in the female, to employ this test before definitely stating that a discharge is gonorrhœal in character.

Method of investigation.—In order to study the gonococcus in detail it is necessary to obtain specimens from pus in which gonococci are present in large numbers and free from other pus organisms. An acute gonorrhœa of the male urethra on the second or third day of the attack furnishes the best examples. Having become acquainted with the form, size, &c., of the gonococcus, we can then study the organism as it occurs in the discharges from the female genitalia, and from the eyes of the newly born.

For the microscopic work it is necessary to procure an oil immersion lens and to have an Abbé's condenser fitted to the microscope. I have always used a Zeiss microscope with a 2 $\mu\mu$ oil immersion lens. The following method has given the best results in examining pus to detect the presence of gonococci.

Clean a series of cover-glasses by washing in nitric acid, followed by distilled water; then dry. Obtain a platinum wire and a glass rod. Heat one end of the rod till it is soft and insert the wire into it; then curve

the free end of the wire into a small loop. The wire must be sterilised each time before use by heating to a red heat over a spirit lamp.

Before obtaining pus from the male urethra the glans and prepuce should be cleansed with a suitable antiseptic. The patient is then directed to squeeze the urethra. After rejecting the first drop of pus the next is collected on the loop made on the end of the platinum wire. The pus is transferred to a cover-glass, a drop being placed on the centre; another cover-glass is laid on the top, the two are pressed together and rapidly separated. As a result each cover-glass is covered by a thin layer of pus. In order to dry the glasses and coagulate the albumen pass each one two or three times through the flame of the spirit-lamp.

The specimen may be stained at once, or if desired, the cover-glasses can be kept in a pill-box to be stained when convenient. Specimens so prepared keep for an indefinite period, which is a great boon to those busily engaged in practice. A similar method is adopted with discharges from the eyes and the genitalia in the female. To stain the specimen it should be dipped into the staining solution contained in a watch-glass, then washed in distilled water; after removal the excess of fluid is got rid of with bibulous paper. The cover-glass after drying is mounted and examined.

Form of the gonococcus.—The gonococcus is classified under the subdivision Diplococci. In unstained specimens under the microscope the gonococci are seen as punctiform rounded bodies, glistening and highly refractile when contrasted with the protoplasm of the pus cells. With a good lens the division between the individual cocci may be distinguished. These points are best shown after the addition of acetic acid to the specimen. When appropriate stains are added, the organisms, differentiated from their surroundings, may be studied in detail. Careful focussing demonstrates that the cocci are divided into two separate halves by a bright line. Each half is bean shaped or

reniform, the concave surfaces looking towards one another. Further observation shows that the halves are again subdivided into two. The generation of gonococci is by fission, the various stages of which can be traced in well-stained preparations.

Each diplococcus is seen to be surrounded by a highly refractile envelope, which may be noticed to be dividing, probably preliminary to the division of the coccus.

As is well known, bodies suspended in a fluid are surrounded by a halo when seen under the microscope, *e. g.* particles of dirt or staining material; however, after prolonged and careful examination, I am inclined to regard this refractile envelope surrounding the gonococci as a definite structure and not an optical appearance. When several gonococci are collected together to form a colony there seems to be a coalescence of the individual envelopes so as to form a zooglœa mass. In some colonies, however, the gonococci are so closely packed together that this appearance is not well marked, so that it is possible mucus may have collected around the colonies. We cannot dogmatise over appearances so open to fallacy.

Size of the gonococcus.—Great prominence has been given by some writers to the size of the gonococcus as a diagnostic test. Bumm * using a Zeiss objective (homog. immersion $\frac{1}{18}$) with an eye-piece micrometer, measured a series of gonococci and gives the following:

"*Large diplococci.*—Length from pole to pole, 1·6 μ; breadth in the centre, 0·8 μ.

"*Very small diplococci*, division only slightly marked.—Length from pole to pole, 0·8 μ; breadth, 0·6 μ.

"The majority measure over 1 μ in length."

Other observers have fallen into error through measuring a single coccus. As the organism called the gonococcus is a diplococcus such results are worthless. The diagnostic aid afforded by the size of the gonococcus is open to many objections. The size of the gonococci

* Der Mikro-Organisms der Gonorrhoischen Schleimhaut-Erkrankungen, 1885, Wiesbaden.

seems to vary with the age, the younger forms being small. Heat has an important effect in causing the cocci to shrink, a result also brought about by absolute alcohol in excess. Gonococci absorb some stains more readily than others, thereby increasing their size. With so many sources of error we must conclude that the size of the gonococcus is of little value as a factor in diagnosis. Measurements of the size can be easily obtained by using an eye-piece micrometer to the microscope.

Action of staining reagents.—The gonococcus, in common with other diplococci, readily absorbs aniline dyes. These should be used in weak solution. Various authors have obtained good results from a particular stain or group of stains. The result depends in great part on the degree of care exercised during the staining process and the amount of experience in this department.

It is well for the beginner to allow the preparation to lie in the staining fluid for a definite time. With experience he will be enabled to determine the exact degree of colouration required.

Fresh staining fluids should be used, and each one filtered before use. The omission of the latter precaution may spoil valuable specimens where the reagents are contaminated with dust.

I have obtained the most uniformly successful results from the use of a solution of fuchsin composed as follows: Fuchsin, 2 gr.; alcohol, 20 c.c.; water, 100 c.c.

The advantages of fuchsin are: (1) rapidity of action; (2) small risk of overstaining; (3) strong solutions may be used.

The fuchsin solution having been filtered into a watch-glass, the cover-glass preparation is allowed to remain in the solution for *thirty seconds* or even less. The cover-glass is then removed and transferred to a watch-glass filled with distilled water until the excess of the stain has been dissolved away. On withdrawal of the specimen the superfluous fluid is soaked up by means

of bibulous paper, and it is allowed to dry. When dry the cover-glass is mounted with xylol balsam and examined.

If ordinary Canada balsam be used the colouration is apt to fade. With xylol balsam, on the other hand, the stain is preserved for an indefinite period. A small drop of balsam should be used for mounting. This method is so rapid that a complete examination of a purulent discharge can be made at once, and as there is little risk of overstaining, the first trial may be attended with good results. Gonococci so stained are sharply defined, the clear space between the cocci is well shown, and the bean-shaped appearance of the two halves. Many other staining reagents cause the cocci to swell, so that the slight concavity in their opposed surfaces together with the division between the two halves of the gonococcus cannot be distinguished. Fuchsin is, in my experience, the most useful stain for clinical purposes. Methylene blue, methyl violet, dahlia, and gentian violet may also be used in weak solutions. With these the risk of overstaining is avoided by thorough washing in distilled water until that depth of stain is obtained which former experience has shown to give the best results.

In order to show the elements contained in the cells, double staining may be employed, which with a little practice gives excellent results.

As a contrast stain a concentrated alcoholic solution of eosin * occupies a prominent place. The method of use is as follows:

Treat the cover-glass preparation for several minutes with the eosin solution. The stain comes out better if gentle heating be applied, care being taken not to overheat the specimens, as this entirely vitiates the result. Remove the superfluous fluid with bibulous paper and re-stain for fifteen seconds in a concentrated alcoholic solution of methylene blue; wash in water.

Effect.—The gonococci are blue on a red ground, the

* Fraenkel, 'Bacterienkunde,' p. 449.

cellular elements of the pus have been stained with the eosin, whilst the nuclei and micro-organisms remain blue. The relation of the gonococcus to the cells, &c., can be well studied in specimens coloured by this method.

Another excellent contrast stain may be obtained by using a solution of safranin.* Stain the preparation for eight to ten minutes in carbol methylene blue, wash with water, dip for three seconds into dilute acetic acid (five drops acid. acet. dil. in 20 c.cm. water), wash thoroughly with water. The gonococci are alone stained. For contrast stain a weak watery solution of safranin is used, being allowed to act until the colouration becomes noticeable. Wash again in water, dry and mount in balsam. The gonococci are dark blue, pus cells and nuclei salmon-coloured.

Note.—Methylene blue stains gonococci darker than the cell elements. Hueppe ('Methoden der Bacterien Forschung,' pp. 135 *et seq.*) states that gonococci are best stained with pararosanilin, in anilin water, thymol water, or carbolic acid solution.

For differentiating the gonococcus the method suggested by Gram is used.

To obtain reliable results the materials employed should be freshly prepared. Filter a quantity of anilin water twice into a watch glass. Add drop by drop a concentrated alcoholic solution of gentian violet (filtered) until precipitation commences. Stain specimens in this solution from ten minutes to half an hour. Transfer to Gram's solution (iodine 10 parts, iodide of potassium 20 parts, water 3000 parts) for five minutes; here the dark blue violet is replaced by a dark purple red. Wash in alcohol until the colour is almost completely removed. Wash in water for a few seconds, dry, and mount.†

During the staining process the specimens can be

* "Schütz ein Beitrag zum Nachweise der Gonokokken," 'Münch. med. Woch.,' 1889, No. 14.

† 'Fortschr. d. Med.,' 1884, No. 6; Roux, 'Compt. Rend.,' 1886, No. 103, p. 899.

examined under a lower power to observe the action of the stains. This method may be employed with advantage during any staining process before the cover-glass preparation is permanently fixed. The effect of Gram's stain is that the gonococci remain unaffected, other pus organisms being stained a deep purple. Beautiful contrast stains may be employed after the specimens have dried, the effects of which are to bring the differential stain into greater prominence.

Steinschneider and Galewski ('Berlin. klin. Woch.,' 1890, No. 24) recommend re-colouring with dilute Loeffler methyl blue in order to distinguish gonococci from other diplococci. Gonococci are bright blue; other diplococci darkly stained.

A watery solution of vesuvin may also be used, which stains the gonococci brown. Eosin is useful as a contrast stain after Gram's method.

Wertheim * used as a contrast stain a very dilute solution of fuschin. He states that this stain is not taken up by the *Staphylococcus pyogenes*. The cultivation test is, however, preferable. After the action of the eosin stain, eosinophile bodies present in the pus cells are well shown.

Nesser † stated that gonococci were stained with strong eosin solution. My own experience tends to show that this stain being taken up so slightly is of little value. Is it possible that the eosinophile bodies were mistaken for gonococci? In 1879, the date of Neisser's original work on this subject, the presence, relations, &c., of eosinophile bodies had not been described.

Caneva ("Sulle Cellule Eosinophile del pus Gonorroica," 'La Rif. Med.,' 1894, No. 25), in a specimen of gonorrhœal pus stained only with a concentrated alcoholic solution of eosin, describes two varieties of eosinophile cells:

1. Mostly uninuclear, the granules of the size of gonococci. These are found in small numbers in acute gonorrhœa.

* 'Centralbl. f. Gynäkologie,' Bd. xlii, 1892.

† 'Centralbl. f. d. med. Wissenschaft,' 1879, No. 28.

2. Contain very fine, partly punctiform, partly rod-like granules, with one or several nuclei. These cells occur in large numbers in the acute form. If the eosin colouration be followed by the use of concentrated methyl blue, the appearance is at once changed. The formerly rose-coloured gonococci are stained deep blue, allowing themselves to be easily distinguished from the first variety of eosinophile cells. If the methyl blue be allowed to act more than five minutes the colour is removed entirely or partly from the second variety of eosinophile cells. The decolorisation is accelerated by the addition of carbolic acid or alcohol. Gonococci are only enclosed in the cells of the second category, not in those of the first.

Posner and Lewin ("Farbenanalytische Untersuchungen über Gonorrhoischen Eiter.," 'Dermatolog. Zeitschrift,' Bd. i, 1894, Heft 2) conclude that the eosinophile granules are only in the cell body, not in the nucleus. Their size and distribution vary in the same specimen; some are diffusely situated in the cell body, others are grouped around the nucleus.

The eosinophile cells are mostly polynuclear, and their nuclei colour very slightly with methyl blue.

1. The number of the eosinophile cells in the pus at the beginning of an acute gonorrhœa is much diminished in comparison to those contained in the blood.

2. The quantity reaches its highest point in the third week.

Wertheim (op. cit.) states that only young gonococci are stained by watery anilin colours, while old gonococci do not imbibe the staining fluid. Old gonococci lose their typical forms, and thus changed we no longer recognise them as gonococci. They become granular spheres, variable in size and indefinite in outline.

Several writers mention that the degree of absorption of the staining fluid by the organisms (gonococci) is an index of their age, *e. g.* if methyl blue be used alone and in weak solution, the young gonococci only are stained while the older ones remain unstained. This statement is difficult to prove or disprove.

As there are several diplococci resembling gonococci in appearance, Gram's method of staining was at first supposed to afford conclusive proof. Although this is not the case, still the method is important as a confirmatory test.

Bumm * describes five varieties of diplococci which may be confounded with the gonococcus.

1. A citron yellow diplococcus, not pathogenic. It has been observed growing on gelatine exposed to the air, and in purulent discharges from the urethra and conjunctiva. It is distinguished by the citron yellow growth on gelatine. It grows at the ordinary room temperature, and liquefies blood serum and gelatine. The form under the microscope resembles that of the gonococcus. Inoculation of cultures gave no result.

2. A milk white diplococcus, not pathogenic. Chiefly found in the lower portion of the vagina in puerperæ, less frequently in the cervix. Easily cultivated on gelatine, which is liquefied.

3. A yellow white diplococcus, pathogenic. This organism was found by Bumm in two cases of vesical catarrh in puerperæ. Cultures at first whitish grey, after some days have a yellow appearance. Blood-serum and gelatine are both liquefied. In contradistinction to the other diplococci described by Bumm, including the gonococcus, the yellow white diplococcus remains dark blue after the action of Gram's method. Inoculation experiments on mucosæ liable to gonorrhœal inflammation gave negative results. Injections under the human skin caused abscess formation, the organism being present in the pus, and in the tissue around the abscess.

4. A greyish-white diplococcus, not pathogenic. Found in vaginal secretion. Liquefies gelatine to a small extent.

5. A rose-coloured diplococcus, not pathogenic. Observed growing on gelatine exposed to the air, and distinguished from other organisms by its colour. Liquefies gelatine after some time and only to a small extent.

It will be seen that all the foregoing varieties of

* Op. cit.

diplococci in their growth liquefy gelatine. The gonococcus does not grow on gelatine and does not liquefy blood serum.

The Detection of Gonococci in the Tissues of the Host.

Owing to our inability to isolate the gonococci embedded in the tissues and to obtain cultivations, the most valuable proof of their identity is not available. This seems to have been ignored by several foreign writers, who from microscopic observation alone consider themselves justified in stating definitely that the cause of the morbid condition observed is the gonococcus. In the present state of our knowledge such pronounced statements must be received with caution.

Bockhart made sections of the urethra of a paralysed male patient, who died on the tenth day after being inoculated with gonorrhœa.

Welander examined scrapings from the male urethra. No systematic investigation had been made until Bumm examined the conjunctivæ of new-born infants affected with gonorrhœal ophthalmia. The specimens were hardened in absolute alcohol, embedded in paraffin, and serial sections cut. To stain gonococci in the tissues only powerful stains are useful, *e. g.* fuchsin and methylene blue. Watery solutions of methyl or gentian violet act so slightly that the organisms are not shown. The best results are obtained by using a strong solution of methyl violet in anilin or toluidin water.

The stain should be prepared fresh by allowing several drops of a concentrated alcoholic solution of methyl violet to be filtered into a watch-glass containing toluidin water. The preparations should remain half an hour in this solution. A longer immersion gives no better result and renders the decolourising more difficult.

Great care must be taken when the tissue is transferred to alcohol. If the alcohol has not acted enough it is difficult to distinguish the cocci from the dark nuclei; if too

much, the gonococci lose their stain. The same difficulty is met with when alcohol is used in the staining of cover-glass preparations. No definite rules can be laid down; experience will tell when the immersion should be discontinued. The specimens should be cleared up in clove oil and mounted in Canada balsam from which all the chloroform has been previously driven off by heating. Bumm found that the organisms penetrate between the epithelial cells of the conjunctiva and not into the cells.

Wertheim * recommends the following method for staining sections. Three to five minutes' immersion in gentian violet anilin water, remove superfluous fluid, transfer for about one minute to Lugol's solution, then into 95 per cent. alcohol, where the sections remain until they have a slight purple tint; if kept too long all the colour would be removed. Stain in aqueous solution of methyl blue for several minutes, wash in water and then in absolute alcohol, clear in bergamot oil and mount. The difficulty of this method, as with the previous, is to know the exact time the preparations should remain in alcohol.

Directions for hardening tissues are given by Leyden,† who investigated a case of supposed gonorrhœal endocarditis. Eighty-six per cent. alcohol was first used, then 96 per cent., followed by embedding in celloidin. Sections were kept in 70 per cent., alcohol, changed every second day.

The essential points to be remembered in staining specimens, whether cover-glass preparations or sections, are:

1. Use fresh staining reagents.
2. Filter all stains before use.
3. Allow specimens to stain for a definite time until sufficient experience is gained to differentiate the exact colouration required.

By attention to these details much valuable time will be gained, and many failures avoided.

Relation to the pus cells.—In order to study the relation

* Op. cit.

† 'Deutsche med. Woch.,' No. 38, Sept., 1893.

of the gonococcus to the cells it is desirable to procure well-stained specimens. I have obtained the best results from those stained with fuchsin. The number of gonococci in a specimen varies according to the stage of disease, being most numerous on the third or fourth day, and then gradually diminishing until pus organisms alone are present. This can be verified by examining preparations from a case where suitable treatment is being applied. It is well, then, in order to procure typical examples of the gonococcus, that preparations be made from cases of acute gonorrhœa affecting the male urethra during the third or fourth day of the attack. When dealing with the female genitalia, so many other organisms are present that considerable experience is required to differentiate the gonococci.

In cases of gonorrhœal ophthalmia pus organisms are frequently found in the secretion which collects round the margins of the eyelids.

We have, then, this important fact to bear in mind,—that in the majority of cases, during the early stages of disease gonococci only are present. From this it follows that the discharge is most infectious during this period. In the later stages pus organisms gradually make their appearance, and finally total disappearance of gonococci occurs.

Preparations made from the early stages of acute gonorrhœa show the cell relations. Gonococci are seen lying free either in colonies of varying size or as separate and distinct diplococci. Careful examination of the colonies shows the diplococcus form of the individual organisms. Gonococci never form chains. They are seen surrounding the pus cells and lying on their surface. The greater number, however, are contained within the pus cells, being sharply limited by the cell wall. They are alleged to push the cell nuclei to one side, but it should be remembered that many of the nuclei are originally situated towards the periphery of the cells. The gonococci are situated chiefly around the nucleus;

where, however, the nuclei are close to the cell-wall this arrangement does not obtain. Many pus-cells may be seen packed full of gonococci, no doubt causing enlargement of the cell-wall. As this packing of the cell more clearly defines the boundary, a cell may appear enlarged when in reality this is not the case. That enlargement does occur, and to a well-marked extent, is shown where actual bursting of the cell-wall takes place with escape of gonococci.

It is probable that pus cells implanted on a virgin soil burst, this being followed by the escape of the gonococci, which have previously increased in number. In this way I am inclined to think infection occurs; doubtless in addition free gonococci are introduced at the same time. The distribution of the gonococci around the nucleus is stated by Bumm to be characteristic. This statement may be disproved by studying the diplococci contained in the pus from cases of vulvitis in children (not gonorrhœal) where a precisely similar arrangement is noticed. It is more correct to say that the gonococci are situated in that portion of the cell not occupied by the nucleus. As previously stated, where a nucleus is situated close to the cell-wall, gonococci are not seen between nucleus and cell-wall; but should there even be a small space left, gonococci are noticed occupying it. Some cells contain few gonococci; others are so well filled that it may be difficult to make out the position of the nuclei.

The nuclei of the pus cells vary in number and position. In some pus cells they give rise to a horse-shoe shaped appearance, and in these the gonococci are grouped as if occupying a central position.

The gonococci lying free in the specimen occur singly (diplococci) in groups of four, like sarcinæ, or in colonies. The highly refractile envelope may be seen, and occasionally the process of division commencing in that envelope. Where colonies are formed these envelopes coalesce. The absence of chain formation helps to distinguish gonococci from many other pus organisms.

Where gonococci have invaded a cell, it will be observed that that portion of the cell does not absorb the staining reagent. It is possible, then, that a condition of local death is produced as a result of the action of these microbes. Moreover, pus cells containing even a few gonococci are not so well stained as those in which none are present. In cells which have burst and from which the gonococci have escaped, the remaining protoplasm does not absorb the stain. Vacuolation of the cell-protoplasm may also be observed, with gonococci contained in the vacuoles.

The formation of vacuoles is a sign, well known to pathologists, of the decay of a cell. Here the vacuolation is presumably due to the action of the gonococci. A fallacy may occur through the organisms being pressed into the vacuoles during the preparation of the specimens.

It is possible that one or two gonococci lying on the surface of a cell surrounded by their highly refractile envelope might be mistaken by the inexperienced for a vacuole containing gonococci; true vacuolation may, however, occur at a later stage.

In the early stages of the disease, *e. g.* the third or fourth day, specimens from the discharge are found to contain gonococci in large numbers with few pus organisms present. In many acute cases examined I was unable to find any pus organisms. Numerous pus cells are seen packed full of gonococci, while colonies of varying size lying apart from the cells are scattered throughout the specimen.

In these acute cases the observer is at once impressed with the large amount of epithelium present in the specimen. This is an evidence of the irritation caused by the poisonous action of the microbe on the urethral mucosa, resulting in a copious shedding of the epithelial lining. Many epithelial cells in preparations from the male urethra are of the squamous variety, this being an additional sign of irritation.

It may be argued that these cells come from the

squamous epithelium of the glans penis, but this source of error was borne in mind when the pus was collected; moreover, their number is too large to be derived from this situation alone.

During the early stage of the disease the number of gonococci lying free is greater than in the later stage. As the disease proceeds to a natural cure the number of gonococci gradually diminishes, while the number of pus organisms gradually increases until the latter only are found, and are present until the discharge ceases.

A large number of gonococci is never seen in conjunction with a large number of pus organisms.

Relation of the Gonococci to the Nuclei of the Pus Cells.

That the gonococci never penetrate the nuclei of the pus cells was originally stated by Neisser and confirmed by all the subsequent writers on this subject, Bumm stating that this was characteristic of the gonococcus. A careful study of the cell changes produced by the action of the gonococcus shows that this statement is inaccurate.

In the majority of the pus cells the gonococci are situated around the nucleus as previously noted, and some lie on the surface of the nucleus. When death of the cell occurs as a result of the destructive action of these organisms (gonococci) it can be seen that the nucleus is penetrated and broken up previous to the complete disintegration of the cell. As the nucleus is the last portion of the cell to die, being the most resistent part, a result such as this would be expected when a pus cell was attacked by a destructive agent.

Careful examination of a series of well-stained specimens will reveal the changes brought about in the nucleus ending in its complete destruction.

Minute observation of a pus cell invaded by gonococci will show that these microbes clustered around the nucleus are exerting a destructive action on the nuclear substance. This is evidenced by the punched-out appearance of the

edges of the nuclei, with gonococci lying in the minute concavities thus produced. The nuclear edges appear as if worm-eaten. Vacuolation of the nuclei is also seen, which must not be confounded with the meshes of the intra-nuclear network. A nucleus riddled with vacuoles may occasionally be noticed, gonococci being contained in the vacuoles. Penetration of the gonococci into the nuclear substance, followed by disintegration, complete the process. Degenerating nuclei are less deeply stained.

Well-marked vacuoles not containing gonococci can be demonstrated, together with broken-down nuclei which do not exhibit gonococci in their substance.

It may be mentioned that pus organisms and gonococci have never been observed in the same pus cell. The former (pus organisms) are most abundant in the neighbourhood of the epithelial cells, many clinging to these cells.

Relation of Gonococci to Epithelial Cells.

Bumm has definitely stated that gonococci do not penetrate epithelial cells. Although others have suggested that the gonococci may penetrate epithelium, yet sufficient evidence has not been brought forward.

In his observations on the conjunctiva and cornea of the new-born, Bumm describes and figures how the gonococci penetrate between the epithelial cells into the subepithelial connective tissue.

Prolonged examination of the epithelium contained in the discharge from a case of gonorrhœa of the male urethra in the early stages will detect the changes produced.

Here we observe the gradual invasion of the cells by gonococci. The epithelial cells so invaded do not absorb the staining agent so well, thus resembling the invaded pus cells. The formation of vacuoles is seen. Penetration of the nucleus by the gonococci occurs when the cell is degenerating, together with the vacuolation of the nuclear substance. In such specimens numerous broken-down epi-

thelial cells are scattered through the field, also detached nuclei containing gonococci in their substance.

These cell changes are best seen during the early stages of the disease, where the destructive process is rapid. In the later stages the appearances narrated are difficult to demonstrate. Through the action of the gonococcus we have a gradual process of cell destruction in part antagonistic to the theory of phagocytosis propounded by Metschnikoff.*

Parts affected by the Gonorrhœal Poison.

In the male the chief seat of infection is the urethral mucosa. The course and complication of gonorrhœal urethritis are well described in surgical text-books. The conjunctiva, joints, endocardium (?), and rectum, are affected in both sexes.

In the female genitalia, the chief seats are the cervix, urethra, Bartholinian glands, and vagina; the disease spreading later to the body of the uterus, Fallopian tubes, and ovaries. The cervix, owing to the number of glands contained in the mucous lining, is the chief seat of manufacture of the discharge met with in leucorrhœa and also of that met with in gonorrhœa.

As a rule the disease does not spread higher than the os internum if the attack be slight.

Next in importance to the cervix comes the urethra and Bartholinian glands. In many cases the entrance to the ducts of these glands is surrounded by an areola of inflammation, and on exerting pressure pus is exuded from the ducts. Examination of the pus shows the presence of

* For further information the reader is referred to the 'Lectures on the Comparative Pathology of Inflammation,' by Elias Metschnikoff, translated by F. E. and E. H. Starling, London, 1893, and to Erlich's book, 'Farbenanalytische Untersuchungen zur Histologie und Klinik des Blutes,' Berlin, 1891.

The neutrophile polynuclear leucocytes are said to engloble gonococci. They are not taken up by the mononuclear leucocytes (Virchow's 'Archiv,' vol. cvii, p. 227, 1887).

numerous gonococci. In some cases abscess formation occurs in the glands and gland ducts.

Vaginitis.—Bumm, who stated that the vaginal epithelium resisted the action of the gonococcus, denied the existence of gonorrhœal vaginitis. This opinion was upheld by other writers in Germany, until recent investigations began to throw more light on the subject. Such a conclusion must have been arrived at on purely theoretical grounds, for practical experience teaches that we do meet with cases of gonorrhœal vaginitis. Where a virgin has been infected by a man suffering from gonorrhœal urethritis, a vulvo-vaginitis of a gonorrhœal character results, and in such a case infection may not extend to the cervix. The same is true of vulvo-vaginitis in children. Doubtless the more delicate epithelium lining the vagina in these cases offers less resistance to the action of the poison. In cases where connection has occurred frequently, the lining of the vagina is probably more resisting. As the gonococci penetrate epithelial cells, and also the interstices between the cells, the occurrence of gonorrhœal vaginitis is readily explained in such cases.

Where acute gonorrhœa of the cervix uteri goes on to profuse suppuration, pouring a constant supply of poison into the vagina, desquamation of vaginal epithelium occurs, and less resisting layers of epithelium being on the surface, a gonorrhœal inflammation with all the characters of a recent infection results.

Gonococci flourish where the epithelial lining is delicate and the secretion profuse ; hence the persistence of cervical gonorrhœa in women.

During pregnancy, owing to increased secretion of mucous and epithelial desquamation, the vagina is more liable to be affected. It should be added that a previous non-gonorrhœal vaginitis predisposes to the vagina being attacked by the gonococcus. Cases of vulvo-vaginitis, gonorrhœal in character, can be cured before the malady spreads to the cervix uteri.

Vulvitis.—A great controversy has existed for some

time, and still exists, concerning the nature of vaginal and vulvar discharges in infants and children. Some have even gone the length of stating that all these cases are gonorrhœal in character. Such random statements are productive of great evil, and do much to bring bacteriological work into discredit.

Cases of vulvo-vaginitis may be divided for the present purpose into two main divisions: (1) gonorrhœal; (2) non-gonorrhœal. I do not classify the latter group as simple cases, for many are of an infective character, as is shown by the epidemic vulvo-vaginitis in schools. The special organism contained in these cases will be described in Part II.

Epstein* describes three cases of gonorrhœal vulvo-vaginitis in the newly-born; two of these infants were also affected with gonorrhœal ophthalmia. Infection of the vulva of the child during labour is possible, especially where it is not well washed after birth. Such an occurrence must be exceptional. I have never met with a case out of 700 labours.

In vulvo-vaginitis of children from two to three years of age, Epstein found that the mothers also suffered from gonorrhœa. Dirty habits on the part of the mother explain many sources of infection in the child.

Rectal gonorrhœa.—In a few cases a gonorrhœal affection of the rectum has been described.

Frisch † relates a case in which he was able to obtain a post-mortem examination. A young woman suffering from gonorrhœal urethritis was found to have a purulent discharge from the rectum. Examination of the pus showed numerous gonococci. Six months later she died

* "Ueber Vulvovaginitis Gonorrhoica bei Kleinen Mädchen," Beihaft ii, 'Arch. f. Dermat. u. Syph.,' 1891, p. 3). Consult also (1) Casel, "Ueber Gonorrhoë bei Kleinen Mädchen," 'Berlin. klin. Woch.,' 1893, No. 29, pp. 700—704; (2) H. Koplik, "Urogenital Blennorrhœa in Children," 'Journ. Cutan. and Genito-urin. Diseases,' 1893, Nos. 6 and 7, pp. 219—230, 263—275).

† "Ueber Gonorrhea Rectalis," 'Verhand. d. phys.-med. Gesellsch. zu Würzburg,' N.F., Bd. xxv, No. 6.

of phthisis. Post-mortem, an ulcer was found situated on the posterior rectal wall 3 cm. above the anal orifice. Sections of this ulcer showed gonococci, contained in round cells lying in the substantia propria of the mucosa and the connective tissue between the glands.

Oral gonorrhœa.—In the newly-born gonorrhœa affecting the mouth has been described by Rosinski.* He has narrated two cases in this situation. In one there were circumscribed patches of superficial infiltration, the discharge containing gonococci.

Ophthalmia.—The changes produced in the eyes of infants as a result of the action of the gonococcus are well described in Bumm's book, which the reader may consult with advantage.

He has shown how the gonococci penetrate between the epithelial cells of the conjunctiva into the deeper layers. This and the subsequent changes can be readily demonstrated in this situation.

Cases of ophthalmia neonatorum may also be divided into two main divisions: (1) gonorrhœal; (2) non-gonorrhœal. In the present state of our knowledge, as with vulvitis, no exact classification can be made.

The ordinary leucorrhœal discharges in the female during labour give rise to a conjunctivitis with purulent discharge. This is rarely severe, and rapidly yields to suitable treatment.

In maternity hospitals it is a routine practice to wash the eyes of new-born infants with a suitable antiseptic solution. It is most important that this should be adopted in private practice.

The onward progress of cases of gonorrhœal ophthalmia is very rapid, requiring active treatment at once.

Examination of the pus in these cases shows abundant gonococci.

All cases of purulent discharge from the eyes of infants should be examined to determine the presence or absence of

* "Ueber Gonorrhöische Erkrankung der Mundhöhle Neugeborener," 'Deutsche med. Woch.,' 1891.

gonococci. Until this is recognised as a necessity many cases will be permitted to drift on from bad to worse. It frequently happens that a discharge from the eyes is overlooked, or if detected either left alone or treated ineffectually, until implication of the cornea forces the gravity of the condition on the attention of the practitioner.

When it is fully recognised what serious consequences may accrue from neglecting such a condition, the necessity for early recognition is at once evident. I have examined a large number of cases (ophthalmia) supposed to be gonorrhœal, and have invariably found gonococci present.

In cases of doubtful diagnosis a microscopic examination is essential.

Gonorrhœal arthritis.—The presence of gonococci in the pus from joints affected by so-called "gonorrhœal rheumatism" is still *sub judice.*

This subject can be made clearer if we take our analogy from the cultivation of the organism. We find that it is very difficult to obtain the gonococci pure and free from other organisms, and that these organisms overgrow the gonococci, just as weeds overgrow young and tender plants, frequently causing their death. If this process goes on outside the body we have every reason for believing that a similar process goes on within the body, so that in pus taken from a suppurating joint no gonococci may be demonstrated.

Deutschmann * describes the case of a child, three weeks old, who, while suffering from blennorrhœa neonatorum developed swelling and redness of the left knee-joint. In the pus from the eyes and from the knee-joint gonococci were found.

Neisser † succeeded in cultivating gonococci contained in the pus from the knee-joint.

* "Arthritis blennorrhoica," 'Arch. f. Ophthal.,' Bd. xxxvi, 1890, S. 109).

† "Ueber die Züchtung der Gonokokken bei einem Falle von Arthritis gonorrhoica," 'Deutsche med. Woch.,' 1894, No. 15.

On this subject, however, more work must be done before formulating definite conclusions.

Channels of infection.—The presence of gonococci in the joints and in the endocardium as suggested by Leyden (op. cit.) leads us to discuss the channels through which they have travelled from the original source of infection.

Two possible channels are open, viz. the blood-vessels and the lymph-vessels.

Trapesnikoff * examined the blood in thirty-two cases where complications existed, the results being negative.

It is probable that the infection spreads through the lymphatics, because sections of tissues containing gonococci show a local thrombosis, produced by these organisms filling the lumen of the lymph-vessels.†

The Theory of Mixed Infection.

Those opposed to the view that the organism called the gonococcus is the cause of gonorrhœa argue that this organism is rarely demonstrated in the pus formations which result at some distance from the local lesion, *e. g.* suppurating buboes, peri-urethral and prostatic abscesses, &c. Here, again, we must refer to the overgrowth of the gonococcus by other pus organisms. Although on examination of the pus from a suppurating bubo no gonococci are found, we cannot conclude that gonococci have never been present in that pus. In the same way, if a gonorrhœal discharge from the urethra be examined during the later stages of the disease, pus organisms only may be detected; here, however, as is well known, pus organisms entirely replace the gonococci.

Staphylococcus pyogenes aureus is not infrequently associated with the gonococcus in late gonorrhœal discharges. Abscesses in the prostate, inguinal glands, or around the urethra are probably due in part to its

* "Die Untersuchung des Blutes auf Gonokokken," 'Medicina,' 1892, No. 2 (Russian).

† Further observations are required to settle this question. I am inclined to think infection spreads through both channels.

presence, as it has been frequently demonstrated in the pus from such cases. In joint affections it is frequently found.

We have, therefore, in order in explain the complications attendant on an attack of gonorrhœa to resort to the theory of mixed infection.

The effect of the action of the gonococcus on the particular soil attacked is to convert that soil into a suitable medium for the growth and development of pus organisms. If this invasion of pus organisms be great we may have various complications developed quite apart from the action of the gonococcus, in the same way that lymphangeal inflammation with suppurating axillary glands may result from a poisoned wound of the finger.

Latent gonorrhœa.—Much has been written in the past on the subject of "latent gonorrhœa." In a case of so-called "latent gonorrhœa" it is supposed that indulgence in alcohol or marital intercourse brings to life certain gonococci which are lying in a dormant state. Such a hypothesis is contrary to all present pathological dicta. If an attack of gonorrhœa in the male remains uncured, the affection is increased by indulgence in alcohol, and the congestion attendant on sexual intercourse. This, however, is a case of true gonorrhœa, not one of so-called "latent gonorrhœa." After a severe attack, even when the disease has been cured, a discharge, purulent or mucoid, may result after alcoholic or sexual indulgence. But in such cases no gonococci can be demonstrated in the pus.

Where a patient has had several attacks of gonorrhœa, the urethra becomes unduly sensitive and structurally altered, often leading to the formation of a stricture.

In such cases any increased congestion or irritation may give rise to a purulent discharge, much in the same way as exposure to any slight irritation is apt to cause a recurrence of conjunctivitis where there have been one or two previous attacks. The conjunctiva, like the urethra, in these cases becomes a weak point.

In the female many tubal and ovarian disorders are attributed to gonorrhœa on very insufficient grounds. Salpingitis occurring one or perhaps two years after an attack of gonorrhœa is generally ascribed to the gonorrhœa; it will be shown, however, that such conclusions are not always warranted by the facts. Medical literature abounds with such statements,—so much so, indeed, that gonorrhœa is laid down as one of the chief factors, if not the chief, in the causation of the diseases peculiar to the female sex.

Noeggerath,* whose statements are very much exaggerated, has been the greatest advocate of this pathology. His work has borne fruit in that the profession, and through it the public, have been educated to the importance of having an attack of gonorrhœa completely cured. The statements that a man is never completely cured of an attack of gonorrhœa, and that that man is certain to infect his wife, are contrary to all clinical and pathological observations.

An attack of gonorrhœa in the female is more apt to be of long standing for two reasons:

1. Because slight attacks are disregarded.

2. Because the periodic congestion resulting from the menstrual functions tends to keep up or aggravate a pre-existing malady.†

Sexual intercourse also tends to augment the condition in two distinct ways:

1. By promoting increased congestion.

2. As the uterus becomes more erect during the sexual orgasm, accompanied by the expulsion of cervical mucus, a suction action is supposed to take place so that spermatozoa may be received into the uterine cavity. Should there be a pre-existing gonorrhœal catarrh of the cervix

* "Die latente Gonorrhoe in Weiblichen Geschlecht.," Bonn, 1872.

† Bröse ("Zur Aetiologie, Diagnose und Therapie der Weiblichen Gonorrhoe," 'Deutsche med. Woch.,' 1893, Nos. 16—18) thinks that shortly before, after, and during menstruation gonococci come out of the mucosa to the surface.

uteri, pus laden with gonococci would tend to be sucked up into the cavity of the uterus, and so cause an upward extension of the disease to the body of the uterus and the Fallopian tubes.*

I am inclined to regard the incautious use of the uterine sound as a potent cause of the upward spread of the gonorrhœal poison. Suppose a case of endocervicitis (gonorrhœal) comes for treatment, an accurate diagnosis is probably not made, and a sound is passed to measure the uterine cavity or for some other reason. Through the passing of this instrument gonorrhœal pus is carried up to the fundus uteri, perhaps a slight traumatism produced, and as a sequence tubal inflammation occurs.

It is imperative, therefore, that the great danger attendant upon the passage of the sound or any other instrument introduced into the cavity of the uterus in such cases, be fully recognised.

I do not believe that cases of gonorrhœa recognised and intelligently treated have as a sequel implication of the Fallopian tubes. Where it was difficult to determine the exact causation of disease involving the Fallopian tubes, gonorrhœa has been used by many as a useful cloak for ignorance.

If the discharge from the cervix uteri in cases of endocervicitis (not gonorrhœal) be examined microscopically, it will be found teeming with microbes.

Here, again, if the uterine sound be passed, these organisms are carried into the body of the uterus, where, normally, few if any are present.

Should the vitality of the uterine tissue be sufficient, this invasion is resisted; if not, endometritis and perhaps salpingitis develop as a consequence.

Healthy tissues, being the best of all antiseptics, can overcome the action of many micro-organisms until their (the tissues') strength fails.

I am convinced that the introduction of sounds,

* I do not overlook the importance of lymphatic absorption from the diseased area.

instruments for uterine medication, stem pessaries, and the like, are most important factors in the causation of salpingitis, and of many cases diagnosed as gonorrhœal.

Before a diagnosis of gonorrhœal salpingitis is made a direct causal relationship should be shown between an attack of gonorrhœa and the attack of salpingitis. Such evidence is absent in many cases recorded in the literature on this subject.

The Diagnostic Importance of the Presence of the Gonococcus.

It is appropriate here to discuss the question, Is the gonococcus the cause of the disease known as gonorrhœa?

Before concluding that a particular disease is caused by a special organism, we must furnish sufficient proof to satisfy the conditions laid down in Koch's postulates.

Firstly, we must have a well-defined type of disease, accompanied in all cases by symptoms so characteristic as to constitute a specific malady. In all such cases, at one stage or another of their course, it must be possible to demonstrate a micro-organism of constant form, disposed in a constant relation to the blood or tissues of its host. This organism must only be found in the tissues of animals which are suffering or have suffered from the distinctive symptoms already described.

Secondly, by carefully effecting the isolation of these organisms from the tissues and inoculating them on nutrient media specially adapted for their support, it must be possible to cultivate them artificially apart from the tissues of their host. Cultivations by constant reinoculation to be produced until a pure cultivation is obtained.

Thirdly, it must be possible, by the inoculation of the organism thus isolated into the system of an animal liable to the disease, to reproduce it, and the disease so reproduced must have all the symptoms of the original complaint, or at least a sufficient number to give it the specific character.

Fourthly, in the tissues of the animal thus attacked there must be a recognition of the same foreign elements in the same relation to the tissues of their host as was observed in the original case.

Before considering whether the relationship of the gonococcus to gonorrhœa conforms to these conditions, it may be affirmed that something carried over with the organisms, and not the organisms themselves, is the *fons et origo* of the malady. We can, however, definitely conclude that the appearances previously detailed may be demonstrated in the pus from cases of gonorrhœa. After cultivation, the same bodies are seen isolated from the cells. These bodies reappear in the discharge from inoculations, and these inoculations produce a disease resembling the original malady. We cannot refute the statement that something is carried over with these bodies, which further research will doubtless reveal.

Let us examine in detail how the particular microbe named the gonococcus stands the test of the conditions mentioned.

Firstly, we have a well-defined specific malady, to which the term gonorrhœa is applied.

In all the acute cases examined, I have never failed to demonstrate a particular organism at one or other stage, of constant form and disposed in a constant relation to the pus cells, &c. This particular organism is not found except in the tissues of animals which are suffering or have suffered from this well-defined specific malady.

Secondly, this organism can be cultivated apart from the tissues of its host, and by re-inoculation on suitable media a pure cultivation is obtained. The difficulty of cultivating was used as an important argument against the identity of this organism. Here, however, Koch has long ago stated that if other media fail, an organism will grow on the blood serum of its host, hence the growth of the gonococcus on human blood serum. The cultivation test is the most important from a diagnostic point of view, and should always be employed in doubtful cases. It is

difficult to accept statements as to the presence, position, &c., of gonococci where no cultivations have been made. On this ground a large number of papers on the subject must be disregarded.

Thirdly, this organism inoculated in man and certain animals has the power of reproducing a disease similar to the original. It must be admitted that the disease produced by inoculation from cultivations is not so severe as that otherwise produced. On this account we may safely assume that in an attack of gonorrhœa we have to deal with a gonorrhœal inflammation from the gonococcus, and a septic inflammation caused by other pus organisms.

Fourthly, in the discharges, &c., produced the same organism is recognised, bearing the same relationship to the cells of the host as in the original case.

Recognition of the Gonococcus by the aid of the Microscope.

It will be necessary under this heading to recapitulate some points previously described.

1. *Form and size.*—The diplococcus form is not characteristic. The size cannot be relied upon as an aid to diagnosis.

2. *Action of staining reagents.*—There is no stain at present used which is characteristic. It was formerly supposed that the action of Gram's stain on this organism was distinctive. As has been shown, other diplococci react in a like manner. The "yellow-white diplococcus" found by Bumm in two cases of puerperal cystitis, remains deeply stained after Gram's method, thus differing from the gonococcus and some other diplococci which remain unstained.

3. The arrangement of the gonococci around the nuclei of the pus cells has been always regarded as the most reliable aid to microscopic diagnosis. My own observations on the pus from cases of vulvitis in children show that the special organisms seen in this disease are

similarly disposed in relation to the nuclei of the pus cells. It will be apparent that although no one of these three signs is characteristic, yet when they occur together there is strong presumptive evidence that we are dealing with the gonococcus. The cultivation test remains the most convincing.

4. Gonococci are present in the pus of every untreated case at some period.

5. Secretion free from gonococci does not cause a gonorrhœal inflammation.

6. Secretion containing gonococci even in small quantities affects sensitive mucosæ with absolute certainty.

The naked-eye appearance of the discharge is not characteristic, although brought forward by some writers.* It is evident that where the presence of gonococci is demonstrated in a purulent discharge, the disease is gonorrhœal in character. If, however, no gonococci be found, we cannot say that the malady has not been gonorrhœal.

In arriving at a conclusion we are assisted by clinical evidence furnishing a history of a definite acute attack, resembling the signs and symptoms of acute gonorrhœa.

In all doubtful cases a careful microscopic examination should be made to assist in forming a correct diagnosis. This is specially needful where the female genitalia are affected, and where so many sources of error beset the path of the investigator. In many cases the reasons given are very insufficient, and do not warrant us concluding that the disease is gonorrhœa. Before concluding that gonococci are absent from a discharge, certain sources of error must be avoided:

1. Small ill-developed examples may be observed (Involutionsformen).

2. Owing to the scarcity of gonococci in the pus, they

* *E.g.* Schwarz ("Die Gonorrhoische Infection beim Weibe," 'Volkmann's Samm. klin. Vortr.,' No. 279, 1886) states that pus from the cervix uteri in gonorrhœal cases is thick, creamy, greenish yellow.

may be overlooked, especially where only one or two preparations are made.

3. Where numerous other organisms are present, *e. g.* in pus from the cervix uteri, the gonococci may be hidden.

4. The gonococci may be embedded in the mucosa, appearing only at intervals in the secretion.

All cases should be examined frequently, and for some time, before stating definitely that no gonococci are present.

The determination of the exact causation of gonorrhœa is of immense practical importance. Investigations have all tended to strengthen the discovery of Neisser, still we must have a large mass of evidence upon which to base our conclusions. The value of confirmatory observations cannot be over-rated. If it be conclusively proved that the gonococcus is the cause of the disease, then in every case where this organism is found we can give a definite opinion that the malady is gonorrhœal. The great importance of such a discovery medico-legally is at once apparent, *e. g.* in cases of supposed rape if gonococci be found contained in the discharge from the vulva or vagina of the female, at the same time gonococci being discovered in the urethral pus from the male suspect. Again, where prostitutes are systematically examined, the pus from the cervix and urethra should be submitted to a careful examination under the microscope, before they are declared free from infective disease.

Methods of cultivating the Gonococcus.

Bokai ("Ueber das Contagium der acuten Blenorrhoe," 'Allg. med. Central-Zeitung,' 1880, No. 74), attempted the cultivation of the gonococcus on a fluid medium; the result was a failure owing to the rapid overgrowth of other organisms. Neisser used meat extract, peptone, gelatine (Fleisch extract peptone-gelatine) of almost neutral reaction. This did not succeed for the reason stated above.

Leistikow * and Loeffler obtained negative results from cultivations at the ordinary room temperature on bouillon gelatine (Rind, Huhn, Mensch), on "Fleischwasserpepton, Blutwasser, Glaskörper, Cohnscher Flussigkeit." After repeated trials in an oven they concluded that blood-serum gelatine was the best medium. Their results were confirmed by microscopic examination, attention being paid to the grouping of the organisms in the cells.

Krause † re-investigated this subject, using pus from cases of gonorrhœal ophthalmia in the newly born. After failing with meat extract peptone-gelatine, he used blood serum from the sheep placed in small glass vessels (Glasnäpfen) with covers, then coagulated. After having inoculated the surface of the serum with gonorrhœal pus, the glasses were placed in a moist chamber at a temperature from 32° to 38° C. After twenty-four hours a quantity of the growth was re-inoculated; on this being repeated two or three times a pure culture was obtained. The growth was very slow, having a greyish-yellow appearance spreading out from the point of inoculation. The cultivation did not grow at the ordinary room temperature. An inoculation from a pure culture was soon overgrown. The cultivated organisms showed the characteristic form, with variation in size.

Other authors have described their results showing that the growth of the organism—a diplococcus—was rapid (Sattler, Chameron, Arning, Sternberg, Oppenheimer). Fehleisen stated that he obtained a cultivation carried through four generations on meat extract peptone-gelatine, kept at the temperature of the body, the pus having been obtained from the urethra.

It will be seen that no additional confirmation was procured to establish the identity of the gonococcus.

* "Ueber Bacterien bei den Venerischen Krankheiten," 'Charité Annalen,' Jahrgang vii, p. 750, and 'Berl. klin. Woch.,' 1882, p. 500.

† "Die Mikrokokken der Blenorrhoea Neonatorum," 'Centralbl. f. prakt. Augen.,' 1882, p. 134.

The microscope in all the experiments previously narrated showed the presence of diplococci, shaped like two rolls (Semmelförmige), forming clusters.

Bumm and Bockhart,* following the example of Fehleisen, used meat extract and meat infusion peptone-gelatine of varying strength and reaction, chiefly of slight alkalinity from the addition of "Dinatriumphosphat." For inoculation, pus rich in gonococci was taken from the urethra of patients having had no treatment, and from all stages of the disease. The pus was placed on the surface of the gelatine in a thin layer, or in thick streaks, or introduced deeply. The tubes were kept at a temperature between 15° and 20° R. No growth was obtained. Several tubes showed a growth of the "milk-white" diplococcus. The results were not better when the tubes were kept in an incubator at the temperature of the body.

Bumm, experimenting with coagulated blood-serum kept at a temperature between 37° and 39° C., did not meet with much success at first. He used ox serum and serum from the sheep, mixed with a varying amount of human blood-serum. The last was carefully expressed from the umbilical cord and mixed so that the upper layer consisted of human blood-serum. Using pus from the urethra and the conjunctiva, he again failed. In several tubes, after two to three days, at the points of inoculation a whitish speck appeared, which, increasing in size, formed a thin layer 3—4 mm., greyish-white by transmitted light with irregular edges. This diplococcus was characterised by very slow growth at the ordinary room temperature and on gelatine. Neither blood-serum nor gelatine were liquefied.

The appearance of this organism was absolutely identical with Neisser's diplococcus. Several pure cultivations were implanted on mucous membranes, the organism proving innocuous. Cultivations of a "milk-white" and

* "Beitrag zur Aetiologie und Pathologie des Harnröhrentrippers," 'Vierteljahrsch. f. Dermat. u. Syph.,' 1883, p. 3.

a "citron-yellow" diplococcus were obtained which were supposed to come from the orifice of the urethra and the edges of the eyelids.

The best results were obtained by keeping the incubator at from 30° to 34° C., the test-tubes being placed in a large glass vessel half filled with distilled water, and covered by a well-fitting glass plate. The glass vessel being filled with moist air, the surface of the blood-serum was prevented from becoming dry. The cultures thus obtained were very thin, often scarcely visible, greyish-yellow by reflected light, the surface smooth and moist, the edges diffusing into the surrounding medium, which was not liquefied. Re-inoculations of a pure culture on meat extract peptone-gelatine, blood-serum, gelatine, and agar gave no result.

Wertheim ('Arch. f. Gynäk.,' Bd. xlii, 1892), following Bumm's method, used human blood-serum. After the birth of the child the umbilical cord was cut across and compressed, the maternal end being placed in a sterilised glass vessel. In this way about 60 to 80 c.c. was obtained from each placenta. After standing twenty-four hours in a quiet place, the separation into blood-clot and serum takes place. The latter is carefully removed with a sterilised pipette and run into sterilised "eprouvetten." The serum so obtained is clear and of a bright yellow colour. Further sterilisation is unnecessary where previous precautions have been thoroughly carried out. To coagulate the serum the tubes are kept in a "Brutkasten" at a temperature of 66° to 68° C. After four hours the serum is of gelatinous consistence without losing its transparency. Wertheim succeeded in producing cultivations resembling both macroscopically and microscopically those described by Bumm and others.* He also experimented with plate cultivations which had been previously tried by Bockhart.†

* On blood-serum cultivation consult Hueppe, "Ueber Blutserumculturen," 'Centralbl. f. Bakt. u. Parasit.,' 1887.

† "Zur Kenntniss der Gonokokken," 'Monatsh. f. prakt. Dermat.,' 1886.

Gonorrhœal pus from the male urethra was carefully added to fluid blood serum in tubes; from these two dilutions were made. The tubes were then placed in a water-bath at 40° C., the contents mixed with an equal amount of agar cooled in the same water-bath at 40° C. (2 per cent. agar, 1 per cent. peptone, 5 per cent. sodium chloride). After mixing, the contents were poured out on plates which were transferred to a moist chamber and kept in a "Brutofen" at 36° C. By this method the formation of colonies may be studied, and where the pus contains other organisms, *e.g.* vaginal discharges, it is possible to isolate the gonococcus. Cultivations obtained by this method inoculated on to sterilised blood serum in tubes showed the presence of the characteristic organism. The results were confirmed by experiments on the human subject.

Schrötter and Winkler* cultivated the gonococcus upon albumen from the egg of the peewit (Kibitz) kept in an incubator at 38° C.

Aufuso (1891) obtained a negative result with albumen from the hen's egg. This observer† cultivated the gonococcus on the fluid obtained from a case of chronic synovitis of the knee-joint, from which he inoculated a male adult, finding typical gonococci in the urethral discharge. Ox serum and ascitic fluid gave a negative result.

Gebhardt ("Der Gonokokkus Neisser auf der Platte und in Reincultur," 'Berl. klin. Woch.,' 1892, No. 11) may also be consulted. He used placental blood allowed to settle in a refrigerator. The serum (1—3 c.c.) removed by a pipette, and introduced into a sterilised glass, then sterilised for seven days at 58° C. for one and a half hours each day. The sterility was frequently tested by keeping

He recommended a mixture of nutrient agar 2 parts, liquefied at 53° C., with blood serum 2—3 parts at 20° C. By quickly mixing with these a little pus containing gonococci he was able to obtain colonies upon plate cultivations made by pouring the liquid medium on sterile glass plates in the usual manner.

* 'Ueber Reinkulturen der Gonokokken,' Wien, 1890.

† Aufuso ("Il gonococco di Neisser," 'La Riforma Med.,' 1891, No. 28, p. 328).

at 37° C. For plate cultures equal parts of serum and peptone agar were used.

Ghon and Schlagenhaufer ("Beitrag zur Züchtung des Gonococcus Neisser," 'Wien. klin. Woch.,' 1893, No. 34, p. 619), used peptone agar covered over with sterile human blood serum (Pfeiffer's blood agar). The use of streaks gave better results than plate cultures. Inoculation in a male gave a positive result. The authors obtained better results on ox-serum agar when they added "saures phosphor saures Natron." They found as a useful substitute a mixture of two parts 2 per cent. agar, and one part acid urine, taken sterile or after sterilisation. As further cultivation on this medium was difficult, they resorted to the use of the former.

A man inoculated with a two-days-old first generation culture on urine agar developed after forty-eight hours' incubation purulent urethritis with typical intra- and extra-cellular gonococci.

E. Finger, A. Ghon, and F. Schlagenhaufer ("Beiträge zur Biologie des Gonokokkus und zur pathologischen Anatomie des gonorrhoischen Processes," 'Arch. f. Dermat. u. Syph.,' Bd. xviii, 1894, Nos. 1 and 2) employed human urine either at once after careful collection or heated for half an hour to 70° to 80° C. The medium was prepared in the same way as the serum agar used by Wertheim. Albumin and globulin are the nutrients for the gonococcus in serum, and in the urine sulphates of soda and potash.

Kral ("Eine Einfache Methode zur Isolierung des Gonococcus in Plattenverfahren," 'Archiv f. Dermat. u. Syph.,' Bd. xxviii, 1894, Heft 1) describes three different cultivating media with which he has obtained successful results. The composition of each is fully detailed in his paper.*

* See McCann, "The Fluid contained in Ovarian Cysts as a Medium for the Cultivation of the Gonococcus and other Micro-organisms," 'Lancet,' May 30th, 1896.

Inoculation Experiments.

Gonorrhœal pus has been inoculated on the conjunctiva and into the urethra of dogs and rabbits (Neisser). Rabbits, dogs, mice, guinea-pigs, horse, asses (Loeffler and Leistikow), in the same situations, generally after wounding the mucosa with a lancet. The results were negative.

Krause experimented on the conjunctiva and urethra of full-grown rabbits, and on the conjunctiva of young cats, pigeons, and mice. No specific inflammation followed.

It is doubtful if some of these observers were dealing with the true organism. The same may be said regarding the results obtained by Bokai, Chameron, Sternberg, and Bockhart, in the human subject.

Bumm produced a characteristic gonorrhœal inflammation after inoculating the urethra of a woman whose genitalia and urethra were proved by repeated examination to be free from gonococci. He also succeeded with the conjunctiva of the newly born.

Wertheim* inoculated the human subject from pure cultures; he was, moreover, successful with animals, producing gonorrhœal peritonitis in white mice, guinea-pigs, rabbits, and rats.

Steinschneider† injected a mixture of bouillon, human blood serum, and gonococci (pure cultivation) into the subcutaneous tissue of the back of a man. No result followed. He also injected watery agar mixed with serum, to which gonococci from a pure culture were added by means of a Pravaz syringe, into the abdominal cavity of three guinea-pigs; result *nil*, preparations and cultures being made. He failed to confirm Wertheim's experiments on the peritoneum of white mice.‡

* Op. cit.

† 'Berlin. klin. Woch.,' Nos. 29 and 30, July, 1893.

‡ Wertheim (op. cit.) inoculated the human urethra with pure cultivations of gonococci taken from pus in cases of pyosalpinx.

Risso * inoculated a pure cultivation of the gonococcus on blood serum into the anterior chamber of the eye of a rabbit. Steinschneider, repeating these experiments, concluded that gonococci, on or with serum agar, placed in the anterior chamber of the eye, occasion a very severe spreading inflammation with exudation which cannot be produced by the gonococci or the serum agar alone, and that the organisms cannot develop further in this situation.

References to the literature will appear in Part II.

Dr. PETER HORROCKS asked if it were possible to obtain evidence of the presence of the gonococci in a tolerably easy manner. Also what did the author mean by saying that a previous attack of vaginitis predisposed to gonorrhœa? Did he mean gonorrhœal vaginitis or some other form? He did not think that attacks of gonorrhœa in either the male or the female predisposed to future attacks. On the contrary, he believed that repeated attacks rendered the mucous membranes affected less prone to attack; they obtained a sort of immunity. He asked what evidence there was to support the statements that in all forms of gonorrhœa the gonococcus was found in some stage of the disease, and that a discharge which contained no gonococci might be the result of a gonorrhœa; and would such gonococci-free discharge set up gonorrhœa in a healthy mucous membrane?

Dr. DAKIN was interested to hear the author's opinion that a large number of the cases of pelvic inflammation ascribed to gonorrhœa had probably not that origin. He would be glad to have Dr. McCann's views as to the length of time which should elapse before a previously occurring gonorrhœa might be acquitted on the charge of causing a perimetritis or a pyosalpinx. It was a somewhat complicated but an important question.

Dr. CULLINGWORTH asked the author what evidence he considered sufficient to warrant the conclusion that a salpingitis was of gonorrhœal origin.

* 'La Riforma med.,' 1892, No. 118.

A CASE OF TRUE UNILATERAL HERMAPHRODITISM WITH OVOTESTIS OCCURRING IN MAN, WITH A SUMMARY AND CRITICISM OF THE RECORDED CASES OF TRUE HERMAPHRODITISM.

By G. F. Blacker, M.D., M.R.C.P., F.R.C.S.,
ASSISTANT OBSTETRIC PHYSICIAN TO UNIVERSITY COLLEGE HOSPITAL,

AND

T. W. P. Lawrence, M.B., F.R.C.S.,
CURATOR OF THE MUSEUM, UNIVERSITY COLLEGE.

(Received January 21st, 1896.)

Abstract.

Klebs' definition of true hermaphroditism as the presence of different genital glands in one individual, is the one adopted in this paper. Klebs subdivides true hermaphroditism into three classes, viz.:

1. Unilateral. Ovary or testis on one side, with ovary and testis on the opposite side.
2. Bilateral. Ovary and testis on both sides.
3. Lateral. Ovary on one side, testis on the opposite side.

The specimen described is classed under the subdivision of true unilateral hermaphroditism. It was obtained from an eight and a half months' fœtus, and consists of a mal-developed uterus unicornis with Fallopian tube and ovary upon the right side, while on the left side the genital gland has the microscopical structure of both ovary and testis, and is connected with a mal-developed Fallopian tube, and an enlarged Wolffian duct representing epididymis and vas deferens.

A summary is given of twenty-eight cases collected from the literature, and described as instances of true hermaphroditism, viz. two of the unilateral, nine of the bilateral, and seventeen of the lateral kind.

Reasons are given for accepting only Heppner's case of the nine bilateral, and Obolonsky's and Schmorl's cases of the seventeen lateral, as proved examples of true hermaphroditism.

The specimen described in the present paper appears to be the only case of true unilateral hermaphroditism in man recorded up to the present time.

From their examination of the reported cases the authors believe that the occurrence of true hermaphroditism in man is proved, if the term be taken to mean merely the presence of different genital glands in one individual, without reference to the presence or absence of their functional activity.

THE subject of hermaphroditism is of such great interest that one is surprised to find how very imperfect and often inaccurate are the reports of recorded cases of this condition.

At one time the term was used with great laxity to include all cases where the genitalia of an individual in any respect resembled those of the opposite sex. As a result of this, many persons were termed hermaphrodites without just cause; and while women with beards were frequently called males, men with well-developed mammæ were relegated to the class of females.

A subdivision is now made by most writers on the subject into true hermaphroditism and *pseudo-* or false hermaphroditism. In any attempt at classification the utmost importance is to be laid upon the presence or absence of the genital glands themselves; and to establish their presence we must insist upon the necessity of a microscopical examination. Without this it is quite impossible to say what the exact nature of any gland may be, and even with the microscope, owing to the very close similarity that exists between the two genital glands in the early stages of their development, it is frequently

difficult to say whether one is dealing with an early testis or an early ovary.

The classifications of hermaphroditism are numerous, but we propose, for the purposes of this paper, to follow that of Klebs, which is the simplest and, in many ways, the best. He defines true hermaphroditism as the presence of different genital glands in one individual; false or spurious hermaphroditism as bisexual development of the genitalia with a unisexual genital gland.

With false hermaphroditism we are not in this paper concerned, and we may therefore confine ourselves to the true variety. Following Klebs, it may be subdivided into three classes, as follows:

1. True unilateral hermaphroditism; where on one side there is an ovary or a testis, and on the other side both ovary and testis.

2. True bilateral hermaphroditism; where an ovary and testis are present upon both sides of the body.

3. True lateral hermaphroditism; where there is on one side an ovary, and on the opposite side a testis.

It is a matter of dispute whether it is necessary, in cases of true hermaphroditism, for the two kinds of glands not only to be present but to be functional. If this strict limitation of the term be insisted upon, it is most unlikely that any case of true hermaphroditism will ever be met with in man; and we may, like Ahlfeld, who altogether denies the possibility of its occurrence, sweep away the class of true hermaphrodites from Klebs' classification. In ordinary usage, however, no such strict limitations are put upon the term hermaphroditism, and we shall regard it as indicating merely the presence of different genital glands in one individual, without necessarily implying that their functions are either present or perfect.

The specimen which is the subject of this paper is classed by us in Klebs' division of true unilateral hermaphroditism; that is to say, it apparently presents upon one side a single genital gland of female type, and upon

the opposite side a genital gland of both male and female type.

It was obtained from the body of an eight and a half months stillborn fœtus. The mother was a healthy primipara eighteen years old. No history of any deformities or mal-development could be obtained either in her family or in that of her husband. No other deformities were present in the fœtus.

The external genitalia consisted of a small, imperforate, penis-like organ with a large prepuce. At the root of this organ was a small opening leading into a urogenital sinus, and admitting a fine probe. A median raphe ran backwards from the opening, with two raised folds of skin on either side of the middle line, resembling the conjoined labia majora of a young female child. There was no trace of any structures representing the labia minora.

The specimen consists of the upper part of the bladder, urethra, part of the urogenital sinus, vagina, uterus with appendages, and the small penis-like organ (Plate VIII, fig. 1).

The part of the bladder (*q*) present, which has been laid open from the front, is contracted, and its mucous membrane considerably corrugated; the two ureters (*n n*) are normal, and open into the bladder in the usual situation. The urethra, 6·5 mm. in length, is situated in the anterior wall of the vagina, and presents longitudinal folds, as in the normal urethra. There is no evidence of any prostate gland. The urogenital sinus, the length of which cannot be measured owing to the absence of the external genitalia, opens superiorly into the urethra, and inferiorly into the vagina.

The vagina (*p*) measures 8 mm. in length, and presents a number of transverse rugæ with an indication of a longitudinal fold. Attached to the upper end of the vagina, and only imperfectly marked off from it, is a body (*o*) measuring 11 mm. in length and 6·5 mm. in breadth. This body ends above in a conical extremity, and contains in its interior a canal, apparently the canal

of the cervix. This canal contains a well-marked arbor vitæ. The upper conical end of the cervix becomes continuous with a hollow tube (*k*), measuring 12·5 mm. in length and 1·5 mm. in breadth, and opening at its upper end into a small cavity (*f*), triangular in shape, measuring 3 mm. transversely and vertically.

This tube and cavity appear to represent the greatly attenuated lower segment and the body of the uterus. The right cornu of the uterus is prolonged outwards for a distance of 1·5 mm., and then divides into two parts. Of these the upper is a tortuous tube (*i*), measuring 2·5 cm. in length and 3 mm. across at its widest part. This tube terminates in a fimbriated extremity, and evidently represents the Fallopian tube of the right side. Lying below and behind the Fallopian tube is an elongated, cucumber-shaped body (*j*), 12·5 mm. by 3 mm. This body is attached at its inner end by a fold of peritoneum, evidently the ovarian ligament, passing to the lower part of the right cornu of the uterus. The ovary is attached by the whole of its anterior border to the fold of the peritoneum which surrounds the Fallopian tube and forms the broad ligament of the right side. Lying between the two layers of the broad ligament, between the outer part of the ovary and the tube, is the parovarium (*g*), and just external to this the ovarian fimbria.

Just outside the centre of the anterior surface of the right Fallopian tube there is a minute thread-like process (*h*), ending in a slightly enlarged extremity. On the anterior surface of the right broad ligament is a fold of peritoneum representing the round ligament; this becomes expanded to a breadth of a little more than 1·5 mm. at its inner end, and is continuous with the right border of the body of the uterus.

Lying between the layers of the right broad ligament are several vessels; but no other structures than those described are visible to the naked eye. Just below the ovary the peritoneum passes out, forming the infundibulo-pelvic ligament (*l*).

Owing to the fact that the cervix and lower segment of the uterus are distinctly displaced to the right side of the middle line, the left broad ligament presents a larger area than the right (Plate VIII, figs. 1 and 2). Attached to the left angle of the body of the uterus and running outwards in the upper margin of the left broad ligament is a fine thread-like strand (*e*), which, at the outer extremity of the broad ligament, passes on to and along the antero-internal surface of the structure to be described as the epididymis (*a*), and ends at a distance of 3 mm. from the end of the epididymis in a free fimbriated extremity (*b*), 3 mm. in length, placed between the epididymis and the genital gland.

The outer and upper part of the left broad ligament is continued into a triangular fold (*w*), ligamentous in character, 3 mm. in length and 1·5 mm. in breadth, to which is attached a small oval body (*d*), measuring 7·5 mm. by 4·5 mm. This body has a small tongue-like process (*c*), 1·5 mm. in length and rather less than this in breadth, attached to its anterior and outer extremity. This tongue-like process is connected with the free end of the Fallopian tube by a fine fold of peritoneum, forming a free crescentic margin between it and the fimbriated extremity of the tube.

Lying imbedded in the left wall of the cervix for a distance of 10·5 mm., and running obliquely upwards and forwards, is a fine tube (*u*), which, leaving the cervix at a distance of 3 mm. from its upper end, pursues an oblique course upwards and outwards in the left broad ligament until it reaches a point just below the commencement of the ligamentous process (*w*). At this point it forms a well-marked U-shaped curve, and then passes upwards and outwards to end in a free, somewhat enlarged extremity (*a*). For the first 2·5 cm. after leaving the cervix the tube has an even calibre; for the remaining 2 cm. it gradually increases in size, and at its extremity is remarkably convoluted. On the margin of this extremity, turned towards the genital gland, there

DESCRIPTION OF PLATE VIII.

Illustrating Dr. Blacker's and Mr. Lawrence's case of True Unilateral Hermaphroditism.

FIG. 1.—From behind, very slightly larger than natural.

a. Epididymis.
b. Fimbriated extremity of rudimentary Fallopian tube.
c. Ovarian portion of left genital gland.
d. Testicular portion of left genital gland.
e. Rudimentary Fallopian tube.
f. Uterus.
g. Parovarium.
h. ? Hydatid at extremity of Wolffian duct.
i. Fallopian tube.
j. Right ovary.
k. Lower segment of uterus.
l. Right infundibulo-pelvic ligament.
m. Right round ligament.
n. Ureters.
o. Cervix uteri.
p. Vagina.
q. Bladder.
r. Combined gubernaculum testis and round ligament.
s. Processus vaginalis.
t. Left infundibulo-pelvic ligament.
u. Vas deferens.

FIG. 2.—Left genital gland and appendages, from before. Enlarged.

a. Epididymis.
b. Fimbriated extremity of rudimentary Fallopian tube.
c. Ovarian portion of left genital gland.
d. Testicular portion of left genital gland.
e. Rudimentary Fallopian tube.
f. Uterus.
r. Combined gubernaculum testis and round ligament.
s. Processus vaginalis.
u. Vas deferens.
v. Left round ligament.
w. Mesorchium (?).
x. Hydatids at extremity of epididymis.

Fig. 1.

Fig. 2.

are two minute fimbriæ (*x x*). Inferiorly the tube can be traced with a distinct lumen as far as the external os. Running from the epididymis to the genital gland is a fold of tissue (*y*), 3 mm. across; this fold contains, passing transversely between genital gland and epididymis, three or four very minute tubules—visible on holding it up to the light,—and is continuous externally and posteriorly with a peritoneal fold (*t*), the infundibulo-pelvic ligament of the same side.

The thickened fold of peritoneum (*s*) enveloping the U-shaped bend of the tube (*u*), which we term the epididymis, is continued downwards and outwards as a ligamentous structure (*r*), analogous to the round ligament (*m*) on the right side. This ligament (*r*) is seen to be composed of two parts, viz. that part enveloping the U-shaped bend of the epididymis, and a second portion (*v*) running upwards and inwards to the cornu of the uterus. The peritoneum forms a well-marked envelope for the upper part of the ligament, the processus vaginalis (*s*).

The specimen exhibits, then, an ill-developed uterus unicornis, with a relatively large cervix.

On the right side the genital gland has all the external appearances of a fœtal ovary, while the broad ligament, round ligament, and Fallopian tube appear to be normal.

On the left side the genital gland is connected with a rudimentary Fallopian tube, and is connected further with a second tube convoluted at its upper and outer extremity, with a well-marked lumen traceable as far as the vaginal wall, and possibly opening into the upper part of the vagina; in fact, an enlarged Wolffian duct representing the epididymis and vas deferens.

The microscopical examination of the genital glands gave the following result:

Right genital gland.—The right genital gland, which to the naked eye presents all the appearances of a normal ovary, is composed of a cellular stroma with a number of spaces filled with masses of cells. At the periphery the

stroma is thickened, and forms a species of tunica albuginea which completely surrounds the gland. At one point, in a crypt-like depression upon the surface of the gland, some of the superficial epithelium is to be seen in the form of a single layer of cubical cells.

The stroma is of a cellular character and embryonic type, and is composed of elongated spindle cells, with oval and spindle-shaped nuclei. Scattered here and there throughout it are a small number of larger cells of finely granular appearance, with irregular outline and large nuclei (Plate IX, fig. 3).

The cells of the stroma are arranged in a concentric manner round the spaces, but no definite limiting membrane can be detected. The central portion of the gland consists mainly of stroma; the peripheral, only half the width of the central part, mainly of cell masses. The cell masses in the peripheral zone, the largest of which measures $\frac{1}{5}$ mm. across, freely anastomose. From the deeper aspect of the peripheral zone the cell masses send down narrow, slightly tortuous cell columns into the central stroma. The columns average $\frac{1}{60}$ mm. in width, but have no uniform diameter. The masses of cells are for the most part separated from the wall of the spaces by a clear interval, due no doubt to shrinking, and appear to consist on close examination of two different kinds of cells, differing from one another mainly in size. The larger number are small round or polygonal cells with a clear glistening nucleus; the rest consist of large cells of similar shape with a well-stained nucleus, and in some places with a clear outline, the protoplasm having partly disappeared.

Tracing the relations of the two kinds of cells to one another from the periphery to the extremity of the cell columns towards the middle of the stroma, the following changes are found.

At the periphery the two kinds of cells are indiscriminately mixed; in the cell columns there is a tendency for the smaller cells to become flattened round

DESCRIPTION OF PLATE IX.

Illustrating Dr. Blacker's and Mr. Lawrence's case of True Unilateral Hermaphroditism.

FIG. 3.—Right genital gland (section parallel to long axis).

c. Cell-nests.
f. Graafian follicle.
s. Stroma (diagrammatic).

FIG. 4.—Left genital gland (ovarian portion, section parallel to long axis).

c. Cell-masses.
st. Stroma (diagrammatic).
v. Blood-vessel.
f. Graafian follicle (shown larger in Fig. 5).

Fig. 3.

Fig. 4.

the larger, the protoplasm of which becomes increased in amount; while at the extremity of the cell columns in one or two places in each section the formation can be observed of distinct primitive Graafian follicles containing one of the larger cells with protoplasm still more increased in amount, and with the smaller cells flattened round it. One of these follicles measures $\frac{1}{100}$ mm. by $\frac{1}{200}$ mm.

The gland is well supplied with blood-vessels, especially in the central portions.

Left genital gland.—The tongue-like process and the adjacent part of the body of the left genital gland present appearances almost precisely similar to those seen in the right genital gland, but the main portion of it has quite a different structure. The whole gland is covered externally by a thickened layer of cellular tissue representing a *tunica albuginea.* No superficial epithelium can be detected anywhere. The stroma of the tongue-like process consists of cellular tissue with oval and spindle-shaped nuclei containing a number of spaces similar to those already described on the opposite side (Plate IX, fig. 4). Scattered throughout the stroma are large cells of irregular outline, and faintly staining nuclei. These cells are two or three times the size of those composing the cell masses, and are found only in the stroma; they are much more numerous than the corresponding cells of the right genital gland. The spaces in the stroma are incompletely filled with masses of cells, composed of two kinds, the one small and oval with a glistening nucleus and finely granular protoplasm (Plate X, fig. 5); the second larger and with a more darkly staining nucleus. The relations of these two kinds of cells to one another are precisely similar to those already described in the right genital gland.

In some parts of the section, bodies like those seen in the right gland are present, composed of one large cell with a well-defined nucleus completely surrounded by a layer of smaller cells.

The stroma in the main part of the left genital gland

is of a looser texture than the rest, although essentially of the same type. It contains a number of irregularly shaped and fusiform cells with well-defined nuclei,—interstitial cells, as they may be termed,—mostly scattered throughout the whole of the stroma, but in some places collected together into small masses. Towards the periphery of the gland the stroma is almost entirely composed of these cells. At the periphery there is a narrow zone of irregular cell-masses and trabeculæ of stroma, one-twelfth the width of the central portion. The cell-masses are smaller than those of the peripheral zone of the right genital gland, and the zone itself is only three-fifths the width of that of the right side (Plate XI, fig. 7).

The spaces in the stroma towards the centre are well defined, and present a distinct limiting membrane composed of a single layer of flattened cells (Plate X, fig. 6). These spaces with the cell-masses lying in them definitely marked off as they are from the stroma, bear a very close resemblance to tubules, and give one the impression of tubes cut across transversely and longitudinally. These tubules are very tortuous, their diameters (varying from $\frac{1}{10}$ mm. in the largest to $\frac{1}{30}$ mm. in the smallest) remain very uniform, while their boundary lines run in long curves and parallel to one another. In parts of the section where the individual cells of the tubules can be clearly made out, the outermost cells are seen to be of larger size with abundant protoplasm, polygonal or cubical in shape, closely packed side by side, with a flat base turned towards the basement membrane, and containing a large, well-stained, oval nucleus. Within the outer layer are smaller cells less closely packed, with no definite arrangement, and surrounding quite isolated cells or a distinct lumen. These are the appearances of the tubules when cut transversely, and where a longitudinal section has passed through their centre. The peripheral cells of the tubules owing to mutual pressure have a characteristic form and are of large size, but the remaining cells are very similar in shape and size. The only indication of any difference

Fig. 5.

Fig. 6.

DESCRIPTION OF PLATE XI.

Illustrating Dr. Blacker's and Mr. Lawrence's case of True Unilateral Hermaphroditism.

FIG. 7.—Left genital gland (testicular portion, section parallel to long axis).

c. Cell-mass at periphery.
st. Stroma (diagrammatic).
s. Tubules (same group as shown enlarged Fig. 6).
v. Vessel.

FIG. 8.—Left genital gland (testicular portion, section transverse to long axis).

s. Seminal tubules.
r. Mediastinum and rete.
m. Mesorchium.
a. Artery.
v. Vein.
st. Stroma (diagrammatic).

Fig. 7.

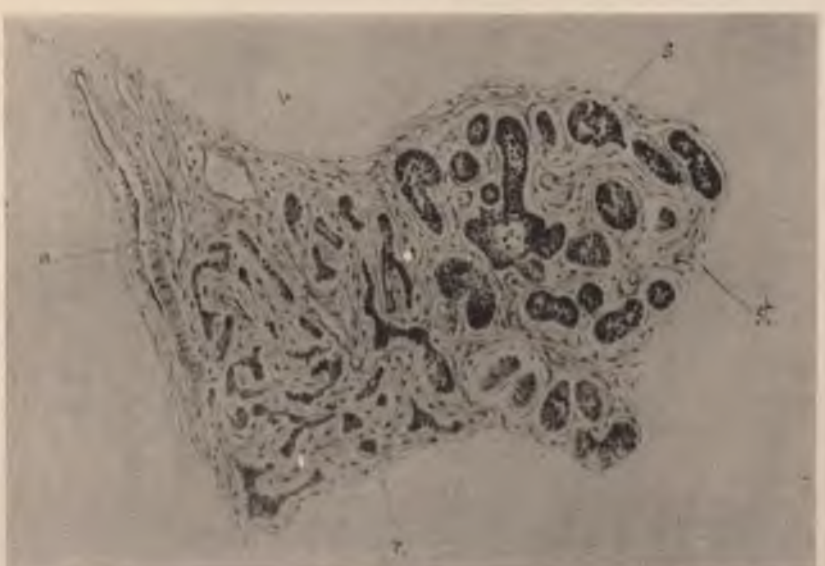

Fig. 8.

between them is that some of the cells have nuclei which stain more deeply, are more homogeneous in appearance, and less highly refractile. The tubules in the central portion of the gland can be traced to the periphery and into direct continuity with the peripheral cell-masses. On making a section at right angles to the long axis of the gland (Plate XI, fig. 8), the tubules can be observed to take a general direction towards the hilum, where they become greatly reduced in size and form an ill-defined network; from this they appear to pass out of the gland, although their actual continuation in the mesorchium has not been cut across. In this section the tubules are undoubtedly pursuing a longitudinal course from the periphery to the attached border, and the fibrous septa between them can be distinctly seen. This portion of the gland also contains a number of blood-vessels, especially towards the centre.

The area of tissue separating the two portions of the left genital gland from one another is mainly composed of a cellular stroma with small collections of cells occurring sparsely here and there. The stroma is of the same character as that in the rest of the gland, and well supplied with blood-vessels.

Although in the centre of the area the cell-masses are very infrequent, yet at the surface they are more numerous, and are continued from the tongue-like process on to the main portion of the gland.

The conclusion that the right genital gland is undoubtedly an ovary is, we venture to think, established by the naked-eye and microscopical examination. It has the anatomical relations of an ovary to the broad ligament, the Fallopian tube, and the uterus. It is attached to the latter by a definite ligament, and it is of the size and shape of a fœtal ovary.

Under the microscope the stroma corresponds to that of a fœtal ovary, and the masses of cells clearly represent cell-nests in which all stages of transition can be traced from masses of undifferentiated cells to well-developed

Graafian follicles. It must, however, be admitted that the Graafian follicles and ova are not nearly so numerous or so well developed as is usually the case in a full-term fœtal ovary, and that the amount of stroma is excessive; but this is due no doubt to the fact that the organ has been arrested in its development. It has attained the shape and size normal in an eight and a half months fœtus through development of its stroma, but as regards its epithelium and cell-masses it has the characters of a much younger organ.

The nature of the left genital gland is a much more difficult matter to determine, and we must consider the two portions separately.

It has already been shown in the description of the specimen, that the tongue-like process of the left genital gland is connected to the infundibulum of the rudimentary left Fallopian tube by a crescentic fold of peritoneum termed the ovarian fimbria. That this fold is rightly termed an ovarian fimbria is demonstrated by the microscopical appearances of the tongue-like process, and the adjoining part of the left gland.

The appearance of the stroma and the spaces contained within this portion is precisely similar to that of the right genital gland. The masses of cells, too, present all varieties, from simple nests of cells to well-formed Graafian follicles. The only difference lies in the fact that there are a larger number of what we have termed interstitial cells in the stroma, and a complete absence of any superficial epithelium. One must, therefore, come to the conclusion from its anatomical relation to the Fallopian tube, and from its microscopical structure, that this portion of the left genital gland, viz. the tongue-like process and the adjacent part of the main body of the gland, is composed of ovarian tissue and represents the ovary on the left side.

The question as to whether the specimen is one of true unilateral hermaphroditism or not must be decided by the nature of the main part of the left genital gland. We

would contend that it represents the male type, and is testicular in character.

If an example of true unilateral hermaphroditism is ever to be met with in man, one would certainly expect that the two kinds of glands should be present in the same organ, as is the case in this specimen. The fact that in Heppner's case (*vide* p. 284) the two glands are separated from one another by some little distance appears to us to throw doubt upon the genuineness of Heppner's contention that they represent an ovary and a testis.

The relation of the major part of the left genital gland to the organ called by us the epididymis, is what one would expect if it represents a testis. We have already pointed out that they are united by fine tubules running in the portion of tissue uniting epididymis and genital gland. On examining the microscopic section passing through the gland near the hilum one can at once see that the tubules run together to the hilum and apparently leave the gland; and we have no doubt but that on further examination these tubules could be traced directly through the fine tubes mentioned above into the epididymis itself. Owing to the impossibility of determining this without spoiling the specimen for demonstration purposes, we have not been able at present to trace the tubules further than the hilum.

The microscopic section of the larger part of the left gland bears a very close resemblance to that of an early fœtal testis. It is true that there is a disproportionate amount of stroma present, but this is no doubt due to the mal-development of the gland in respect of its epithelial structures, a condition which, as we have seen, is also apparent in the case of the ovarian portion.

The arrangement of the tubules, their structure, and that of the cells lining them, all correspond to that of a fœtal testis. They run a definite course from periphery to hilum, where they become reduced in size and form a rete, and they are certainly tubules with a definite limiting membrane rather than cell nests, while the epi-

thelium contained within them is evidently all of the same character, no two definite kinds being recognisable as in the case of the ovary.

The large number of interstitial cells in the stroma gives it a still closer resemblance to that of a testis, as interstitial cells are much less numerous in the ovary.

There is one very noteworthy thing in the sections, and that is the masses of cells at the periphery, many of which are without the structure of tubules, but with which the tubules appear to be directly continuous. Their presence is, we think, due to the undeveloped condition of the specimen, and these masses of cells represent germinal epithelium, which has not yet taken part in the formation of cell-nests or cell-tubes, as the case may be. It might be contended that the tubules represent the tubules of the rete testis rather than seminal tubules, and that the organ is really an ovary with well-developed efferent ducts of male type. Our knowledge of the mode of development of the rete testis is at present very imperfect, but we think that the relation of the tubules to the masses of epithelium at the surface, and their apparent direct continuity, is sufficient to disprove this view.

If the organ were merely an hypertrophied Wolffian body, one would expect to find some traces of the glomeruli that are normally present in that organ, and structures resembling the ducts of the Wolffian body. We have, however, entirely failed to find any traces of glomeruli, while the tubules do not in the least resemble the ducts of the Wolffian body. We have, therefore, come to the conclusion, on consideration both of the microscopical appearances of the specimen and its anatomical relations to the equally well-developed epididymis and vas deferens, that this portion of the left genital gland represents a testis, and that the specimen is therefore one of true unilateral hermaphroditism with an ovo-testis present upon the left side.

We may now pass on to the cases recorded by other observers. Medical literature contains a number of re-

puted cases of true hermaphroditism, most of which were recorded many years ago.

An examination of these cases, however, reveals the fact that very few of them, if indeed any, will stand a more critical investigation than that given to them by their original observers.

We have collected twenty-eight such cases, viz. two of true unilateral, nine of true bilateral, and seventeen of true lateral hermaphroditism. We propose to give a short account of each of these, taken in every instance directly from the original description, except where it is otherwise stated, and then to discuss their value as proof of the occurrence of true hermaphroditism in man.

Cases of True Unilateral Hermaphroditism.

Brühl, in his essay on hermaphroditism, places under the head of the true unilateral variety two cases, viz. those of Paul Gast and Lilienfeld; but we shall see that while Gast's case may be one of true lateral hermaphroditism, there is no evidence that it is an example of the unilateral kind.

The specimen was one of a malformed fœtus with spina bifida and extroversion of the bladder. It had a uterus didelphys, the two portions connected together below by a solid band of tissue, possibly representing a vagina. The two halves of the uterus were composed of muscular fibres and connective tissue, and were continued into Fallopian tubes with well-marked fimbriated extremities, and a lumen admitting a fine probe. Close to the outer end of the left tube lay a small bean-shaped body, which on microscopical examination showed Graafian follicles and ova set in a connective-tissue stroma.

Situated at the lower end of the left kidney was a body about the size of a pea, prolonged below into a cord running to the left inguinal region. The microscopical structure of this body was that of a testis. In a connective-tissue stroma beset with long cells were open

canals running transversely and longitudinally, and a number of blood-vessels. In some places the lumen of the tubes was filled with round and polygonal cells lying close to one another, in which definite outlines of individual cells could not be distinguished. No microscopic examination of the band running to the left inguinal region was made, but it was considered by Gast to represent the gubernaculum testis.

No trace of the right ovary could be detected. The fœtus had been preserved for a year in spirit, and its condition was unfavourable for microscopical examination. There were present, then, in this case a uterus didelphys, two tubes, a left ovary containing Graafian follicles, and upon the same side a body described as a testis. It is a curious feature of the case that the two organs are situated on the same side, while on the opposite side there is no trace of any genital gland at all. No drawing of the microscopical appearances is given, but the description of the arrangement of the tubules in the testis would seem to correspond to that seen in a fœtal testis. There is no evidence of the presence of any excretory duct. One is forced to conclude that while this may be a case of true lateral hermaphroditism, it is not one of the true unilateral kind. Owing, however, to the malformations present, it is difficult to say what changes may not have taken place in the relations of the pelvic organs, even if we accept the fact that one organ is a testis, and the other an ovary.

The second case mentioned by Brühl is that of Anna Petrovitch, twenty-two years of age, who died in 1850 in the Vienna Infirmary, the condition of whose genital organs has been described by Lilienfeld from the notes of the post-mortem examination, and an accompanying drawing.

The following is his account:

"The uterus ended on the right side in a small blind extremity; lying close to the right internal abdominal ring is a well-formed testis, with epididymis and vas

deferens. The left uterine cornu is prolonged into a well-developed Fallopian tube. Lying in the left broad ligament is a parovarium, and close to this a swelling corresponding to an ovary." The latter organ contained no ova, but its exact structure is not given. The description makes no mention of any second gland upon the left side, but in the drawing a small body is seen to be connected with the ovary by a sort of pedicle, and to be also connected with the vas deferens upon that side. There is no evidence to show what this organ is on the left side. One can also determine from the drawing that the right uterine horn really ends in a tube-like body, with a small opening at its extremity, but with no fimbriæ; and that the vesiculæ seminales are present, and well developed.

The presence of well-developed vasa deferentia and vesiculæ seminales in Lilienfeld's case, together with the appearances of the two glands in the drawing, leads us to regard them as testes; but the absence of any microscopic examination prevents a definite conclusion being come to on the point, and it is impossible to accept the case as one of true unilateral hermaphroditism.

Cases of True Bilateral Hermaphroditism.

Of true bilateral hermaphroditism we have found nine cases recorded in the literature of the subject, but we shall see that the large majority of these are not genuine.

One of the earliest cases is that of Schrell, mentioned by Simpson and by Klebs. Unfortunately we have been unable to obtain the original description in Schenk's 'Archives,' and our account must therefore be based upon Simpson's. In an infant who died when nine months old, internal and external organs of the male type were said to be well formed. Externally there existed a well-developed penis, at the root of which was a small vulvar aperture, surrounded apparently by labia majora and labia minora. This aperture led into a vagina terminating above in an imperfect uterus, to which bodies having

some resemblance to ovaries and tubes were attached. No further description is given of the bodies described as ovaries, nor is there any detailed account of the so-called testes. The case is too imperfectly reported to be worth any detailed criticism. It is worth noting that the uterus was only imperfectly developed, and the organs attached to it are admitted to have borne only some resemblance to ovaries and tubes.

2. Béclard's case is founded upon a dried specimen and a wax model by Lemonnier in the Museum of the School of Medicine at Paris. The dried specimen is too old to enable one to distinguish the parts with certainty. The wax model, which unfortunately does not appear to bear much resemblance to the specimen, shows a uterus, two ovaries, a vagina, vulva, and clitoris. Two testes are also represented, the vasa deferentia of which terminate at the uterine cornua. Obviously no definite opinion can be expressed about such a specimen; while Simpson mentions that Houel, one of the former curators of the museum, characterised the description of it as a case of true bilateral hermaphroditism as "pure imagination."

3. Blackman described the following appearances in the person of a sailor, thirty years of age. He was manlike in his appearance, of large stature and with a moderate amount of hair upon the face. He preferred the society of females. The external genitalia, consisting of a penis and an apparently empty scrotum, resembled those of the male. On post-mortem examination a vagina, uterus, Fallopian tubes, ovaries, prostate, testes, and vasa deferentia were described as present. There was no microscopical examination carried out. A discharge of blood occurred monthly from the urethra, and was said to be attended with much suffering. Death occurred during one of these periods. In the sketch which accompanies the paper, no trace is to be seen of the vasa deferentia. The so-called testes are in the position of the normal ovaries, while the ovaries might be interpreted from the drawing as merely portions of a thickened and

convoluted Fallopian tube. The *pseudo*-menstruation which occurred in this case, and in the cases of Stark, von Franqué, Klotz, Messner and Fowler, is not at all an uncommon occurrence in cases of hypospadias, and is not evidence of true hermaphroditism.

4. Vrolik had the opportunity of examining after death an individual, fifty-eight years of age, who had consulted him during life with regard to his sex. At seventeen years of age the testes began to descend through the inguinal canals, and a copious beard appeared upon the face. He had, up to this, been considered a female, and he continued to dress as such until the age of thirty-eight. At this time he was examined by three medical men, of whom Professor Vrolik was one, and they gave him a certificate to say that he was a hypospadiac male. On dissection after death Vrolik found the following anatomical conditions present:—On the left side were an ovary and a testis near together; on the right side the same parts less developed; there were two rudimentary Fallopian tubes, and two better developed vasa deferentia. There was no trace of prostate or vesiculæ seminales. A uterus and vagina were found, ending in a urogenital canal which opened at the root of an imperforate penis. The labia united to form a scrotum, the right half of which contained an inguinal hernia. The Fallopian tubes ran from the uterine cornua through the inguinal canals, and were lost upon the tunicæ vaginales. The right testis, when divided, showed transverse septa, but no tubuli seminiferi. In a glutinous fluid obtained from it the microscope detected nucleated cells, but no spermatozoa. The right vas opened into the cavity of the vagina, the left into the angle of the uterus. The stroma of the right ovary was contracted and indurated at the periphery, but no Graafian follicles could be detected.

There is nothing in the description or in the drawing to show the nature of the organs upon the left side, and the entire absence of Graafian follicles tends to negative the assumption that one of the right genital glands is an

ovary. The drawing accompanying the original description is a very imperfect and poor one. No doubt it correctly represents a testis on either side enclosed in the tunica vaginalis, but it does not in the least enable one to come to any conclusion as to the nature of the second organ.

5. Brühl includes a case under the heading of true unilateral hermaphroditism said to have been recorded by Fowler. The individual had ovaries and testes well developed, while menstruation and micturition occurred through the penis.

Unfortunately, we have entirely failed to find the original description of this case, so that we cannot express an opinion as to its authenticity. Brühl's reference is erroneous, and none of the other writers upon the subject refer to the case.

6. In Reichert's 'Archives' for 1870, Heppner records the case of a premature child who died at the age of two months. The external genitalia were of female type, such as occur in cases of perineo-scrotal hypospadias. A urogenital sinus opened at the base of an imperforate penis, and was continued into a vagina 2 cm. long. A prostate was present, surrounding the urethra and vagina. Attached to the uterus, which was of fœtal type, were two well-developed Fallopian tubes and two ovaries. On each side, close to the ovary, there was a testis, and between them an organ resembling the parovarium. The round ligaments were present in their normal situation, and passed into the inguinal canals. No vasa deferentia could be found. On microscopical examination the ovaries presented, towards their centre, a number of bodies resembling Graafian follicles; these were bounded by a definite membrane lined by a layer of epithelial cells, their cavities filled with uniform granular cells with here and there a larger clear cell, apparently an ovum. In some of the larger follicles a clear zone was seen between the membrana granulosa and the ovum, due to the presence of fluid.

The testes were covered by a capsule externally,

beneath which lay a series of tubules running vertically to the surface, and anastomosing near the hilum so as to form canaliform spaces. The walls of the spaces presented a hyaline structure in which neither striæ nor nuclei could be recognised, and they were lined with cells of variable size with granular protoplasm. Here and there the lumen of the tubes was filled up with a yellowish mass which could not be resolved into cells, while the canaliform spaces near the hilum were filled with a number of small nuclei.

This specimen is the one that is most frequently quoted as an undoubted instance of true bilateral hermaphroditism, but the proof cannot be said to be entirely satisfactory. Ovaries were certainly present, and had the typical structure of such organs. The two bodies lying close to the ovaries showed tubules with hyaline walls filled with cells, running towards a hilum. Unfortunately, no good drawing of the microscopical appearances accompanies the paper. From the description the two bodies may well be rudimentary testes; they certainly do not resemble persistent Wolffian bodies. No vasa deferentia were present, and one is not told anything about the ultimate termination of the tubules. Slavjansky thought the two glands ill-developed ovaries. The microscopical characters appear to bear a very close resemblance to those of the body we have endeavoured to show is a testis; but the description is not so full as one would wish. The case is one in which the presence of bisexual genital glands is very probable, but where it cannot be said to be entirely proved.

7. In a paper on hermaphroditism in the 'Guy's Hospital Reports,' Durham published the case of an individual twenty-five years old, who during life had been regarded as a female.

The mammæ were well developed, the nipples and areolæ virgin-like. There was a hypospadiac penis and small scrotum containing normal testes with epididymes, and vasa deferentia. Lying above the testis on either side was a small lobulated body, on section apparently

composed of fibrous tissue and fat, which Durham looked upon as an ovary. No microscopical examination was made. This case is interesting as showing upon what extremely slight foundations the diagnosis of true hermaphroditism was at one time based. From the drawing the two accessory tumours might very well represent fatty tumours of the cord, absolutely no evidence being forthcoming to show that they are ovaries.

8. The case of Matthieu Perret, who died at the age of sixty-four, is quoted by Odin as one of true bilateral hermaphroditism. He was of masculine form, with very little hair upon the face, a bachelor, and showed no inclination towards either sex.

The breasts were of male type, with well-formed nipples. He possessed a hypospadiac penis with bifid scrotum. The latter had the appearance of two large labia, and was covered with hair on its external aspect. A small body the size of a pigeon's egg lay close to the external abdominal ring. A urogenital canal led anteriorly into the bladder and posteriorly into a vagina 8 cm. long. The prostate was completely absent. The vagina, the orifice of which was incompletely closed by a hymen-like membrane, was directly continuous with the well-developed cervix uteri. The body of the uterus was rudimentary, and terminated in a long, cord-like structure directed to the left. This passed into a fleshy mass enveloped in peritoneum, and situated at the left internal abdominal ring. This mass contained an ill-developed testis surmounted by a voluminous epididymis, and an imperforate tube. The pavilion of the latter was well formed, and the fimbriæ were directed towards an elongated, convoluted body, presenting some small cysts upon the surface. This body was apparently the ovary, although the microscope did not show any Graafian follicles. Between the tube and the ovary a rudimentary organ of Rosenmüller was present. On the opposite side of the body the fleshy mass was also found, and the same structures were included in it, but the testis and the cord passing to the uterus were a little less developed. The right

vas deferens, but not the left, could be traced to the vesicula seminalis, both of which were present in their usual position at the base of the bladder.

This case is apparently that of a hypospadiac male with undescended testes, and a rudimentary uterus with imperfect tubes—an example of what Klebs terms *pseudo-hermaphroditismus masculinus completus.* The bodies called ovaries showed none of the appearance of that organ under the microscope.

9. Arigo and Fiorani's case is unfortunately incomplete owing to the absence of any microscopic examination. The individual was sixty-eight years of age, and died in hospital. He possessed an imperforate penis and bifid scrotum containing two atrophied testes. On internal examination they found a virgin uterus with Fallopian tubes and ovaries. The vagina opened into a urogenital sinus at the root of the penis. The authors intended to investigate the structure of the ovaries further, but, owing to an unfortunate misunderstanding, they were unable to do so; proof is therefore wanting as to the exact nature of the organs present, and as it stands the case is too incomplete to be accepted.

Cases of True Lateral Hermaphroditism.

The cases of true lateral hermaphroditism which we have to consider next are, as regards some of them at any rate, more satisfactory than the preceding, since the most recently reported cases have been instances of this condition.

1. The earliest authenticated case of true lateral hermaphroditism is that met with by Sue in 1746 in a young person thirteen or fourteen years of age. The external organs resembled those of a hypospadiac male, and during life he had always been looked upon as belonging to the male sex. At the root of the penis was the opening of a urogenital sinus common to the vagina and urethra. A uterus was present with a Fallopian tube, ovary, and round ligament upon the left side. On the right was a

slender elongated body close to the internal abdominal ring called by Sue a testis; this terminated in two tubes which finally united into one and ended in the angle of the uterus on the right side. A histological examinationwas not made.

The slender elongated body with the two tubes ending in one at the angle of the uterus, would correspond much better to an ovary than to a testis, as Sue calls it, but in the absence of any microscopic examination we cannot say what it is.

2. Maret relates in detail the case of Hubert Jean Pierre, aged 17, who died in hospital at Dijon in 1767. During life Pierre, who had a delicate skin and a somewhat feminine type of figure, had been considered a male, but had never shown any partiality for the opposite sex. The mammæ were large and well developed, there was no appearance of any beard and no projection of the larynx. The penis, four inches long, was imperforate, and contained a corpus spongiosum. At its root was a large fissure bounded by two folds like labia; the left of these contained a small body like a testis; the right was empty. Immediately below the opening of the urethra was a small aperture partially closed by a hymen-like membrane leading into a cul-de-sac about one inch in length. Dissection displayed on the left side the presence of a well-formed testis with spermatic vessels, vas deferens, and vesicula seminalis; the latter contained fluid resembling semen. On the right side an oblong cystic tumour was found lying in the iliac fossa; this contained a small round body giving off towards the right a Fallopian tube, close to the fimbriated end of which lay an organ like an ovary. The small round body contained a cavity continuous with that of the tube, and from the structure of its walls appeared to be a uterus. On the same side there was a small shrivelled vesicula seminalis and a vas deferens which gradually disappeared without being connected with any structure resembling a testis. No description is given of the appearance of the various structures on section. The presence of the vas deferens and

vesicula seminalis on the right side, and the presence of a corpus spongiosum in the penis, might lead one to consider the so-called ovary a testis, especially as there is no microscopic proof to the contrary. The excessive development of the mammæ is of no importance; this is a condition not at all uncommon in males.

3. In 1754 the anatomist Varole dissected the body of an individual, eighteen years of age, who died at the Hotel Dieu, and found the following condition of things. The mammæ were well developed. The external organs were of male type, with partial hypospadias. On the right side the scrotum contained a testis with vas deferens, the latter opening into the external border of the corresponding vesicula seminalis. The left half of the scrotum was empty, but internally on the same side a small uterine body with no neck, a Fallopian tube, ovary, and broad and round ligaments, were found. The right vesicula seminalis and the body of the uterus apparently communicated by a canal 1½ inches in length. No further description is given of the two genital glands.

If the anatomical details of this case are correct it may have been an example of true hermaphroditism, but in the absence of any microscopical examination one cannot consider it as a certain example.

4. Rudolphi recorded the case of an infant dying seven weeks after birth. There was a hypospadiac penis. The right half of the scrotum contained a testis with epididymis and vas deferens; the left half was smaller and empty. At the base of the scrotum was the opening of a small urogenital sinus. A rudimentary prostate was present below the uterus; connected with the left side of the latter was a Fallopian tube and ovary, with maldeveloped broad ligament, and round ligament. The uterus terminated below in the wall of the prostate; the vas deferens also passed through the side of the latter, and probably opened into the sinus urogenitalis. There were no vesiculæ seminales.

The end of the so-called vas deferens on the right side,

as represented in the drawing, has the appearance of the fimbriated end of the Fallopian tube rather than of the epididymis, as it is described. The ligament of the so-called testis passes to the right angle of the uterus, and the real explanation of the case would appear to be that there was a hernia of the right ovary and appendages, with a persistent duct of Gartner on the right side, and that the individual was a female.

5. One of the most interesting cases of hermaphroditism is that of the celebrated individual Carl Durge or Maria Duriée. He was looked upon and brought up as a female until forty years of age, when he was persuaded to change his name and dress to that of a male. During his life he travelled all over Europe, and was examined by numerous medical men, who held the most divergent opinions as to his real sex. Thus, amongst others, Osiander, Rosemüller, Cooper, and Lawrence considered him a male; Hufeland, Mursinna, Gale, and Brooks thought him a female; while Schneider, Lauth, and Metzger held that he was a neuter. He was born at Potsdam in 1780, and Stark records that he met with a severe injury to his head in his youth which may have interfered with his development. He had some predilection for the female sex, but no sexual desire.

He died in 1835 at Bonn, and the post-mortem examination was made by Mayer. The penis was small and imperforate, but reached a length of 3 inches during erection; there was no corpus spongiosum. At the root of the penis was a circular orifice leading into a sinus urogenitalis, opening into urethra and vagina; the latter was 2¾ inches in length. The uterus, 2½ inches long, was in the middle of the pelvis, with the fundus directed a little to the left. Two Fallopian tubes, closed at their abdominal ends, but with well-marked fimbriæ, opened into the cavity of the uterus. On the right side, near the end of the Fallopian tube, was a small almond-shaped body covered with peritoneum. On section it presented a yellowish-white appearance like that of the testis, and

seminiferous canals could be seen in it. Outside and behind the extremity of the left Fallopian tube another small flattened body was found, resembling an ovary. On section it is said to have possessed a granular parenchyma composed of separate glomeruli, and on this description is based the statement that it resembled an ovary rather than a testis.

The measurements of the pelvis were those of a male. The right hemispheres of the cerebrum and cerebellum were smaller than those of the left side.

The weak point in this case is the microscopic appearance of the ovary. If it really contained glomeruli it is much more likely to have been a remnant of the Wolffian body than an ovary. The anatomical relations of the two bodies appear to have been much the same, both being covered by peritoneum. It is to be noted, too, that there is no vas deferens or vesicula seminalis present upon the left side.

6. Barkow had the opportunity of examining the body of a man whom he had treated for impotence. The individual was fifty-four years of age, married, and his wife had borne him one daughter. The penis was imperforate. The right half of the scrotum contained two bodies, distinctly palpable; the left half was empty, and rather resembled a labium majus. A prostate was present. The swelling in the right half of the scrotum was found to consist of a hernia of the uterus. Close to the uterus, the walls of which had a normal appearance, lay two bodies; one, eleven lines by seven, was surrounded by a fold of peritoneum like a tunica vaginalis, and on section had a light yellowish-brown parenchyma, through which, in the recent state, fine thread-like canals could be seen passing. The second body lay below, behind, and internal to the first. Anteriorly it was united with a band which passed to the sac wall. From its middle a round, cord-like structure, corresponding to the ligamentum ovarii, passed to the side of the uterus. This so-called ovary was sixteen lines long, and consisted of

connective tissue, fat, and blood-vessels. No vesiculæ seminales were present, nor was there any trace of the Fallopian tubes. Barkow states that close to the first body, which he calls a testis, was another body like an epididymis. The vas deferens was, however, entirely wanting, and the specimen was partly spoilt during removal. He thought that if he had been able to examine the specimen in the fresh state he could have demonstrated Graafian follicles and seminal tubules. The presence of ovarian tissue is not proved in this case, since no ova or Graafian follicles were detected in the so-called ovary, and consequently the case cannot be looked upon as one of true lateral hermaphroditism.

7. In a full-term child that died soon after birth, Berthold found a small imperforate penis with a urogenital cleft at its base. Between the rectum and the bladder lay a single-horned uterus, the right appendages of which were wanting. Attached to the left of the uterus was an ovary, Fallopian tube, and round ligament. The ovary, on microscopical examination, failed to show any of the appearances of the normal organ, although to the naked eye it presented all the characters of the fœtal ovary. A body resembling the parovarium was found between the two layers of the broad ligament above the ovary. In the right half of the scrotum lay a testis with epididymis; the vas deferens, passing into the abdomen along the side of the uterus, penetrated its wall and opened into the sinus urogenitalis. The testis had the normal appearance of that organ. The vesiculæ seminales and prostate were absent. The arrangement of the vas deferens in this case corresponds to that described in Rudolphi's. The ovary in the drawing looks like a fœtal ovary, but the microscope failed to confirm its external appearance.

8. In 1851 Dr. Banon described the case of a supposed male, aged twenty-six, who died in Dublin prison. He was baptised as a girl, but, owing to the increase in size of the organ representing the penis, he was brought up

as a male. His general appearance, his voice, and his sexual feelings were all masculine in character.

The penis was imperforate; at its base was a urogenital sinus leading into a vagina. The uterus and broad ligaments were present. On the left side was a permeable Fallopian tube, and an ovary lying in the pouch of Douglas. There was no trace of any uterine appendages upon the right side. Lying also in the pouch of Douglas was a testis with an epididymis and vas deferens belonging to the right side, the latter opening into the uterus at its lowest part. There was no vesicula seminalis or prostate. The testis is said to have the structure peculiar to this organ, but no spermatozoa could be found. On microscopical examination the ovary presented the appearance of fibrous tissue and fat granules with no trace of any Graafian follicles or ova. The curator informs us that this specimen is still preserved in the Museum of the Royal College of Surgeons of Ireland, and that to naked-eye examination it agrees very well with Banon's description. The drawing of the microscopical appearance presents not the slightest resemblance to the structure of the normal ovary. Unfortunately the specimen does not appear to be fit for any further microscopical examination, while, in default of this, it cannot be accepted as a case of true hermaphroditism.

9. The case of an individual twenty-two years old, who died of peritonitis, is related by Gruber. He had an imperforate penis with sinus urogenitalis and well-developed prostate. The scrotum was divided into two halves by a median raphe. The vagina, 8 cm. long, led into a uterus of the same length, the distinction between the two being well marked. On the left side was a broad ligament, normal Fallopian tube, round ligament, organ of Rosenmüller, and ovarian ligament. Attached to the left broad ligament in the usual position of an ovary was a tumour having the structure of a medullary carcinoma. Although no ovarian tissue could be recognised, Gruber was certain the growth began in the ovary. He based

this belief upon the way in which it was attached to the uterus and the Fallopian tube, and upon its relation to the broad ligament.

The right broad ligament was only partially developed, and 6 cm. from its point of attachment to the uterus there was an opening in it leading to the processus vaginalis. Lying close to the right external abdominal ring was a testis with epididymis and vas deferens; the epididymis lay in the inguinal canal, but the vas could not be traced beyond the internal abdominal ring, where it was lost. The microscopical examination showed a number of seminal tubules separated from one another by septa, as in the adult testis. The canals were lined with a layer of polygonal cells, and contained in their interior mainly pale granular cell nuclei. Their diameter was a little less than that of the corresponding tubes in the adult organ. In the drawing accompanying this case, the tumour certainly appears to be situated in the position of the ovary, and has the anatomical relations of that organ. Primary carcinoma of the ovary is a very rare disease, and there is no mention of any growth elsewhere. It is admitted, further, that no trace of any ovarian tissue remained, and under the circumstances we cannot consider that it is certain that the ovary was originally present.

10. In 1878 a patient was operated on in Billroth's clinique for a cystic tumour in one half of a divided scrotum. The operation resulted fatally from the slipping of a ligature, and an examination of the parts by Klotz led him to the conclusion that it was a case of true lateral hermaphroditism. The individual, twenty-four years of age, is said to have had an appearance resembling both the male and female types. He had broad shoulders, and big arms, but well-developed mammæ like those of a woman of the same age, while his voice was a high tenor. The external genitalia presented the following appearances. Between two folds, like the folds of a divided scrotum, lay a small imperforate body resembling a glans penis,

capable of erection. At its base was a small opening surrounded by two folds like labia minora. This opening led into a urogenital sinus communicating with both the urethra and vagina. The latter was only imperfectly marked off from a one-horned uterus. The uterus was continued on the right side as a spindle-shaped body having a small appendix attached to it at its centre, and terminating by a constricted portion, the Fallopian tube, in a cystic swelling occupying the right half of the scrotum. The cavity of the spindle-shaped body communicated on the one hand with the uterus, and on the other hand with the tube and the cystic swelling. At the posterior and inner part of the right half of the scrotum was a small fistulous opening which communicated with an opening in the appendix-like body. In the left half of the scrotum lay a normal testis with epididymis and vas deferens, which terminated, after passing through the lower part of the cervix uteri, in the siuus urogenitalis, just at the commencement of the urethra. The vas deferens presented, at its distal end, an indication of a small vesicula seminalis.

Klotz made a careful microscopical examination of the parts. He found that the left genital gland had the typical structure of a testis. The cyst removed was mainly made up of thin-walled spaces filled with a yellowish turbid fluid. The solid parts consisted of connective tissue containing a large number of vessels, giving it the appearance of a cavernous tissue "not unlike the medullary tissue of an ovary." In small portions towards the periphery it consisted of an avascular connective-tissue stroma containing globular structures completely filled with cells. In other parts cavities were cut across with a limiting membrane and filled with cells; these cavities showed all transitions from solid strands of cells to definite gland-like spaces with a well-marked lumen and a lining of cylindrical cells. The larger spaces were lined with cubical or flattened epithelium, while some of the smaller ones contained ciliated epithelium. The fluid contents

showed the same varieties of epithelium, mostly in a state of fatty degeneration.

Inquiry elicited the fact that up to ten years of age the two scrotal halves were of the same size. At this time attacks of pain set in, recurring every four weeks and lasting from three to four days. At eighteen years of age, with each monthly attack a discharge of bloody fluid occurred from the fistulous opening upon the right side, and from the sinus urogenitalis. During the last two years the attacks of pain had increased in severity and duration to such an extent that the patient was compelled to seek some relief from them.

The question to be decided in this case is whether the tumour in the right half of the scrotum is an ovarian cyst or a degenerated testis.

Klotz puts forward the following reasons for thinking it an ovarian cyst.

1. The fact that its structure resembles that of an ovarian cyst.

2. The presence of a round ligament upon that side which he says is not present, according to Klebs, when there is a vas deferens.

3. The presence of well-developed nymphæ.

4. The occurrence of menstruation ; and

5. The fact that cystic degeneration of an ovary is much commoner than that of a testis.

With regard to these arguments, it must be conceded that the structure does appear to resemble that of an ovarian cyst. If it be a cyst, however, it is one of the rare forms of tubo-ovarian cyst with the end of the Fallopian tube opening into the cyst cavity.

Klotz says that the proximal part of the tube leading to the spindle-shaped body can be resolved into three portions, a hollow tube, a round muscular band he calls the round ligament, and a bundle of blood-vessels and nerves. If the spindle-shaped body be a part of the uterus, as its structure leads us to suppose, then the muscular band internal to it cannot be the round liga-

ment, since the latter is always attached to the junction of uterus and tube, and marks off the uterus from the tube; so that it is doubtful if the body he calls the round ligament is really that ligament at all. The presence of nymphæ and the occurrence of menstruation are of no importance in determining whether an individual is a true hermaphrodite or not, since, as we have already said, the only factor of importance is the presence or absence of the different genital glands. The only arguments of Klotz's, then, that seem to hold good are the fact that the tumour resembles an ovarian cyst, and the further fact that cystic disease of the ovary is much commoner than that of the testis. The drawings of the microscopical appearances do not help one much either one way or the other, but they certainly do not in the least resemble that of any tumour of the testis.

11. The description of Messner's case suffers from the fact that it is the result of an examination during life only. The individual was thirty-one years of age, had been married for seven years, and his wife had borne him one daughter. He went to a boys' school until the age of fifteen, when the breasts began to develop like a girl's. His voice was a high soprano. There was no sexual inclination at any time towards males. In his twenty-first year spontaneous bleeding occurred from the urethra, which returned every four weeks and lasted from three to four days. The amount of blood lost the first day was so great as to compel him to wear bathing drawers. During the first year the amount lost was excessive, but during the last twelve months it had diminished until it amounted to only a few drops, or at most a drachm. It is an important fact that this *pseudo*-menstruation lasted ten years without any intermission. Messner observed four menstrual periods himself, and has given a careful description of them. During the first two days the patient complained of listlessness and dragging sensations in the abdomen, with pricking and stabbing sensations in the breasts. On the third day the abdominal pain became so

intense as to require the application of hot flannels; it continued from six to eight hours, and was terminated by the escape of a few drops of pus and slime from the urethra. After the cessation of the period the sexual feelings were markedly increased. He was of feminine build, had no beard or moustache, while the breasts were pendulous and well developed. He possessed a hypospadiac penis 6 cm. long, on the under aspect of which, 3 cm. from the end, was an opening leading into a sinus urogenitalis. The right testis, which was the size of that of a full-grown man, and possessed an epididymis, was situated at the external abdominal ring. On the left side there was a genital gland present in the inguinal canal, the nature of which was not so certain. The prostate felt normal. No trace of any uterus could be detected. A small body could be felt in the pelvis. This was painful on pressure, freely moveable, and prolonged towards the middle line into a cord-like structure. In size and form this body resembled an ovary. Nothing similar could be felt upon the left side. Movements of this body had no effect upon the testis. The semen contained no spermatozoa.

Messner acknowledges the occurrence of urethral bleeding simulating menstruation in cases of hypospadias, but thinks that it was too regular in this case, and the presence of another pelvic organ too certain to admit of anyone doubting but that the latter organ was an ovary. It is obvious, however, that we cannot accept a diagnosis of true hermaphroditism upon the result of a physical examination alone.

12. Obolonsky re-examined and described a specimen which had been twenty years in spirit. The external genitalia appeared at first to belong to the feminine type, the enlarged clitoris being the only remarkable thing about them. This organ was embedded between two folds of skin like labia majora, which formed a prepuce for it. Two smaller folds like labia minora passed backwards to the sides of a sinus urogenitalis. The bladder

was normal; the urethra, 4 cm. long, opened into the sinus urogenitalis. A prostate and colliculus seminalis were also present. The vagina, the opening of which was furnished with a hymen-like fold of mucous membrane, was 6·5 cm. long, and 2·5 cm. across. It passed into a cervix, 5 cm. long, with well-marked palmæ plicatæ, terminating in a bicornate uterus. The left horn, well developed, was 6·5 cm. long, while the right, almost undeveloped, was the size of a pea. The left broad ligament passed downwards towards the left labium majus; embedded in it lay a cord-like structure 3·5 cm. long, and 4 mm. thick; this expanded at its end into a swelling 3 cm. by 1·5 cm. About the middle of the cord was a small opening admitting a uterine sound as far as the left horn of the uterus. At its expanded end the cord showed upon its inner side longitudinal folds of mucous membrane, and ended in a cyst-like body with a blunt-pointed extremity. This body, wrongly described in the original description as a testis, was lined by plicæ of mucous membrane, while under the microscope it showed the typical structure of the infundibulum of the Fallopian tube. Lying parallel to and above the tube was another body, originally called the vas; this structure was 3·5 cm. long and 5 mm. wide, covered by peritoneum, and attached to the left horn of the uterus by a definite ligament. It showed, on microscopical examination, a definite tunica albuginea, a stroma rich in nuclei, containing large and small cavities filled with altered but still recognisable epithelium. Amongst the masses of epithelium were clear vesicular cells like ova, while nearer the centre the stroma contained a number of blood-vessels. The structures in the left broad ligament appear then to represent an ovary, with its ligament, a Fallopian tube, and a round ligament. Attached to the edge of the right broad ligament, remote from the uterus, was an ellipsoidal flattened body 2 cm. by 1·5 by ·5. This was composed on examination of a fibrous stroma forming a species of mediastinum at the hilum, while the parenchyma proper consisted of closely

placed tubules filled with round granular epithelial cells. These tubules were surrounded by a capsule of connective tissue, and were collected into groups separated from one another by the trabeculæ, which contained large vessels running in their substance. Running obliquely downwards from the testis-like body was a band 3 cm. long by 6 mm. wide, divided by a longitudinal furrow into two parts, an upper and a lower. The former showed on section a canal covered by layers of longitudinal and circular muscular fibres, and lined by mucous membrane; while the latter consisted only of a blood-vessel. Along the free edge of the ligament was a band, said to be composed of coni vasculosi, and terminating in a small hydatid; in his drawing Obolonsky terms this the epididymis. From the right horn of the uterus a hollow tube ran to the lower and outer part of the broad ligament, and terminated in a fimbriated end; this tube was joined a short distance from its apparent commencement by a solid ligamentous structure, evidently the round ligament. The ultimate termination of the vas deferens could not be traced, owing to the manner in which the broad ligament had been cut across. This appears to us to be the only undoubted case of true lateral hermaphroditism that has so far been recorded. Microscopically, the two glands correspond definitely to an ovary and a testis. It is unfortunate that no history is forthcoming of the appearance and habits of the individual from whom the specimen was obtained. It is greatly to be regretted, too, that the termination of the vas deferens cannot be traced, and that the specimen should have been reported without any drawings of the microscopical appearances. If true hermaphroditism is to be considered as the presence in one individual of bisexual genital glands, without any reference to the development or mal-development of the genital tract, then this is undoubtedly a proved case of true lateral hermaphroditism.

13. Czarda's case is a specimen from a female child which weighed 1·9 kilos., and measured 45 cm. in length.

He claims that it is a case of hermaphroditism because of the appearance of the external genitalia, and by Brühl it is placed in the class of true hermaphrodites. The external genitalia consisted of an imperforate penis with a large glans, and a bifid scrotum apparently containing testes. At the root of the penis was a small rhomboidal opening, the margin of the opening split anteriorly into two parts like labia minora, one portion passing to the root and the other to the dorsum of the penis.

Czarda says he records the case because the external appearances resemble so closely those in the cases of true hermaphroditism recorded by Berthold, Barkow, and Mayer.

14. In Brühl's essay there is a case attributed to Verdier, in which there was a penis with the opening of the vagina below it. On the right side there is said to have been a testis, vas deferens, and vesicula seminalis; on the left a tube and ovary. The reference given by Brühl to this case is incorrect, and we have completely failed in our attempts to trace the case, and to find the original description.

15. In Virchow's 'Archiv' is to be found the case of an individual twenty-two years of age, related by Schmorl. He was of masculine appearance with a high tenor voice. The external genitalia consisted of a rudimentary scrotum and a hypospadiac penis. In the right half of the scrotum was a small body like a testis, while the left more rudimentary half felt empty. The patient was successfully operated on for the hypospadias. Some little time after this a swelling appeared in the left inguinal region, accompanied by pain and vomiting. This was cut down on, and what was thought to be a degenerate testis was removed, but unfortunately the patient died. At the post-mortem examination the following condition was present:—The uterus directly continuous with the vagina ended in two horns; of these the left was prolonged as a hollow cord-like body to the left inguinal region, where it ended in the tissues ligatured at the

second operation. The right horn was also prolonged into a band of tissue, which passed to the right inguinal canal, and ended in a sac of peritoneum in the right half of the scrotum. This band of tissue could be resolved into three parts, one ending in a fimbriated extremity, and representing the right Fallopian tube, another representing the round ligament and passing to the bottom of the processus vaginalis; and a third the main continuation of the right uterine horn ending in the body felt in the right inguinal region by external examination. This body, which in shape resembled a testis, measured 6·25 cm. by 4·25 cm., and was covered externally by a tunica albuginea which sent trabeculæ into its interior. The parenchyma proper was composed of fine tubules, visible to the naked eye, which at the point of attachment of the organ ran together, and ended in a small tubercle not unlike an epididymis. A bundle of fibres corresponding to the gubernaculum testis reached from the outer part of this body to the bottom of the processus vaginalis.

The microscopic examination confirmed the view that the organ was a testis, except that spermatozoa could not be discovered, nor did the so-called epididymis contain any canals, but only tubules similar to those contained in the main body of the gland. There was no trace of any vas deferens. In the tissue below the Fallopian tube and the testis were some fine tubules like those of the parovarium. An examination of the tissue removed at the second operation revealed the fact that the greater part of it consisted of a convoluted tube with a definite lumen reaching as far as the ligatured portion. A small body about the size of a pea was found lying close to the tube, evidently representing the genital gland of the left side. This structure had been cut in half at the time of the operation, but the second half could not be discovered. On microscopical examination this body was found to be covered by a layer of cylindrical cells, and to consist mainly of a stroma of fibrous tissue with elongated spindle-cells.

Scattered through the fibrous tissue were small ball-like masses of cells, consisting of spherical cells with granular protoplasm and large nuclei and nucleoli. In some of these cell-masses fine fibrous threads from the ground substance could be detected passing between the individual cells. The cells in some of the nests were larger towards the centre than at the periphery, but a limiting membrane was wanting in most of them. There were also a few cylinder-like depressions of the covering epithelium, and some large spaces lined by a single layer of cubical epithelium, filled with granular débris, but with no trace of any ova.

Schmorl gives a drawing of the microscopical appearances of the gland on the left side, and it certainly resembles a poorly developed ovary. The fibrous stroma is rather abundant, but what look like cell-nests and developing Graafian follicles are undoubtedly present, and the section has no resemblance at all to that of a testis, tubules being entirely absent. The testis on the opposite side did not possess any definite epididymis, and the vas deferens was absent. No drawing of the microscopical appearance of the testis is given. In spite, however, of the deficiency of its excretory ducts, one cannot regard the gland as anything else but a testis, while the left genital gland would certainly appear to be an ovary. We can therefore consider this as a case of true lateral hermaphroditism in which the diagnosis has been established by the microscope.

16. One of the cases most frequently quoted as an example of true lateral hermaphroditism is that recorded by Meyer. The specimen was obtained from a new-born child. The external genitalia resembled those of a male child with hypospadias. The left scrotal sac contained a testis-like body, while the right was empty.

There was a small prostate present with a well-marked colliculus seminalis. At the side of the latter were a number of small openings, no doubt those of the prostatic ducts, and two large openings, of which one led into the vagina, and the second ended blindly.

A small vagina and uterus were present with Fallopian tubes, broad and round ligaments, and parovaria on either side. On the right side, according to Meyer, was an ovary, and on the left side a testis.

The opening on the under aspect of the glans penis led into a urogenital sinus 4·5 mm. deep.

The uterus was only marked off from the vagina by the thickness of its walls, and by the palmæ plicatæ present in it. A cord passed from the left genital gland to the left upper angle of the uterus, and was thought from its position to be a vas deferens; it contained a lumen extending for a distance of 30 mm. from the testis.

The testis was situated in a large processus vaginalis, the presence of which accounted for the greater size of the left half of the scrotum.

Cramer in his description says that the interpretation of the specimen depended not alone upon a naked-eye, but also upon a careful microscopical examination. Curiously enough, Meyer in his account does not allude to any microscopical examination.

Förster says the so-called ovary may be rudimentary, since ova and Graafian follicles could not be detected; what ground he has for this statement does not appear.

Klebs, in a further examination which he carried out, found the following structure:—The stroma consisted of a dense fibrous tissue with many nuclei not unlike the rete testis, and was tunnelled by branching and anastomosing canals, 8—20 μ in width. These canals presented no proper walls, but the surrounding tissues formed a double contour, and their interior was filled up with polygonal cells containing granular protoplasm and well-marked nuclei. In some of the larger canals there were large brighter cells, measuring $11{\cdot}4 \times 7\ \mu$, which Klebs designated as primordial ova, since such cells do not occur in the rete testis. It is true these cells did not correspond to the size of the ova in the new-born fœtus, which, according to Waldeyer, measure 18—24 μ, but they corresponded to the narrow spaces

in which they lay. A large round cavity, measuring $80 \times 64\,\mu$, surrounded by concentric fibres, was called by Klebs a Graafian follicle, although there was no trace of an ovum in it, and the contents consisted merely of a granular mass with a few nuclei scattered through it. It was too large to be a blood-vessel.

The weak point in this case is the microscopical appearances of the so-called ovary. To naked-eye examination it certainly closely resembles a fœtal ovary, and its anatomical relations point to the same conclusions. The microscopical evidence is, however, defective. Klebs expressly states that no definite Graafian follicles are present, although further on he describes a space—containing no ovum, however—which may have been such a follicle. The fact that the tubules possess no definite limiting membrane, and that they contain two varieties of epithelium, points to their being cell columns rather than tubules. In the face of the unsatisfactory microscopical examination, we can only say that entire proof that the right gland is an ovary is wanting; but on the whole it appears most probable that it is of this nature, and that the specimen, therefore, is really a case of true hermaphroditism.

17. The last case, that of Catherine Hohmann, is of great interest, owing to the fact that such a large number of medical men have examined and reported upon it.

The individual was born in Bavaria in 1824, and spent the first forty-six years of her life as a female. In the fifteenth year seminal emissions occurred. In her nineteenth year an irregular discharge of blood took place from the urethra, re-appearing every three to four weeks, and lasting from three to four days; this was said to have been accompanied by the usual menstrual molimena. As she approached the fortieth year the amount lost gradually decreased, and the menopause occurred about the forty-third year. At the age of forty-eight Catherine Hohmann married and proceeded to America.

The most thorough examination of the case was made by Schultze.

He found a well-developed penis with marked hypospadias; a scrotum, containing in its right half a testis, the left half empty; a urogenital sinus, leading to a canal terminating towards the left side in a body representing the uterus masculinus. From this a cord passed off to a small moveable tender body felt in the left half of the pelvis, apparently the left genital gland.

Prostate and vesiculæ seminales appeared to be absent.

In the fluid emitted spermatozoa were found, and during life Catherine Hohmann undoubtedly fulfilled, though imperfectly, male and female sexual functions. It is interesting to note that the male characteristics first became marked towards the time at which menstruation ceased. There appears to be no doubt that a discharge of blood actually did occur from the urethra. Von Franqué, in 1869, personally observed some of the periods. Epistaxis usually occurred at the same time, and it is said that fraud was practised by Hohmann in regard to her menstruation; but this seems impossible, as she was closely watched.

Post-mortem examination alone can show that the organ on the left side is an ovary, and as far as we can ascertain such an examination has not yet been made.

Dr. Paul Mundé, who examined the patient very carefully in 1875, kindly informs us that, as far as he knows, the individual is still alive; he has neither heard nor seen anything of her since that date. Rindfleisch is the only observer so far who has definitely said that Hohmann is a true hermaphrodite; but obviously proof is lacking until the so-called ovary has been examined microscopically.

It will be seen from a perusal of the cases that we have collected that the number of proved examples of true hermaphroditism is very small. Of the true unilateral variety, the case which is the subject of this

paper appears to be the only one recorded up to the present time.

Of true bilateral hermaphroditism, Heppner's is the only case of the nine described which is at all likely to have been of this description, but, for the various reasons we have already mentioned, even this case cannot be accepted without cavil. The description and microscopic examination of two of the cases of true lateral hermaphroditism is sufficiently complete to enable us to accept them as proved instances of this condition, viz. those of Schmorl and Obolonsky; while it is probable that the cases of Meyer, Gruber, and Klotz are examples of the same kind.

We feel convinced, therefore, that true hermaphroditism can occur and has occurred in man, and we anticipate with confidence that cases of all three varieties will be recorded in the future.

Authors referred to.

1. *Ahlfeld.* 'Die Missbildungen des Menschen,' 1880.

2. *Arigo e Fiorani.* 'Annali Universali di Med.,' vol. ccxlvii, 1879.

3. *Banon (A. P.).* 'Dublin Quart. Journ. of Medical Sciences,' vol. xiv, 1852, p. 66.

4. *Barkow.* 'Anatomische Abhandlungen,' Breslau, 1851, S. 60.

5. *Beclard.* 'Bulletin de la Facul. de Méd.,' 1815, No. 2.

6. *Berthold.* 'Abhandl. der König. Gesellsch. der Wissensch. zu Göttingen,' Bd. ii, 1845, S. 104.

7. *Blackman.* 'Amer. Journ. of Med. Sciences,' vol. xxvi, July, 1853, p. 66.

8. *Brühl.* 'Ueber Hermaphrodismus,' Inaug. Dissert., Freiburg, 1894.

9. *Cramer.* 'Ein Fall von Hermaph. lateralis,' Inaug. Dissert., Zurich, 1857.

10. *Czarda.* 'Wiener medizinische Wochensch.,' 1876, S. 1075.

11. *Debierre.* 'L'Hermaphrodisme,' Paris, 1891.

12. *Durham.* 'Guy's Hosp. Rep.,' 3rd Series, vol. vi, 1860.

13. *Fowler.* ? Brühl, loc. cit.

14. *Von Franqué.* 'Scanzoni's Beiträge,' Bd. v, S. 57.

15. *Förster.* 'Die Missbildungen des Menschen,' Jena, 1865.

16. *Gast* (*P.*). 'Beitr. zur Lehre von der Bauch, Blasen, Genitalspalte, und von dem Hermaphrodit verus,' Inaug. Dissert., Berlin, 1885, Greifswald.

17. *Gruber.* 'Mémoires de l'Acad. Imper. des Sciences de St. Pétersburg,' 1859, tom. i.

18. *Heppner.* 'Reichert's Archives,' 1870, S. 679.

19. *Klebs.* 'Handbuch der path. Anat.,' Bd. i.

20. *Klotz.* 'Archiv für klin. Chir.,' Bd. xxiv, S. 454.

21. *Laurent.* 'Les Bisexués, gynécomastes, et hermaphrodites,' Paris, 1894.

22. *Lilienfeld.* 'Beitr. zur Morphol. und Entwickel. geschich. der Geschlechtsorgane,' Inaug. Diss., Marburg, 1856.

23. *Maret.* 'Mémoires de l'Acad. de Dijon,' tom. ii, S. 157, 1767.

24. *Mayer.* Casper's 'Wochensch. für Heilkunde,' 1835, No. 50.

25. *Messner.* "Hermaphrodismus verus," 'Virchow's Archiv,' Bd. cxxix.

26. *Meyer.* 'Virchow's Archiv,' Bd. xi, S. 420.

27. *Mundé.* 'Amer. Journ. Obstetrics,' vol. viii, 1875–6, p. 615.

28. *Obolonsky.* "Beiträge zur patholog. Anat. des Hermaphrod. hominis," 'Zeitschrift für Heilkunde,' ix, 1888.

29. *Odin.* 'Lyon Médicale,' t. xvi, 1874, p. 214.

30. *Rudolphi.* 'Abhandlung der Akad. der Wissensch. zu Berlin,' 1825, S. 45.

31. *Schmorl.* "Ein Fall von Hermaphrodit.," 'Virchow's Archiv,' Bd. cxiii.

32. *Schrell.* 'Med.-chir. pract. Archiv von Schenk,' i, 1804.

33. *Schultze.* 'Virchow's Archiv,' 1868, Bd. xliii, S. 329.

34. *Simpson.* 'The Works of Sir J. Y. Simpson,' vol. ii, Hermaphroditism.

35. *Stark.* 'Neues Archives für die Gebürtsh.,' Bd. ii, S. 544.

36. *Sue.* 'Arnaud's Mém. de Chirurgie,' pt. 1, 1768.

37. *Varole.* 'Pinel Mém. de la Soc. Méd. d'Émulation,' vol. iv, p. 342, Paris, 1801.

38. *Verdier.* ? Brühl, loc. cit.

39. *Vrolik.* Tab. ad illustr. 'Embryogen. Hom. et Mamm.,' Amsterdam, 1849.

Dr. HERMAN said that these cases were so rare, that there must be few Fellows of the Society competent to criticise Dr. Blacker's and Mr. Lawrence's paper. He wished to express his own high appreciation of the instruction derived from it, of the labour which the authors had put into it, of the ability of the reasoning, and the excellence of the microscopic sections.

The PRESIDENT said that Dr. Blacker's and Mr. Lawrence's paper was of a kind which, from its very nature, almost precluded discussion. Such papers, however, were of great value as scientific records in the Society's 'Transactions.'

True Unilateral

No.	Name and date.	Age.	Aspect.	Ext. genitalia.	Vagina.	Uterus.	Ovaries.	Fallopian tubes.
16	Gast, 1884	Fœtus mal-formed	?	?	Vagina represented by solid band of tissue uniting two halves of uterus	Uterus didelphys	Ovary on left side	Both f. ts. present, with well-marked fimbriated ends
22	Lilienfeld, 1856	22 years	?	?	?	Uterus bicornis	Small body attached to left broad lig. and f. t. called ovary	Left f. t. normal; right uterine horn prolonged into tube-like body with no definite fimbriæ
	Blacker and Lawrence	8½ months fœtus	?	Small penis-like organ with hypo-spadias; folds like labia majora; urogenital sinus	Vagina 8 mm. long	Uterus uni-cornis; body rudimentary; cervix well developed	Normal ovary on right side	Right f. t. normal; left present, but rudimentary

True Bilatera

32	Schrell, 1804	9 months	?	Hypospadiac penis with vulvar aper-ture below	Vagina present	Uterus imperfect	Both ovaries present	Both f. ts. present
5	Béclard, 1815	—	Dried speci-men and wax model	Vulva and clitoris	Vagina	Uterus	2 ovaries	?
7	Blackman, 1853	30 years	Man-like	Penis and empty scrotum	Vagina	Uterus	2 ovaries	2 f. ts.
39	Vrolik, 1849	58 years	Copious beard ap-peared at 17; dressed as female up to 38, after that as male	Imperforate penis; sinus urogenitalis	Vagina	Uterus	2 ovaries	2 rudimentary f. ts. passing through inguinal regions to tunicæ vaginales
13	Fowler, date?	?	?	Penis	?	?	2 ovaries	?

rmaphroditism.

aments.	Par-ovarium.	Prostate.	Testes.	Vasa deferentia.	Vesiculæ seminales.	Microscopic examination.	Remarks.
?	?	?	Small body called testis lying close to kidney on left side	None	?	Ovary showed ova and Graafian follicles in fibrous stroma; testis, cellular stroma containing tubules filled with round and polygonal cells	Specimen had been preserved in spirit for one year. No trace of any genital gland upon the right side of the body.
nd ligs. ll deve- l; broad s. mal- reloped	Par-ovarium said to be present on left side	?	Right testis well formed, with epi-didymis and vas. def. lying close to right int. abd. ring	Present on both sides	Ves. sem. well developed	Ovary said to contain no ova, but no definite mention of a micro-scopic exam.	—
ht side l, round, ovarian, normal; ft side ad and nd ligs.	Present on right side	Absent	Ovo testis on left side	Vas. def. and epididymis left side	Absent	Rt. gland showed cell columns, cell-nests, and Graafian follicles with relatively exces-sive stroma. Left gland in part exhibits similar structure; the rest is made up of abundant stroma, with definite tubules filled with cells, and forming at the hilum a rete-like structure.	—

maphroditism.

?	?	Internal male organs said to be present normally				None	—
?	?	?	2 testes present	2 vas. def. opening into cornua of uterus	?	None	—
?	?	Prostate present	2 testes	2 vas. def.	?	None	Monthly flow of blood occurred from urethra with much suffering.
?	?	None	2 testes present	Right vas. def. opened into vagina; left into left cornu of uterus	None	Examination of right ovary showed no Graafian follicles; right testis contained fibrous septa, no tubuli seminiferi.	—
?	?	?	2 testes	?	?	None	Original description not traceable. Menstruation and micturition through penis.

No.	Name and date.	Age.	Aspect.	Ext. genitalia.	Vagina.	Uterus.	Ovaries.	Fallopian tubes.
18	Heppner, 1870	2 months	?	Imperforate penis-like organ; sinus urogenitalis	Vagina 2 cm. long	Uterus fœtalis	2 ovaries present	2 tubes well developed
12	Durham, 1860	25 years	Female mammæ large	Hypospadiac penis	?	?	Body lying above testis on either side called ovary	?
29	Odin, 1874	64 years	Masculine; very little hair on face	Hypospadiac penis, bifid scrotum	Vagina 8 cm. long	Uterine body rudimentary	Right and left ovaries in mass of tissue at int. abd. ring	2 f. ts. imperforate, but wit well-marked fimbriæ
2	Arigo e Fiorani, 1879	68 years	?	Imperforate penis; sinus urogenitalis	Vagina present	Virgin uterus	2 ovaries present	2 f. ts.
								True Latera
36	Sue, 1746	13—14 years	Masculine aspect	Those of hypospadiac male; sinus urogenitalis	Present	Present	Left ovary	Left f. t.
23	Maret, 1767	17 years	Feminine, no beard, large mammæ	Imperforate penis 4″ long, fissure at root bounded by 2 folds like labia; left contained small body	A cul-de-sac 1″ in length, possibly representing vagina	Small body with cavity contained in cystic tumour, lying in right iliac fossa	Right ovary close to fimbriated end of tube	Right f. . present
37	Varole, 1754	18 years	Mammæ well developed	Hypospadiac penis; right half of scrotum contained small body, left half empty	?	Small uterine body on left side; no cervix	Left ovary present	Left f. t.
30	Rudolphi, 1825	7 weeks	?	Hypospadiac penis with sinus urogenitalis; right half of scrotum containing testis, left half empty	No definite vagina	Uterus terminated below in wall of prostate	Left ovary present	Left f. t.
35	Stark, 1835. Carl Durge or Maria Duriée	55 years	Head and face like that of old woman, slight beard	Imperforate penis with sinus urogenitalis	Vagina 2¼″ long	Uterus 2¼″ long	Ovary outside and behind left f. t.	2 f. ts. openi into uterus, closed at abdominal ends, but wit well-marke fimbriæ

aments.	Par-ovarium.	Prostate.	Testes.	Vasa deferentia.	Vesiculæ seminales.	Microscopic examination.	Remarks.
›ad and ›nd ligs. ormal	Present on both sides	Present, surrounding vagina and urethra	2 testes placed close to ovaries	None	None	Ovaries showed bodies like Graafian follicles apparently containing ova; testis showed tubules with walls of hyaline structure, some lined with granular cells, others filled with yellow débris.	—
?	?	?	Testes in small scrotum	Vasa def. and epididymes normal	?	None. Naked-eye examination: 2 ovaries composed of fat and fibrous tissue	—
?	Rudimentary on either side	Absent	Both testes present, with voluminous epididymes	Right vas def. could be traced to ves. sem., but not left	Present in usual position	No Graafian follicles found in ovary	—
?	?	?	2 atrophied testes in bifid scrotum	?	?	None	—
·maphroditism.							
t round lig.	?	?	Right testis close to int. abd. ring	2 tubes, finally uniting into one, passed from testis to right angle of uterus	?	None	—
?	?	?	Testis on left side, well formed, with spermatic vessels	Vas def. on both sides	Ves. sem. on both sides, right shrivelled	None	—
t broad l round ligs.	?	?	Testis in right half of scrotum	Right vas def. opening into ves. sem.	Right ves. sem. said to communicate with uterus	None	—
t broad l round s. malreloped	?	Rudimentary	Right testis with epididymis in scrotum	Right vas def. opening into sinus urogenitalis after piercing prostate	Absent	None	—
?	?	?	Testis near end of right f. t.	?	?	None. On naked-eye exam. ovary presented; granular parenchyma with separate glomeruli. Testis: yellowish-white appearance, with seminiferous tubules	Had discharge of blood from genital organs on one occasion after an injury.

No.	Name and date.	Age.	Aspect.	Ext. genitalia.	Vagina.	Uterus.	Ovaries.	Fallopi tube
4	Barkow, 1851	54 years	Masculine	Imperforate penis; right half of scrotum contained two bodies, left half empty	?	Hernia of uterus in right half of scrotum	Ovary present, side doubtful	No trac f. ta
6	Berthold, 1845	Full term child	?	Imperforate penis, urogenital cleft	Vagina present	Uterus unicornis, with left appendages	Left ovary present	Left f. prese
3	Banon, 1852	26 years	Masculine	Imperforate penis, sinus urogenitalis, and divided scrotum	Vagina present	Uterus normal, but no appendages on right side	Left ovary present in recto-vaginal space	Left f. permea with fimb end
17	Gruber, 1859	22 years	?	Imperforate penis; sinus urogenitalis	Vagina 8 cm. long	Uterus 8 cm. long	Carcinomatous tumour on left side in position of ovary	Left tu norm
20	Klotz, 1880	24 years	Intermediate between male and female; mammæ large	Imperforate penis, sinus urogenitalis, divided scrotum, fistulous opening in right half	Vagina present	Uterus unicornis	Cystic body in right half of scrotum described as ovarian cyst	F. t. on side ope into c
25	Messner, 1892	31 years	Feminine, no beard or moustache, mammæ large	Hypospadiac penis 6 cm. long; opening of urethra 3 cm. from end	No evidence of vagina	No trace	Small body right side of pelvis, size and shape of ovary, on palpation	?
28	Obolonsky, 1888	?	?	Hypertrophied organ like clitoris, with folds of skin representing labia majora and minora, sinus urogenitalis	Vagina 6·5 cm. long present, with hymen-like fold at entrance	Uterus bicornis, left horn 6·5 cm. long, right horn quite rudimentary	Ovary present on left side, 3 cm. × 1·5 cm.	F. ts. on side

ments.	Par-ovarium.	Prostate.	Testes.	Vasa deferentia.	Vesiculæ seminales.	Microscopic examination.	Remarks.
ian lig. ched to dle of vary	?	Present	Testis with epididymis present, side doubtful	Vas. def. absent	Ves. sem. absent	None. Testis, on section, showed light yellowish brown parenchyma, with fine thread-like canals; ovary consisted of connective tissue, fat, and vessels	Specimen not fresh, and spoilt during removal.
nd and ligs. in t side	Par-ovarium left side	None	Testis with epididymis in right half of scrotum	Right vas def. passing through wall of uterus and opening into sinus urogenitalis	None	Testis showed normal structure. Ovary showed none of microscopical characters, although normal to naked eye	—
?	?	None	Right testis lying in recto-vaginal space with large epididymis	Right vas def. opening into uterine cavity at lower part	None	Testis said to present normal structure. No spermatozoa. Drawing of microscopical section of ovary shows fibrous stroma with granular contents, but no Graafian follicles.	—
broad, ian, and nd ligs. al; right ad lig. eveloped	Present on left side	Well developed round urethra	Testis close to right ext. abd. ring, with epididymis in inguinal canal	Right side vas def. not traceable beyond int. abd. ring	?	Tumour showed structure of glandular carcinoma. Testis had fibrous septa and seminiferous canals	—
?	?	?	Testis in left half of scrotum with epididymis	Left vas def. terminating in sinus urogenitalis	Slight indication of ves. sem. at urethral end of vas	Left gland showed typical structure of testis. The cystic swelling was made up of thin-walled spaces filled with yellow fluid. The more solid portions consisted of a fibrous stroma, with cavities, showing all transitions from solid strands of cells to gland-like spaces lined with cubical, flattened, and ciliated epithelium	Had monthly attacks of pain. In 18th year discharge of blood commenced from urethra and from fistulous opening recurring monthly.
?	?	Felt normal	Right testis at ext. abd. ring; body in left inguinal canal, possibly left testis	?	?	None	Monthly hæmorrhages from urethra began at 21 years of age, and continued for 10 years, lasting 3—4 days, with great deal of pain.
bad and nd ligs. th sides	?	Prostate present	Testis 2 cm. × 1·5 cm. on right side, with remains of epididymis	Right vas def. present, cut short	?	Ovary showed fibrous stroma, with cell-nests containing clear cells like ova. Testis fibrous stroma, with mediastinum and tubules filled with round cells	Specimen had been 20 years in spirit.

No.	Name and date.	Age.	Aspect.	Ext. genitalia.	Vagina.	Uterus.	Ovaries.	Fallo tub
10	Czarda, 1876	Immature child	45 cm. long	Imperforate penis with large glans, sinus urogenitalis	?	?	?	?
33	Verdier, date ?	?	?	Penis with opening of vagina below	?	?	Ovary on left side	Left f
31	Schmorl, 1888	22 years	Masculine, voice high tenor	Hypospadiac penis with rudimentary scrotum	Vagina opening into urethra at site of colliculus seminalis	Uterus bicornis	Ovary left side cut in half at operation	Right imperf except a left with marked
26	Meyer, 1857	New-born child	Masculine	Hypospadiac penis; sinus urogenitalis	Small vagina	Small uterus	Right side an ovary	Both f prese
33 27	Schultze, 1868. Mundé, 1876. Catherine Hoffman	Born 1824	Masculine, but mammæ well developed, and hair like woman's	Hypospadiac organ, 5½″ long when erect; right side scrotum containing body, left side mass of fatty tissue; urogenital sinus	No trace of vaginal pouch	Doubtful uterus	Body felt in left side of pelvis called ovary; connected with ? uterus by cord	?

*** The numbers refer to bibliography.

ıments.	Par-ovarium.	Prostate.	Testes.	Vasa deferentia.	Vesiculæ seminales.	Microscopic examination.	Remarks.
?	?	?	? Testis in bifid scrotum	?	?	?	Called by Czarda true hermaphrodite because of resemblance of ext. genitalia to arrangement usually met with in true hermaphrodites.
?	?	?	Testis on right side	Right vas def. present	? Right ves. sem.	?	Original description not traceable.
ht side ıd ligs.	Tubules like par-ovarium on right side	?	Body in right half of scrotum with rudimentary epididymis called testis	No trace of vas. def.	None	Testis showed tunica albuginea, with fibrous trabeculæ and fine tubules. No spermatozoa. Ovary, cellular stroma, and follicles, but no ova.	—
ht and broad round igs.	Par-ovarium on either side	Small prostate present	Testis in left scrotal sac in processus vaginalis	Left side tube like vas def.; no definite lumen except for 30 mm. towards uterus	None	Klebs found so-called ovary to consist of fibrous stroma tunnelled by branching and anastomosing canals filled with polygonal cells	—
?	?	Absent	Right testis in scrotum, ? left testis in inguinal canal	?	None	Spermatozoa found in fluid emitted in 1863	Lived as woman until 46 years of age; after that as man. Seminal emissions in 15th year. Pseudo-menstruation ? from 19th to 43rd year.

OCTOBER 7TH, 1896.

F. H. CHAMPNEYS, M.A., M.D., President, in the Chair.

Present—41 Fellows and 3 visitors.

Books were presented by the Clinical Society, the American Association of Obstetricians and Gynecologists, the Johns Hopkins Hospital Staff, and Dr. Charles West.

Frank E. Easton, L.R.C.P.Lond., and W. Campbell McDonnell, L.R.C.P.Lond., were admitted Fellows of the Society.

Mark Sharman, M.B., C.M.Glas. (Rickmansworth), was declared admitted.

The following gentlemen were proposed for election :—Guthrie Rankin, M.D.Glas. ; and Sidney Arthur Mugford, L.R.C.P.

A TUBO-OVARIAN ABSCESS.

Shown by WALTER TATE, M.D.

(For Report see p. 380.)

A SUB-COMMITTEE was appointed to examine and report upon this specimen. It consisted of Mr. Bland Sutton, Dr. Roberts, and Dr. Tate.

FŒTUS PAPYRACEUS.

Shown by W. Rivers Pollock, M.D.

The specimen was obtained from a patient aged 20, who had had two pregnancies. The first confinement was a natural one, and a healthy child was born in September, 1894. With regard to the second child, the last period occurred in January, 1896. At 4.30 p.m. on September 24th a normal delivery again took place, and a large, full-term healthy child was born. The placenta and membranes came away without difficulty. Attached to them, however, and occupying a separate pocket in the membranes with a separate atrophied placenta, was discovered a fœtus papyraceus, about ten inches long, that appeared to be about five months old. The mother and child both did well.

Mr. Bland Sutton remarked that there was little chance of overlooking or mistaking the nature of a "papyraceous fœtus" when it had attained such proportions as in Dr. Pollock's specimen. He wished to show an example sent to him by a gentleman of large experience in midwifery "as a curious lump found in the membranes of a well-formed fœtus." A cursory examination was sufficient to demonstrate it to be a compressed fœtus of the third month attached to a similarly flattened placenta. A very small example was apt not only to be overlooked, but also to be misinterpreted, and even to be described as "a tumour of the amnion" (*vide* the Society's 'Transactions,' vol. xxix, 243, 512). A study of the compressed placenta attached to a papyraceous fœtus is of interest, inasmuch as it enables the histologist to demonstrate the atrophic changes which ensue when the fœtal circulation ceases, and also furnishes him with facts which assist him in determining the relative length of time that a placental fragment has been retained. Thus, in his (Mr. Sutton's) specimen, the fœtus was about three months old, and the changes exhibited by the placenta were the result of six months' retention in the uterus. Yet, in spite of the compression and atrophic changes to which the placenta has been subject, it is a matter of great simplicity to determine its placental

nature with the aid of the microscope, for the chorionic villi stand out with great distinctness among the surrounding connective tissue when viewed with a low power; but when examined with a high power the minute details are blurred and lost. Papyraceous fœtuses are commonly found in twin births; they have also been found in the membranes of triplets. A fœtus accompanied during its sojourn in the uterus by a papyraceous fœtus is of course a twin, yet there are many individuals born in these circumstances absolutely ignorant that they had twin brothers or twin sisters. As a matter of fact most of us would find it difficult to prove that we were not one of twins. (This is a question of some interest in relation to cases of transposition of viscera.)

The President thought that it would be unsafe to argue from changes in the placenta in a specimen like this, as to the changes which would be found in a piece of placenta in a case of imperfect abortion. The conditions were very different. Fœtus papyraceus was a very interesting thing, because it was very common in the vegetable kingdom. In a large number of fruits all the nutlets but one were stunted, and could be seen squeezed flat by the surviving nutlet, just as in fœtus papyraceus. Familar examples were seen in the cocoa-nut, where two flattened stunted nutlets were always to be seen on dividing the shell. The same occurred in the chestnut, and in many other fruits. Another analogy was furnished by what sometimes happened in a bird's nest. A brood of birds were hatched, one of them was often feebler than the others, was pressed aside by them at feeding-time, died, and was squeezed flat against the nest. He had presented one such specimen to the museum of St. Bartholomew's Hospital, in which a little body like a finger-nail really was the entire body of a young canary. It had been pointed out that the uterus was strictly analogous to the nest, the bird laying her eggs into the nest, the mammal into the uterus.

AN UNREPORTED CASE OF PRIMARY CANCER OF THE FALLOPIAN TUBES IN 1847, WITH NOTES ON PRIMARY TUBAL CANCER.

By Alban Doran, F.R.C.S.,

SURGEON TO THE SAMARITAN FREE HOSPITAL.

(*Abstract.*)

In a MS. atlas of pathological drawings recently presented to the library of the College of Surgeons by Dr. Renaud of Manchester, is a drawing of a case of cancer of the tubes and ovaries, dated November, 1847. The uterus was free, it appears, from malignant disease. The further history has been lost. The drawing represents the disease as far advanced in one tube, whilst the ovaries remain small. This is the condition found in primary cancer of the tubes described within the last ten years. Mr. Doran notes a source of fallacy. The large tube may be a hydrosalpinx into which cancer has extended from a relatively small ovary, as in Winter and Fabricius's cases. Orthmann has published a useful summary of cases of cancer of the tube related by the older writers of this century. Many observers, instead of analysing each case on its merits, seem to have worked with the fixed idea that cancer of the tube must always be secondary. Recent investigations by Orthmann, the author, and others tend to prove that primary cancer is more frequent in the tube than is commonly supposed.

In the course of some investigations on tubal cancer, the result of which is published in Drs. Allbutt and Playfair's 'System of Gynæcology,' my attention was turned by Dr. Cullingworth to an unrecorded case of singular interest.

Dr. Renaud, now consulting physician to the Manchester Royal Infirmary, recently presented to the library of the

Royal College of Surgeons of England a fine MS. atlas of pathological drawings in two volumes. The author's painstaking observations extend from 1837 to 1888, or over half a century. Some of the drawings were used for an instructive article in the 'Journal of Medical Science' in 1845.* The greater part of the atlas, including the original of the sketch now exhibited, remains unpublished.† The writing under the original sketch is "*Vide* Case 21, p. 124: medullary cancer of right and left oviducts, also of right and left ovaries, uterus free from all ordinary evidences of malignant disease. Case, Mary Rigby, November 16th, 1847; F(rank) R(enaud)."

In reply to inquiries last summer (1896), Dr. Renaud informed me that the case was possibly recorded in the 'London Medical Gazette' about 1847, amongst brief reports of the Manchester Pathological Society. We have both looked through several volumes of the 'Gazette,' and failed to find the desired information. There are several notes on uterine cancer in 1846–8, one of considerable length. The specimen was probably exhibited at the Society, but not reported in the 'Gazette.' Dr. Renaud remembers nothing further about the case, nor can he explain the meaning of "Case 21, p. 124." It refers to some lost MSS., and not to the newspaper above mentioned.

The first undoubtedly genuine case of primary cancer of the tube was published by Orthmann in 1888.‡ His report includes an instructive summary of cases of cancer of the tube described by older writers. Sänger and Barth,§ referring to this summary, justly remark that the accuracy of many of the older writers is problematical.

* "The Human Female Ovary with reference to Corpora Lutea, both True and False," 'London and Edinburgh Monthly Journal of Medical Science,' vol. v (1845), p. 589.

† I must thank Dr. Renaud and the President and Librarian of the College of Surgeons for permission to make this copy.

‡ "Ueber Carcinoma Tubæ," 'Zeitschrift für Geburtshülfe,' vol. xv, p. 212.

§ Martin's 'Krankheiten der Eileiter,' art. "Neubildungen," p. 252.

Renaud's case, for reasons which I have made clear, escaped the notice of Orthmann, Sänger, and Barth. I agree with the opinion of the latter writers just quoted; I may point out, however, that I have examined Dr. Renaud's drawing, and am also among the few who have had an opportunity of examining thoroughly a case of primary cancer of the tube. Let it be observed that in Renaud's drawing, which gives every indication of artistic ability, the right tube is clearly dilated and filled with new growth, displayed by an orifice cut in the tubal wall. The ovaries are quite small, and almost hidden by the enlarged tubes, and Renaud reports them as cancerous. This relative proportion of tube and ovary is precisely what is seen in primary tubal cancer. We see a big tube or tubes filled with new growth, and a small ovary or ovaries healthy or becoming cancerous. In the second case ever published of primary tubal cancer, where the patient was observed so closely by Dr. Amand Routh and myself, this condition was well marked.*

On the other hand, in primary cancer of the ovary infecting the tube we see a large ovary with a small tube. The walls of the tube show deposit growing from without inwards, and its canal may be normal without dilatation. Sänger and Barth figure† a typical case of this kind.

Thus the way to distinguish primary cancer of the tube is seldom difficult. A source of fallacy exists when a hydrosalpinx lies on a cancerous ovary. A few patches of malignant growth inside the tube in such a case must not mislead the observer; Klob was not deceived by this condition. Fabricius recently reported a typical case. The patient was forty; a free bloody discharge had existed for several months. This symptom is observed in primary tubal cancer. There was a small cystic cancerous tumour of the ovary, and a large hydrosalpinx which contained masses of cancerous substance floating free in its lumen.

* 'Trans. Obstet. Soc.,' vol. xxx, 1888, p. 194, 'Trans. Path. Soc.,' vol. xxxix, p. 208; vol. xl, p. 221.

† Loc. cit., fig. 53, p. 275.

CANCER OF TUBES.

(After a drawing of Dr. RENAUD'S, 1847).

This substance had entered the tube through a perforation communicating with the diseased ovary. Judging from the drawings and report in the original paper, there seemed to be no evidence of cancer of the tube itself.* Winter describes a similar case.† A hydrosalpinx lay in contact with a cancerous ovary, and a pedunculated cancerous mass projected into the cavity of the tube.

I am inclined to agree with Orthmann in believing that some of the older observers did actually detect primary tubal disease, though the cases which he quotes are of little value in the absence of microscopical reports, and most of them seem rather instances of extension of cancer from the uterus. Since Orthmann wrote his report some twenty cases of primary cancer of the tube have been published, and the appearances of the disease are now no longer unfamiliar. Thus Schröder and others erred in asserting that malignant disease in the tube was never primary. Such assertions are certain to lead to error. Let it be understood that we must examine a specimen of tumour of the tube with the sole intent of getting at the truth, and not to prove that it cannot be primary or cannot be secondary. The fact remains, however, that primary disease is not unknown. The subject demands, I admit, much further investigation. I believe that in not a few cases of malignant pelvic growths, too advanced for operation or for precise pathological definition, the disease began in the tube. I refer especially to cases where the growth, though advanced, hardly rises out of the pelvis, and the uterus is free. In primary ovarian cancer the tumour usually rises high in the abdomen.

Dr. CULLINGWORTH explained the circumstances under which he had learnt of the collection of artistic treasures which Dr. Renaud had entrusted to the keeping of the Royal College of Surgeons, and expressed his personal gratification that Mr. Doran had decided to bring them under the notice of the pro-

* "Perforation eines malignem Ovarialtumor in die Tube," 'Wiener klin. Wochenschrift,' vol. ix, 1896, pp. 59 and 74.

† 'Centralblatt f. Gynäkologie,' 1887, p. 497.

fession. He was glad that the Council of the Society had seen its way to sanction the reproduction of the beautiful drawing which formed the subject of the present communication, and he thanked Mr. Doran for having shown so earnest a desire to give credit to an early and overlooked observer in the department of tubal pathology.

A CASE OF DOUBLE UTERUS WITH DOUBLE HÆMATOMETRA AND COMPLETE ABSENCE OF THE VAGINA.

By Arthur H. N. Lewers, M.D.Lond.,
OBSTETRIC PHYSICIAN TO THE LONDON HOSPITAL.

(*Abstract.*)

The author relates a case of a girl æt. 17, who had never menstruated. She was led to seek advice on account of severe pain in the hypogastric region and the lower part of the back. In November, 1893, careful examination under anæsthesia showed that the vagina was imperforate, and *per rectum* that there was a uterus, perhaps a little larger than normal in a virgin of seventeen, but not much larger. There being no positive evidence of distension, it was decided to watch the case. The patient was kept under observation for more than two years. Ultimately examination showed that the uterus was definitely enlarged, and it was then decided to operate. Full details of the operation, performed on January 2nd, 1896, appear in the paper. There was *complete* absence of the vagina. There was a double uterus, each half of which was distended by retained menstrual fluid. The subsequent progress of the case was satisfactory. The patient was seen in September, 1896. She had menstruated regularly, and was quite free from pain. The only difficulty was to keep the vagina open. The small ring pessary she was wearing was found, after being in three months, to some extent incarcerated by granulation tissue, and an anæsthetic had to be given in order to remove it. It seems likely that by changing the pessary rather more frequently than usual, perhaps once a month instead of once in three months, this difficulty may be avoided in future.

The question of a preliminary abdominal section in dealing with such cases is discussed in the paper, and, though it was

not done in the present case, it appears to the author on the whole to be the right course to adopt.

L. T—, a single girl aged 17, was first seen by me on November 26th, 1893, at Reading, at the request of my friend Dr. Arthur Roberts, of Reading, who was attending her. On that occasion a very careful examination was made, the patient being under the influence of an anæsthetic administered by Dr. Rows, of Reading. The condition of things discovered at that examination is described below.

Family history.—Her father is alive and well. Her mother died during the patient's infancy. She has no sisters or brothers, but she has half-sisters and half-brothers.

Personal history.—She is seventeen, and will be eighteen on the 24th of May next. She has lived all her life at Southampton, and has had no illness of any kind before the present trouble began.

Special history.—She has never "seen anything" at all, but for some time past (the time when the pain began was not given very accurately) she has complained of great pain in the hypogastric region and back, which comes on about once a month, and lasts about fourteen days. Severe pain is practically her only symptom.

At the examination on November 26th, 1893, the following facts were noted:—the patient is a tall, well-developed girl; the breasts are well developed. On examining the abdomen no swelling could be felt in the hypogastric region, nor was there any swelling to be felt there at any time subsequently, though she was examined on many occasions extending over a period of more than two years, during which she was kept under observation before the operation.

Vulva.—When the labia are not separated the appearance of the external genitals is quite normal; the mons Veneris, labia majora, and pubic hair present their normal appearance. On separating the labia majora, the nymphæ,

glans clitoridis, vestibule, urethral orifice, fourchette, and fossa navicularis are normal, but where the vaginal orifice should be the condition is as follows. There is a slightly raised median ridge running from before back from the posterior margin of the urethral orifice to where the posterior margin of the vaginal orifice should be. On each side of the raphe described there is a slight depression of the surface, to the extent of $\frac{1}{32}$ of an inch or so, and round each of these depressions there is a distinct but rather rudimentary hymen. That is to say, where the vaginal orifice should be there is a central antero-posterior ridge, with a very shallow depression surrounded by a rudimentary hymen on each side of it.

On rectal examination a uterus can be felt bimanually; it is in the normal position and fairly moveable. As regards its size, the uterus appears to be rather larger than the uterus of a virgin aged seventeen, but not very much larger. Certainly it is not so much enlarged as to lead one to feel sure there is any accumulation of menstrual fluid inside it. With the sound in the bladder and the finger in the rectum, the partition between the rectum and the bladder is felt to be very thin, and especially so in the neighbourhood of the cervix. A dimple is felt at the end of the cervix, which is taken to be the external os uteri; it points backwards and somewhat to the right. The distance from the anus to the position of the os was measured as carefully as possible with the finger, and found to be about 2 inches. This is of interest in the light of what occurred at the operation, as the dissection had to be carried about 3½ inches or more from the surface before the dimple in question was reached. As regards the opinion of the case arrived at on this occasion, I came to the conclusion that there was no vagina, but that, on the other hand, there was no evidence on physical examination of distension of the uterus. As the patient only complained of pain, it did not seem to me at that time that making an artificial passage to the os uteri would necessarily relieve it, as the pain did not seem to depend on distension

of the uterus. I therefore advised postponing the question of any operation till there was definite evidence of accumulation in the uterus. The patient was given ichthyol in pills for some time, and it seemed for a while to relieve her. I should say that I took her into the London Hospital on January 12th, 1894, and kept her in till March 2nd, 1894. During that time there was no rise of temperature; the only symptoms were the pain described and headache. There were intervals when she was free from any discomfort.

Examination during her stay in the hospital confirmed the results already found when she was examined at Reading.

I saw her at intervals during 1894 and 1895. Sometimes she was free from pain for long periods, while at other times the pain was very severe. She was re-admitted into the London Hospital on October 31st, 1895. The attacks of pain had been irregular in their occurrence, and not every month. For instance, the last onset of pain was six weeks before her re-admission, and it continued up to her admission. The pain is often worse at night. The pain is said to be rather to the left side of the hypogastric region, and to extend down the left leg as far as the knee, as well as being felt in the lower part of the back.

November 14th, 1895.—An anæsthetic was given, and she was again thoroughly examined. There was no swelling to be felt in the lower part of the abdomen even when she was deeply under the influence of the anæsthetic. On bimanual examination *per rectum* the uterus was felt to be distinctly enlarged, and about the size of the pregnant uterus at the eighth week. There was a swelling to the left of the uterus, which could not, however, be separated from the uterus, and it seemed like an enlargement of the uterus in that direction.

I felt sure now that the uterus was distended, and accordingly decided to operate. Extensive alterations were being made in the ward at the time, causing a great

deal of noise, so that the operation was postponed till January 2nd, 1896. In the meantime the patient was often in great pain, and hypodermic injections of morphine were frequently needed.

As to the nature of the proposed operation, the question as to whether a preliminary abdominal section should be undertaken, as has often been suggested (quite recently again by Dr. J. C. Webster, in an article on "Atresia of the Vagina," in the 'American Journal of Obstetrics' for October, 1895), was carefully considered. It is well known that dilated Fallopian tubes not rarely complicate cases of hæmatometra. As I had carefully watched the case for two years, and seen the patient both when the uterus was little if at all distended, and again when the uterus was clearly enlarged, it seemed to me that most probably in this instance the Fallopian tubes were not dilated. I therefore decided to attempt to make an artificial passage up to the uterus without any preliminary abdominal operation.

Operation (January 2nd, 1896).—The patient was anæsthetised with the A.C.E. mixture, and placed in the lithotomy position. The parts having been thoroughly sponged with corrosive sublimate lotion (1 in 1000), a transverse incision about 2½ inches long was made in the perinæum just behind the fourchette. A sound was held in the bladder, and the left forefinger frequently introduced into the rectum during the operation. The wound was gradually deepened, partly by tearing, but principally with the knife and scissors. The sides of the wound were held apart by strong retractors right and left. The point aimed at was the dimple felt on examining *per rectum*. The dissection had to be carried much further from the surface than had been anticipated; and its depth was ultimately at least 3½ inches. The strong traction on each side of the wound had gradually torn the perinæum back to the very margin of the anus, and a few fibres of the sphincter ani were torn. The cavity produced by the dissection was of a capacity to allow

of its containing the fist. It was at length possible to recognise that the immediate neighbourhood of the uterus had been reached, a part uncovered by bladder. There was no trace of any pre-existing cavity—an interesting point, because in cases of atresia of the vagina the atresia is often confined to the lower part of the vagina—the lower third or half, for instance. When the obstruction has been opened up to that extent a normal vagina is found above. There was nothing of the kind in the present case, nor was there any trace of the normal smooth covering of the vaginal portion. The part of the uterus corresponding to the vaginal portion, as regards its aspect towards the vagina, merely presented the raw surface made by the dissection. As the dissection proceeded it had gradually come to my knowledge that there was something in the nature of a second dimple felt to the right of the one that had been recognised before the operation.

When the amount of tissue over the principal dimple, that to the left (of the patient), was felt to be very little, a pair of Wells's small pressure forceps was thrust into it, evidently at once entering a cavity; the usual dark treacly fluid met with in cases of retained menses at once began to escape. The opening was enlarged by separating the blades of the forceps till the finger could be passed into the cavity. This was felt to be slightly loculated at one place, and to extend some distance to the left side.

Towards the middle line this cavity presented a vertical partition, towards the left its wall was concave. The dimple to the right side was now localised as well as possible, and a pair of Wells's forceps similarly thrust into it. It entered a larger cavity than that on the left side, and the puncture was followed by a fresh escape of retained fluid. The opening was enlarged with the forceps, and the finger passed into this right cavity. This cavity seemed to have been about the size of a duck's egg. Each cavity was now washed out with hot iodine water, a strip of iodoform gauze was packed loosely into it, an inch or so being left hanging from each os uteri

into the vagina. The wound (vagina) was now packed with iodoform gauze. Two stitches were put in to unite the tissues for a quarter of an inch in front of the anus, and the patient was put back to bed.

Subsequent progress.—The patient went on very comfortably from January 2nd, the date of the operation, till January 13th, having little or no pain, and no rise of temperature. The gauze was still in; a little of the lower end of the part used to plug the vagina had been cut away on two occasions.

On January 15th the temperature rose for the first time since the operation, reaching 101°. The gauze was removed from the vagina, and also the two strips from the two compartments of the uterus. A good deal of pus followed the removal of the vaginal plug, and some also the removal of each uterine plug.

On the 16th the temperature was still up (102°). As the patient was extremely tender, an anæsthetic was given in order to wash out the two uterine cavities thoroughly. This was done with iodine water. The finger was passed into each os uteri. Each uterine cavity was mopped out with pure tincture of iodine, the excess being washed away, and iodoform was introduced with a Recamier's curette freely into each cavity; a good deal of iodoform was also left in the vagina, but no plug of gauze was used on this occasion.

The rest of the patient's progress was uneventful. The cavity contracted rapidly, but was kept from becoming too small by passing No. 26 of Hegar's bougies daily. A pewter ring was modelled to fit the vagina, and the patient left the hospital on February 22nd. Examination before she went out showed that the uterus had become very much smaller than it was found to be any time before the operation. When examined with a Sims's speculum, the two apertures leading to the uterine cavities could be seen about half an inch apart at the top of the vagina. The vagina was about two inches deep from the surface. Some of its surface was still granulat-

ing, but over a good deal of the lowest part the epithelium had spread in. The patient had complete control over the bladder and rectum. She was seen again a week afterwards, and a small ring pessary, $1\frac{5}{8}$ inches in diameter, was put in instead of the pewter pessary.

Dr. G. H. Cowen was resident accoucheur when the patient was in the hospital on the second occasion. I am indebted to him for much careful attention to her after the operation, and also to Messrs. H. C. Dixon and F. Waldron, clinical clerks, for their notes of the case.

Remarks.—I have not been able to find a case on record of double uterus with *double* hæmatometra and *complete* absence of the vagina. In cases of complete absence of the vagina the uterus is generally rudimentary or absent. I have seen such a case in my own practice. In that case the uterus was rudimentary, and the vagina absent. As there were no signs of retention, and no symptoms, nothing was done. The case is fully recorded elsewhere.[1] I think the most important question arising in cases such as that described in the present paper is, first, as to what are the indications for operation; and, second, as to what operation should be performed.

As regards the first question, i. e. the propriety of any operation, it seems to me that, in the absence of symptoms, nothing should be done; and that even in the presence of a good deal of pain it is better to wait till there is physical evidence of retention before proceeding to make an artificial passage to the uterus.

The rapidity with which in the present case a cavity, which at the time of the operation would contain the fist, contracted and shortened so that it would only contain a ring pessary $1\frac{5}{8}$ inches in diameter, would certainly tend to deter me from attempting to make an artificial vagina for the purposes of sexual intercourse alone.

As regards the second question, i. e. an operation of some kind being indicated by the presence of physical signs of retention, what should the operation be? Should

[1] Author's 'Text-book of the Diseases of Women,' 4th ed., p. 414.

it take the form of a preliminary abdominal section, with a view to ascertaining whether or not the Fallopian tubes are distended as well as the uterus? My own feeling would now be in favour of doing this in cases of hæmatometra, especially when the physical signs go to indicate the existence of some swelling or swellings outside the uterus. In the operation performed in the present case there was a good deal of manipulation in the way of pushing down the uterus from above, and pulling on it with a volsella. Had the Fallopian tubes been distended, I think that they would most probably have been ruptured.

There is a fatal case of hæmatometra in a single uterus, with absence of the vagina, by Dr. C. H. F. Routh (in vol. xii of the Obstetrical Society's 'Transactions,' p. 34), in which an artificial vagina was made, and the fluid liberated from the dilated uterus. The patient died of peritonitis, evidently caused, as shown at the post-mortem examination, by rupture of one of the Fallopian tubes, both of which were dilated. The rupture was most probably caused, and no doubt unavoidably, by the manipulation employed in making the new vagina. The dilated tubes might probably have been quite safely removed by a preliminary abdominal section, or at least might be so removed in a similar case at the present time. Dr. Routh's case occurred in 1869. The question of operating on cases of hæmatometra by puncture through the rectum was an alternative operation considered seriously at the time of Dr. Routh's case, but such a proceeding would probably have no supporters at the present day.

Dr. J. C. Webster has recently recorded two cases of atresia of the vagina with retained menstrual blood. In one, a case of atresia affecting the lower fourth of the vagina only, abdominal section was first performed, and the Fallopian tubes, one of which was dilated, were removed. The patient died of septic peritonitis some weeks after the operation. In the other case, Professor

Simpson first evacuated the fluid by making an artificial vagina, and subsequently did an abdominal section, removing a cystic mass, the exact relations of which could not be made out. In this case the patient did well. Dr. Webster is of opinion that abdominal section with removal of the tubes should precede any attempt to open up the atresic vagina. With this view I now myself agree in cases of hæmatometra where the vagina is practically absent, although the procedure recommended is not that adopted in my own case, which terminated very happily.

It will be observed that both sides of the double uterus were washed out with a double-channelled intra-uterine tube, both at the time of the operation and also a fortnight afterwards, when the temperature had gone up. I can see no objection at the present day to washing out the uterus, provided a double-channelled tube is the one employed.

In conclusion, I may summarise the points of interest in my case as follows :

1. The complete absence of the vagina with double uterus and double hæmatometra. I believe the case to be unique in respect of the double hæmatometra.

2. The entire absence throughout of any swelling that could be felt by abdominal examination alone, even when the patient was deeply anæsthetised.

3. The occurrence of long intervals in the earlier part of the case, during which the patient was free from pain. Whether this was due to the influence of the ichthyol she was taking it is impossible to say. Afterwards the pain was not affected by ichthyol, and could only be relieved by frequent hypodermic injections of morphine.

4. As regards the operation, there is very little information given in the text-books as to the best mode of proceeding. I found making a long transverse incision just behind the fourchette to be a convenient way of beginning the dissection. The wound was gradually deepened partly by tearing, but also with the knife and

scissors, the sides of the wound being strongly held apart by retractors.

5. The cavities from which the retained menstrual blood was evacuated were washed out, both at the time of the operation and subsequently when the temperature rose.

6. The rapid contraction of the cavity made at the operation—a well-marked feature in the case,—which would seem to point to the uselessness of making an artificial vagina apart from any signs of menstrual retention.

Dr. Amand Routh narrated a case of a girl aged twenty-one, an in-patient in the Samaritan Hospital, who had painful menstrual molimina with amenorrhœa. The vagina was entirely absent, and she had a hypogastric tumour which recto-abdominal examination proved to be an enlarged uterus. No distended tubes could be felt. He dealt with the case as Dr. Lewers had done, dissecting along the narrow septum between the urethra and bladder in front, and the rectum behind. When close to the cervix he could feel a double membrane covering it, which was probably the pouch of Douglas turned forwards, as no vagina was present. This was subsequently opened, and as the cervix was also imperforate, it was opened with a curved trocar and cannula. There was great difficulty in keeping the vagina patent, a long narrow Hodge becoming embedded; but finally a small speculum was found to answer best. The woman, however, was of weak intellect, and when she left the hospital allowed the vagina to close again, requiring the operation to be repeated. He had not seen her for six months. As regards the alternative operation, Dr. Routh did not think that there was any need to open the abdomen to decide whether a hæmatosalpinx was present, that being discoverable by recto-abdominal palpation; but he believed that if the vagina could not be kept patent, and menstruation without exit persisted, the proper treatment was to remove the appendages to arrest the function altogether.

Dr. Cullingworth said that he quite agreed with Dr. A. Routh in thinking that abdominal section might be a justifiable operation for other reasons than those alluded to by Dr. Lewers and the President, in certain cases of menstrual retention in which the vagina or a large part of it was absent. As Dr. Lewers's case showed, and as was proved by the experience of every one who had had similar cases to deal with, an artificial vagina was very difficult to keep open, and the accumulation was apt to recur. Where this happened, or where there was great danger

of its happening, it would, he thought, be good practice to remove the ovaries with a view to the arrest of menstruation. The subject had been brought under his notice recently in connection with the case of a young lady, in whom an accumulation of menstrual fluid in the upper part of an otherwise occluded vagina had been opened by a surgeon *per rectum* under the belief that it was an abscess. Septicæmia followed; the distended sac became an abscess cavity; each month the flame was fanned by the pouring out of more blood into the cavity, and its rapid decomposition; the pelvis became filled with a mass of inflammatory exudation and adherent viscera, and the question was raised as to the desirability of removing the ovaries. As he doubted very much whether in such a tangled and malformed mass he should be able to find the ovaries, he persistently declined to expose the patient in this particular case to the risk of the attempt. Nevertheless this experience had made him feel how well it would have been if the ovaries had been removed when the first indications of mischief had manifested themselves. Dr. Cullingworth was, of course, quite familiar with the directions laid down by Dr. Matthews Duncan for the safe evacuation of the retained fluid in ordinary cases of hæmatocolpos, and quite recognised that they were founded on the ghastly experience of this operation in the pre-antiseptic days. At the same time he had, in his own practice, continued to follow them. He believed that, notwithstanding the introduction of antiseptics, there was still danger in attempting to hasten the evacuation of the fluid by abdominal pressure or by washing out the cavity. From the nature of the fluid it was impossible for the evacuation to be completed at one sitting, and therefore it was better to leave it to be gradually accomplished by the powers of nature. If the hand was employed to make pressure from above, the moment the pressure was relaxed air would, of course, rush into the cavity. He believed all external pressure to be contraindicated, partly on this ground, and partly because of the risk of rupturing a hæmatosalpinx. With regard to the washing out, inasmuch as it could not be effectual in thoroughly cleansing the cavity (for no amount of douching would bring away the last drops of so viscid a fluid), he thought it, too, was better omitted. No fluid was more susceptible to the changes of decomposition than effused blood, and he, personally, always felt that his patient was safer when he had avoided all manipulations that involved the risk of introducing air or water, or even chemical solutions, into the retention sac. In two or three days, if a sufficient opening was made, the sac would empty itself spontaneously, and this would be best and most safely accomplished by avoiding all attempts to hasten the process. Let a means of exit be provided, and leave the rest to nature.

Dr. Herman said that the probability of hæmatosalpinx with

retained menses varied with the site of the atresia. When there was a septum low down in the vagina (the condition commonly spoken of as "imperforate hymen") the blood was usually retained in the vagina without distension of the uterus, much less of the tubes; but when the atresia was high up, so that the uterus became distended, hæmatosalpinx was more frequent. The result of operation for absence of the vagina depended partly on the condition which produced absence of that canal. He had treated two cases of hæmatometra with absent vagina by forming a vagina. In one case the vaginal canal had been obliterated as a result of sloughing during an acute disease in childhood, and in the operation dense fibrous tissue had to be cut through. A canal was made and the fluid let out, but all attempts to keep the canal open failed. The patient afterwards went to another hospital, but treatment there failed also. The canal could be dilated with probes, bougies, &c., but unless this was constantly kept up it contracted to a minute sinus. In the other the absence of the vagina was a defect in development, and the new canal was made by tearing through cellular tissue between urethra, bladder, and rectum. In that case the result had been entirely satisfactory. He had observed the patient for six or seven years, and she had menstruated without trouble all that time. In two cases of married women in whom, from absence of vagina with rudimentary uterus, there was no retention of menses, but sexual intercourse was impossible, he had made a vagina, or rather a mucous cavity, which had proved sufficient for that purpose. He agreed with the late Dr. Matthews Duncan that washing out after opening a cavity containing retained menses was bad practice. He had himself only lost one such case. In that patient the vagina, without his instructions and against his wish, was washed out, and fatal peritonitis followed.

Dr. Herbert Spencer thought that the case described was one of great interest, and that the remarks made by the previous speakers were very instructive. He agreed with Dr. Herman that the difficulty and danger of the treatment of retention of menses depended chiefly upon the seat of the obstruction, and also upon the presence or absence of hæmatosalpinx. In a case of simple hæmatocolpos from so-called imperforate hymen, the treatment should nowadays, he imagined, be always successful. But the danger was much greater when the uterus and Fallopian tubes were distended. He thought that Dr. Lewers was to be congratulated upon the successful treatment of a very difficult case, concerning which the only doubt was as to whether the new vagina would remain patent. He (Dr. Spencer) would be inclined to expect that the sinus would close unless flaps of skin could be turned into the new vagina. He could not agree that it was justifiable to perform abdominal section

merely for the purpose of seeing whether the tubes were distended: no one could say that a patient would not die as a result of such an operation, it might be years subsequently. Hæmatosalpinx could be diagnosed in these cases by the ordinary examination, as in a case of his own, in which the typical tubal tumours at the sides of the distended uterus left practically no doubt as to their nature. In such cases he thought abdominal section advisable. His patient had refused it, and he had endeavoured to drain the Fallopian tubes by aspirating the blood through the hymeneal septum (in another case he would prefer aspirating through the perinæum), opening the septum some days later. In this, however, he was disappointed, for the tubes remained distended after the evacuation of the vagina and uterus, and although the patient left the hospital quite well she subsequently nearly lost her life from peritonitis, evidently set up by the tubes. In Dr. Lewers' case, if the new vagina could be kept patent, he had no doubt that the treatment adopted was the proper one; but if the passage closed, it would, he thought, indicate abdominal section, and the removal of the uterus and appendages as the proper treatment for these rare and difficult cases of absence of the vagina with retention of menses.

The PRESIDENT doubted whether Dr. Lewers ought to call the fold surrounding each of the depressions described, a "hymen." He was familiar with the appearance as figured, and had shown something very like it in a case of extroversion of the bladder in a former volume of 'St. Bartholomew's Hospital Reports.' These duct-like openings he had also seen more than once in other deformities of the genital organs, and in at least one case of vaginal transverse septum with double uterus above, but not continuous with it. He regarded them as the stranded distal extremities of Müller's ducts. He thought Dr. Lewers could hardly say that hæmatosalpinx was common in cases of hæmatocolpos. Hæmatocolpos (or "retention of menses with imperforate hymen" so called) was not very uncommon, and was but rarely complicated by distension of the tube with blood. In some of the rarer forms, no doubt, this was occasionally met with; but he thought it ought not to go out that in the opinion of the Society it was correct practice to open the abdomen as a matter of routine in cases of retained menses, to see if there was not a hæmatosalpinx. Such a practice would, he felt sure, only increase the mortality. There might be cases which justified this course, such as those in which repeated operations had to be done to evacuate retained menses, or where in such cases a distended tube was felt, but they would be rare. As to the ordinary form, he saw it every few months, and his practice was personally to wash out the fluid once for all, believing that this was the safer course; and that the dangers referred to by Dr.

Matthews Duncan as following on washing out applied to the days before the careful use of antiseptics. But he had seen inaction answer equally well. With regard to the manufacture of a new vagina, he had recently had a case in which the whole vagina except the actual fornices was absent. He dissected as Dr. Lewers had done, and then stitched the skin to the fornices. The result had been good so far. But all the attempts which he knew of to make a satisfactory canal merely by burrowing through cellular tissue and keeping it open with bougies had failed, and he did not think a vagina could be satisfactorily made in this way.

Mr. Alban Doran reminded the author of the paper that if a vagina were successfully opened up, and a more or less normal cervix exposed, the patient's trouble would not necessarily be over, and perfect function, that is pregnancy, might involve great difficulties. An abdominal section might not settle the case, for malformations in the upper part of the genital tract were not always easy to define except by careful dissection—an impossibility at an operation. Mr. Doran had under his care a young woman aged 23, who was seized early in July with symptoms of ruptured tubal cyst. A swelling developed to the left of the uterus, projecting into Douglas's pouch; it grew rapidly larger when under Dr. Hubert Roberts's observation in September. The sound passed through an apparently normal os, $2\frac{3}{4}$ inches into the uterine cavity to the right and in front of the swelling, which reached as high as the umbilicus. Mr. Doran opened the abdomen and found a large cyst, with thick reddish-brown walls, continuous with the fundus. The left round ligament sprang from its anterior aspect far outwards. There was a kind of hernia of its inner wall also, strongly adherent to intestine, which was separated, then the cyst was tapped, and two pints of deep brown fluid came away. In its lowest part was much broken-down tissue, possibly relics of very early gestation. The collapsed cavity was packed with iodoform gauze, and was now contracting. It was not easy to say whether the cyst were a left cornu impregnated through a once patulous os tincæ, or a left cornu never open at either end, and the seat of a recent hæmatometra not dependent on gestation. Interstitial gestation sacs always, according to records, burst early, yet it was possible that in this case cystic dilatation of the portion of the tube which traversed the uterine walls might have existed as a congenital malformation.

Dr. Ewen Maclean referred to two cases of retained menses which he had had opportunity of observing. The first, where the atresia existed in the lower half-inch of the vagina only, was readily opened and evacuated. The usual methods to ensure the patency of the canal were successful, and the patient subsequently married. In the other case the atresia was present from

hymen to os uteri; the uterus was distended to fœtal-head size, the Fallopian tubes remaining uninvolved. A tedious dissection resulted in the evacuation of the usual dark, treacle-like fluid, but the artificial vagina could not be kept open. Symptoms of re-accumulation shortly appeared, and the operation was repeated some months later, but eventually with the same result of closure of the wound. Abdominal section was next effected, and much the same kind of difficulty was experienced in removing the appendages as in their removal for myoma uteri; at the same time the fluid was evacuated through the reopened wound. The tubes were found to be macro- and microscopically normal. It was also found that from the difficulty in isolating the right appendages a small portion of the ovary of that side had been left *in situ*. This doubtless accounted for the recurrence yet again of the symptoms of collection of menstrual fluid. Finally the abdomen was again opened, and a complete hysterectomy was performed, followed by a good recovery and the permanent relief of the patient. Dr. Maclean found that to the naked eye the mucosal and muscular coats of the uterus appeared atrophied, and that microscopically no further structural change was detected than a surface epithelial desquamation of the mucous membrane.

Dr. Lewers, in reply, said that his paper dealt only with hæmatometra, and his remarks as to a preliminary abdominal section had reference to hæmatometra only, such as was produced by a more or less complete absence of the vagina. In such cases hæmatosalpinx was by no means uncommon. It could not be certainly diagnosed beforehand; and, indeed, too much examination bimanually was undesirable. If the Fallopian tubes were distended with blood, rupture of them might easily be produced by the examination. He was, therefore, of opinion that in the rare cases where the vagina was more or less completely absent, and where there was evidence of hæmatometra, a preliminary abdominal section was the best treatment. In the comparatively common cases where retention of menses was due merely to an imperforate hymen, he agreed with those speakers who considered abdominal section quite unnecessary, because in such cases there was a strong probability that the Fallopian tubes were not dilated. Dr. Lewers had had some seven or eight cases of retention of menses in the vagina due to imperforate hymen. His practice was to open the imperforate hymen with Paquelin's cautery, and to abstain both from washing out the vagina, and from making any pressure on the abdomen to hasten the exit of the fluid. In all his own cases of hæmatocolpos the patient's recovery had been uninterrupted. In the case of hæmatometra described in his paper he did wash out both sides of the double uterus. In that case there was a very large raw surface made in order to reach the uterus, and it

seemed a good thing not to leave the retained menstrual fluid, which was very ready to decompose, any longer in contact with the wound than could be avoided. The extreme difficulty of keeping the new vagina open was an important fact in the management of these cases. So far in his own case the patient had menstruated regularly since the operation—some eight months. If it were found in any such case to be impossible to keep the opening patent, so that repeated operations became necessary to give exit to the retained fluid, it seemed to him that removal of the uterine appendages, with the view of bringing about the menopause, would probably be the best treatment. The case referred to by Mr. Doran showed the difficulty that might sometimes arise in identifying a hæmatosalpinx even after the abdomen was opened. Dr. Lewers thanked the Society for the attention given to his paper.

NOVEMBER 4TH, 1896.

F. H. CHAMPNEYS, M.A., M.D., President, in the Chair.

Present—37 Fellows and 6 visitors.

A set of books was presented by Dr. Cullingworth.

The following gentlemen were elected Fellows of the Society :—Guthrie Rankin, M.D.Glas. ; and Sidney Arthur Mugford, L.R.C.P.

FIVE SPECIMENS OF FIBROID TUMOUR OF THE UTERUS REMOVED BY THE INTRA-PERITONEAL METHOD.

Shown by W. DUNCAN, M.D.

SELF-RETAINING GLASS RETRACTORS.

Shown by Dr. MACNAUGHTON JONES.

DR. MACNAUGHTON JONES exhibited his self-retaining glass retractors with smooth pothook ends. The retractors are curved to lie on the abdominal wall, and are fixed in position by a strap and buckle that pass behind the waist. They are made of different sizes, and the hooks are of sufficient width to enclose a thick abdominal wall.

A CASE OF COMPLETELY CLEFT SPINE ASSOCIATED WITH AN UNUSUAL VISCERAL MALFORMATION IN AN ANENCEPHALIC FŒTUS.

By Thomas G. Stevens, M.D., F.R.C.S.,

LECTURER ON ELEMENTARY BIOLOGY, AND SENIOR DEMONSTRATOR OF BIOLOGY, GUY'S HOSPITAL MEDICAL SCHOOL.

The specimen, of which the following is a description, was sent me by Dr. D. H. Forty, of Wotton-under-Edge. The mother was aged thirty-five years, and had had two other children, the last ten years before the present one. There were no miscarriages at any time between. Labour was induced on account of a watery blood-stained discharge which had persisted for some days. The fœtus presented by the feet, and was delivered by traction. The mother made a good recovery, though she was anæmic for some weeks afterwards. There was no history of maternal impression, and no note as to the state of the placenta and cord. The fœtus is a female of about eight months' growth. It presents a frog-like appearance on account of the absence of neck and cranium, and the upwardly turned face.

It is well nourished and fat, especially the limbs. The face and features are naturally formed, the ears normal in shape, external meatus present and patent.

The cranium, with the exception of the base, is absent. Hair is present along the edge of the basis cranii. Chest very prominent, with well-marked mammary elevations. The neck is absent, the integuments being continued straight down from the face to the chest in front, and the shoulders laterally. The umbilicus is situated very low down on the abdomen, with a piece of healthy cord attached. Below

the umbilicus and continuous with it is a rough irregular elevation. An extroverted bladder with the two orifices of the ureters is to be seen at the lower angle. On either side of the ureteric orifices are imperfectly formed elevations representing labia majora and minora. Between the labia minora the hymen, perforated with three holes, bulges. Just behind the hymen is the anus, a very small opening hidden by a valve of skin.

On the dorsal surface are two large protuberances,

FIG. 1.

separated by a deep groove. The posterior one is the larger of the two, and measures about 4½ inches by 3 inches at the widest part. It is a somewhat flattened ovoid in shape, with the large end forwards. It is covered by a dull corrugated membrane, bright red in the recent state, and continuous all round with the skin of the back. The junction of the skin and membrane forms the greatest possible contrast in colour, and feels extremely hard, as if the swelling were protruding through a bony ring. The

most posterior part of the swelling has a circular outline, in the centre of which near its junction with the skin is a pit, down which a probe can be passed, to appear below at the anus. On the left side, just above the pit, is an opening through which a probe can be passed into a blind cul-de-sac.

A microscopic section through the wall of the swelling shows intestinal glands on the outside, then a muscularis mucosæ, two layers of muscular fibre, and finally a layer of flattened epithelium forming the lining of the swelling, which is in reality intestine turned inside out, and containing other viscera.

The anterior swelling is more or less fan-shaped, with the narrow end posterior. It has not quite the same consistence and feel as the posterior swelling, being more rough and stringy to the touch. Its anterior free margin overlaps the superciliary ridge of the fœtus. The attached portion is continuous at the sides with the skin above the ears and temporal regions. Posteriorly its external covering is reflected beneath the above-mentioned bony ring, in the deep grove between the two swellings. In the middle line beneath the bony ring and between the two swellings is a wide aperture, lined with smooth mucous membrane, through which a probe can be passed into the mouth. This probably represents the pharynx. The microscopic section of this portion will be referred to under the heading Nervous System.

Muscular system everywhere well developed, and only such abnormalities were found as would be expected with the malformations of the bone to be mentioned.

Alimentary system.—Mouth well formed, lips normal, præmaxillæ synostosed, leaving no cleft in the alveolar margin. Hard palate deeply grooved, but not cleft. Submaxillary, sublingual, and parotid glands present. Tongue well formed and normal as to musculature. Uvula and fauces with tonsils normal. Pharynx about one inch long, very wide and flattened from above downwards, opens beneath the bony ring on the exterior between the two dorsal masses; its lining is smooth, and looks like altered

skin. This appears to represent the stomodæum developmentally. The rest of the alimentary canal as far as the rectum is represented by the large posterior dorsal mass (and, as has been shown, turned inside out with the glands on the surface). Connected with this are several pouch-like protuberances, producing irregular thickenings of the wall turned towards the inside, none of them being con-

FIG. 2.

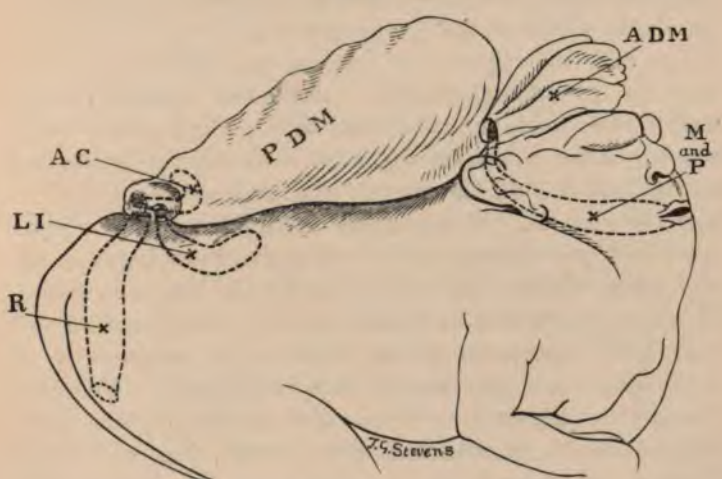

Outline drawing showing intestinal malformation.

A C. Appendix cæci.
L I. Large intestine.
R. Rectum.
P D M. Posterior dorsal mass.
A D M. Anterior dorsal mass.
M and P. Mouth and pharynx.

tinuous with one another. These pouches contain a pultaceous, cheesy material, and on section show intestinal glandular structure, more or less degenerate, and two muscle layers. These are all on the left side of the mass. At the anterior portion of the mass, just where the edge doubles over to become continuous with the pharynx, is an irregular mass of solid tissue embedded, which on section is glandular and looks like slightly altered

pancreas. On the right side also, near the anterior margin, is a rounded solid mass contained in a separate cavity lined with smooth mucous membrane. It is about the size of a small walnut, and on section gives the appearance of spleen. At the posterior end where the rectal invagination (proctodæum) opens on the dorsal mass, there are two other orifices to be seen. One small and to the left communicates with a curved finger-like pouch, which projects into the cavity of the mass, and in the recent state was lying with its extremity downwards between the two lobes of the dorsal projection of the liver. This also shows intestinal glands on section, and appears to represent the vermiform process. The other opening, larger and to the right, communicates with a blind pouch representing large intestine, to be seen inside the peritoneal cavity just behind the uterus, and apparently between it and the rectum. It contained meconium. The rectum contained only mucus, and ended at the anus between the two labia minora, and very close to the vaginal orifice. Between the rectum and skin on the dorsal surface was only dense connective tissue, there being apparently no bony connection between the ossa innominata. The liver formed the largest mass to be seen on opening the abdomen in front. It consisted of two equal lobes, very broad in front and above under the diaphragm, gradually tapering downwards and backwards through the bony ring to appear inside the posterior dorsal mass. Where the liver passed through the bony ring the glandular tissue was markedly constricted. When looked at from behind the two lobes had a flattened appearance, with a flattened sac, the gall-bladder lying between their two halves. Superiorly two "horns" projected from either lobe into the corresponding corners of the posterior dorsal mass, lying in two gutters, as it were, in the thickened wall of the mass. The ligaments consisted of a flat vertical band and two lateral ones. The vertical band connected the front of the liver with the under surface of the diaphragm and anterior abdominal wall as far as the umbilicus. Behind, the anterior fold of the

dorsal mass was continued down the middle line between the two horns above mentioned, leaving a free edge where it abutted on the liver substance, apparently thus representing a mesentery. The two lateral ligaments connected the right and left lobes of the liver in front with the diaphragm, and helped to form the upper boundaries of the capsules of the kidneys. That all this mass was really liver was proved by microscopic investigation.

The thyroid and thymus glands, though relatively very large, were normal in shape and position.

The trachea and lungs were normal, the latter being small and airless.

Genito-urinary system.—The kidneys, slightly lobulated and normal in size, were lying in connective-tissue capsules connected with the sides of the liver, this latter being hollowed out by mutual pressure. The right pelvis and ureter were normal in size; the left pelvis and the upper part of the left ureter were dilated for about 1½ inches, gradually narrowing down to the normal. This appears to have been caused by the somewhat long ureter becoming kinked at about its centre.

The bladder presented the usual appearance of extroversion, the mucous membrane corrugated, and the openings of the ureters apparent and admitting bristles easily.

The *uterus* was bicornute for about half its length, the Fallopian tubes appearing at the ends of the two horns. The ovaries normal in position, small and flattened by pressure against the liver.

Circulatory system.—Owing to the great size of the liver, the heart appeared to be somewhat compressed, and its surfaces—usually anterior and posterior—to be twisted so as to become superior and inferior. Also more than usual of the right ventricle was apparent from above. The only abnormality seen from the outside was the presence of the left superior vena cava, which was about equal in size to the right, and the apparent origin of the aorta from the *right* ventricle bifurcating above to give off *two* aortic

FIG. 3.

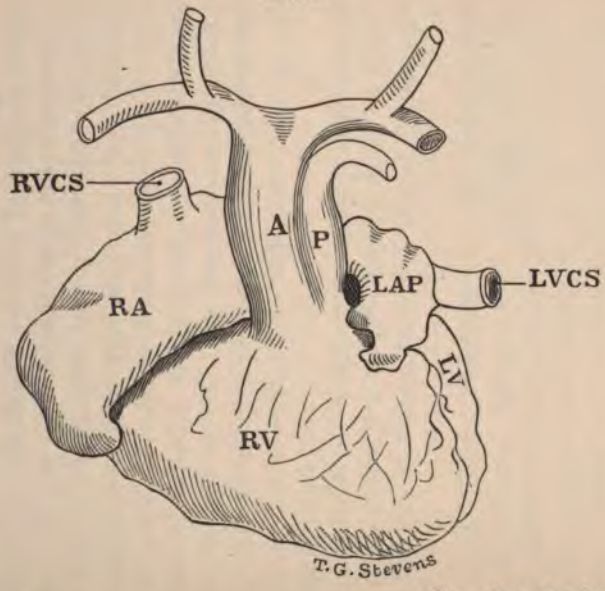

FIG. 4.

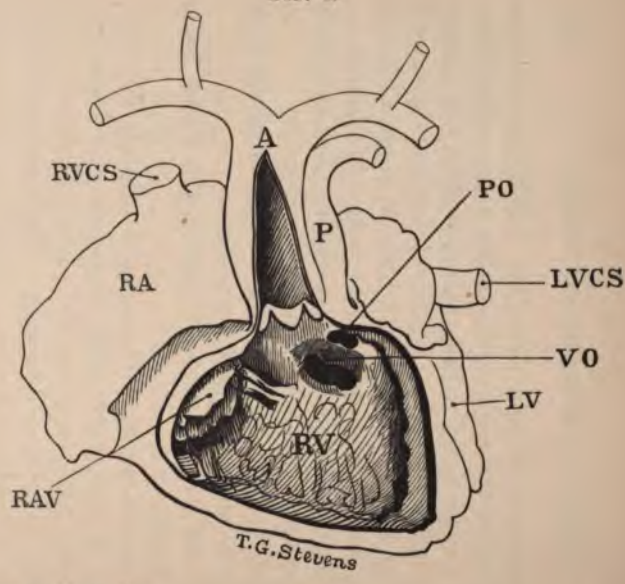

Two views showing the cardiac malformation.

RV. Right ventricle.
LV. Left ventricle.
RA. Right auricle.
A. Aorta and bifurcation.
P. Pulmonary artery.
RVCS. Right vena cava superior.
LVCS. Left vena cava superior.
LAP. Left auricular appendage.
PO. Opening of pulmonary artery into right ventricle (contracted).
VO. Opening of left ventricle into right ventricle. Deficient septum.
RAV. Right auriculo-ventricular valve.

arches, each of which furnished innominate and subclavian arteries. On laying open the right ventricle it was apparent that it really did give off the aorta. The opening was wide, and guarded by three semilunar valves. The pulmonary artery also opened into the right ventricle a little to the left of the aortic opening. Its orifice was very much contracted, and hidden by a fold of endocardium. Below and between the aortic and pulmonary orifices was a deficiency in the interventricular septum; its edges were rounded and smooth, and measured about $\frac{1}{16}$ inch across. The right auriculo-ventricular opening had apparently only *two* cusps to its valve. The interauricular septum was extremely rudimentary,—in fact, the two seemed continuous.

The left auriculo-ventricular opening was small, otherwise normal.

The intestinal branches of the two abdominal aortæ were represented by small irregular vessels supplying the dorsal mass.

The abdominal aortæ and two posterior venæ cavæ were lying on the anterior surfaces of their corresponding halves of the cleft spine to be described.

The vessels in the limbs were all normal. The portal veins could not be traced, but were probably represented by numerous small vessels in the dorsal portion of the central vertical ligament.

Nervous system.—Brain as such is not at all developed, but the anterior dorsal mass undoubtedly represents it for several reasons.

First, the cranial nerves can be traced into it, and with the exception of the auditory this was easily done in every case.

Secondly, it was continuous with the spinal cords—for two were present.

Thirdly, microscopic sections of various parts showed in places rows of large, deeply staining, irregular-shaped cells which looked like multipolar nerve-cells; also other cells connected with delicate connective-tissue strands

representing neuroglia, and congeries of blood-vessels forming plexuses such as one finds in the choroid plexus.

For these reasons it would seem that there is really some development of brain, and it would be better to call the fœtus *pseudo*-encephalus rather than anencephalus, as Hurst and Piersol suggest for a similar condition.

Tracing this mass downwards towards the cleft spine, it was found to be continuous with two distinct spinal cords, each of which was situated in a groove in the corresponding half of the vertebral column. The proof that these two masses ought to be called separated cords was found in the microscopic sections of them. In the section of each a central canal lined with columnar epithelium was found, around which were groups of deeply staining, unmistakable nerve-cells. No distinction into white and grey matter could be made out, and no medullated nerve-fibres were found.

Each of these cords gave off their corresponding spinal nerves, the roots with their large posterior ganglionic masses being normal in every case.

The exits of the cranial nerves from the basis cranii were very difficult to distinguish in the recent state owing to the primitive development, and somewhat to the maceration of the specimen.

However, it is probably true that most of them had their usual sites, for the vagus, glosso-pharyngeal, and spinal accessory, together with the internal jugular vein, came out of the same opening. The third, fourth, and first division of fifth and sixth also went through the sphenoidal fissure, only separated from the optic nerve, however, by some dense connective tissue. The eyes were normal in appearance. The external auditory meatus were present and patent, the membranæ tympani being situated much more beneath the skull base than normal.

Skeletal system.—The skull presented no difference from the usual anencephalic skull as described by Dr. Amand Routh and Dr. A. E. Giles in the 'Transactions of

the Obstetrical Society' for 1895, p. 219, all the membrane bones being absent with the exception of the orbital plates of the frontal bones and the lower parts of the squamous portions of the temporal bones.

The vertebral column presented the most interesting malformation of the specimen, appearing collectively as the two halves of the original spinal column, completely cleft from the occipital bone to the tip of the coccyx. The development of the two halves also seemed to be irregular, the right side being much better formed than the left, and the individual vertebræ more easily distinguished. The cleft measures 1½ inches transversely at the widest portion, about opposite the second lumbar vertebræ. The angles of curvature of the various parts of the spinal column were remarkable. The sacrum and last lumbar vertebra made their normal angle with one another, but the halves of the sacrum were so rotated inwards that the lower end looked towards the median plane of the fœtus. The auricular surface, for articulation with the ilium, which should look almost directly outwards, was turned vertically downwards. The result of this was that on both sides the ilia only partly articulated by their auricular surfaces, the joint being maintained by strong ligamentous fibres joining the posterior part of the iliac crest to the posterior surface of the sacrum. On the right side four halves of sacral vertebræ can be made out; the fifth, being only cartilaginous, has dried up. The bodies, laminæ, and parts of the spinous processes can be made out; the sacral foramina are well formed, and four can certainly be distinguished. On the left side the sacral vertebræ are not nearly so distinct, and there seems to be some irregular bony formation which, in the recent state, appeared to roof in that part of the spinal canal.

Lumbar vertebræ.—Nearly vertical in outline, no anterior convexity being present. They form the greater part of the bony ring which the cleft spine gives rise to. On the right side the individual vertebræ, five in number, can be easily made out. Their several parts are perfectly

formed. On the inner side, joining the last lumbar vertebra to the first sacral, is a crescent-shaped piece of bone, apparently formed from a separate centre of ossification, and only connected with the other vertebræ by cartilage. There are several other irregular pieces of bone joining in this way the inner sides of the halves of the bodies of the lumbar vertebræ,—notably in the third lumbar vertebra of the right side, in which it seems to be an outgrowth from the body of the vertebra. These may represent extreme degrees of "lipping" of the articulating surfaces of the vertebræ, developed in consequence of the pressure of the viscera protruding through the spinal cleft. On the left side the first three lumbar vertebræ are fairly well developed, but the fourth and fifth are fused. The laminæ and spinous processes are very irregular, and are more curved than on the right side, forming a kind of groove in which the spinal cord rests.

The dorsal vertebræ are all represented on both sides, but present so small a degree of development of the bodies that an extreme amount of *dorsal retroflexion* is produced. The laminæ and spinous processes are well formed, as also are the transverse processes with their articular surfaces for the tubercles of the ribs. The retroflexion produced is so extreme that the dorsal spine on both sides is bent double, the spinous process of the first dorsal touching that of the eleventh. This retroflexion produces a deep hole on either side, into which the two halves of the spinal cord dipped in the recent state, giving off the dorsal nerves above and below instead of externally. On the right side the separate laminæ can be easily made out; on the left they are all more or less fused. The bodies on both sides are irregularly fused. The dorsal vertebræ form the upper boundary of the bony ring formed by the cleft spine.

The *cervical vertebræ* are the worst developed portions on both sides. On the right three masses apparently represent the seven bodies fused irregularly, and four masses represent the lateral portions of the bones per-

forated by numerous foramina for the cervical nerves. The spinous processes are fused into one plate of bone, which fills up the interval between the first dorsal vertebra and the base of the skull.

On the left side there are only two or three irregular nodules, wedged in between the dorsal vertebræ and base of skull to represent cervical vertebræ.

Remarks.—There seem to be two distinct conditions to explain in this fœtus. First, the anencephalous or rather pseudencephalous condition; and second, the completely cleft spine and intestinal malformation.

The causes of the first have been ascribed by Dareste, Marchand, Perls, and others, to undue pressure of adherent and constricting amnion; by Ahlfeld to increased intracranial pressure with rupture of the primary cerebral vesicles, in which the spinal canal may participate to some extent, producing a notencephalous condition; by v. Recklinghausen to some primary interference with the normal development of the blastoderm. Now the theory of Ahlfeld seems to be the one most likely to fit most cases of anencephalous fœtus, especially as intermediate forms of hydrocephalus and hydrorrhachis with consequent malformation have been met with. But such a theory will not account for the complete cleft of the spinal column, nor the extremely interesting and possibly unique intestinal malformation in this specimen.

In order to explain this, in my opinion, one must go back to the primary development of the fœtus at the time of the formation of the notochord, and look for some error in the behaviour of the primary germinal layers. It cannot be conceived that some merely mechanical cause, such as adherent amnion, could account for such a malformation. In the first place it must be noted that the malformation is limited to that area of the spinal column in which the notochord is usually found, for the cranium is not more altered than is usual in anencephalic fœtuses. Then, again, those portions of the alimentary tract which are normal are confined to the first part and the last,—

just those, in fact, that we should expect to be formed by invaginations of epiblast, and not at all from hypoblast. If the hypoblast be conceived to become adherent to the epiblast before the differentiation of the notochord, as we know does occur at the time of the first appearance of the primitive streak and groove, and then a cleft to appear down the centre of this junction, then all the essential features of the malformation can be explained. The notochord first appears as a rudiment on each side of the cleft, derived either from the hypoblast or the epi- and hypoblast. Next the mesoblast appears on each side, forms its somites, vertebral and muscle plates in the usual way, and development proceeds normally, but in two halves, joined only at those parts of the embryo where there is *no* notochord, namely, at the cranium and the extreme posterior end of the vertebral column. The mesoblast splits into somatopleure and splanchnopleure; the former joins up ventrally as usual (except where the bladder is extroverted), as does the latter, forming the ventral boundary of the intestine; but the intestine remains open behind or dorsally, owing to the primary cleft of conjoined epiblast and hypoblast, so that the lining of the alimentary canal becomes continuous with the skin of the back. Now the liver and other glands in connection with the alimentary canal develop in the ventral wall of the gut and begin to grow, and naturally do so in the direction of the least resistance. This they can do dorsally towards the cleft spine, but not so easily ventrally on account of the body wall being closed. Then, as they are developed between the ventral wall of the gut and the body wall, as they grow they must gradually push the intestine before them through the cleft, thus turning it inside out. Finally the liver, spleen, &c., grow through the cleft, constantly pushing the gut before them, and so we arrive at the condition of the large posterior dorsal mass with the lining mucous membrane of the intestine *outwards*, the peritoneal coat inwards, and the mouth and anal invaginations opening on the exterior, as they had

already opened into the intestine rudiment before the liver, &c., had commenced to grow to any extent.

In searching the literature of teratology for a similar case, the only one approaching it I could find is a specimen reported by Ahlfeld of a pharyngeal diverticulum opening on the back of an anencephalic hydrorrhachitic fœtus. I cannot find any mention of any other similar intestinal malformation, and neither Ahlfeld, Förster, nor Hurst and Piersol figure a specimen of completely cleft spine. In the museum of the Royal College of Surgeons of England, however, there is a specimen of complete cleft of the lower half of the spinal column, No. 338 of the fœtal malformation series; it is a very ill-developed specimen, the vertebræ being very poorly developed, and the sacrum not distinguishable as such. There is no mention in the catalogue of any intestinal malformation accompanying it.

Dr. Dakin complimented the author on his interesting description of a very rare deformity. It was very difficult to account for the presence of two separate spinal cords and columns in the fœtus. Was it possible that this case was one of dichotomy of the spinal column occurring in that structure only?

Dr. Stevens, in reply to Dr. Dakin, said that he had considered the possibility of the specimen being a parasitic fœtus. However, on careful examination no trace of doubling of any structure, with the exception of the spinal column and cord, could be found. He thought there could be no doubt that the central canals found microscopically really represented two separate cords, and that the vertebræ appeared to be really halved, and in no way connected with a double monster with two spinal columns.

ON THE STRUCTURE OF THE RIPE PLACENTA, AND THE CHANGES WHICH OCCUR IN PLACENTÆ RETAINED *IN UTERO* AFTER THE DEATH OF THE FŒTUS.

By Thomas Watts Eden, M.D., M.R.C.P.

Preliminary Note.

The portion of this paper which deals with the ripe placenta is an abstract of a communication about to be published in the 'Journal of Pathology and Bacteriology,'* and is introduced in order to render intelligible the succeeding portion dealing with the changes found in retained placentæ; the latter portion has not been previously made public.

I. *The Structure of the Ripe Placenta.*

The placenta at term differs so widely from the young and growing organ that it requires separate description. To understand its structure we must remember that we are dealing with an organ which, though complex in arrangement, is composed of the simplest elements, and is intended to serve only a temporary purpose. When that purpose is fulfilled it is shed as a withered leaf is shed by a tree,—that is to say, the placenta is a caducous organ. All caducous structures begin to degenerate for an appreciable time before they are cast off by the individual—plant or animal—to which they belong; indeed, the immediate cause of their shedding is that they are degenerated. So the ripe placenta is a worn-

* 'Journal of Pathol. and Bacteriol.,' December, 1896.

out, senile structure which is no longer fitted to play its physiological part, and is therefore repudiated both by the fœtus and the mother. This failure of vitality in the placenta commences long before the approach of term, and results in certain changes which it is the object of this part of the paper to describe.

Practically all the constituents of the placenta are affected; we shall consider first the fœtal and then the maternal structures.

(1) *Changes in the fœtal structures.*—The first to appear, and the most important change of all, is a slowly progressive obliteration of a certain number of branches of the allantoic (umbilical) arteries. The affected branches are irregularly distributed, but are most numerous in the marginal cotyledons. The terminal and medium-sized arterioles are first affected by the change, which is of the nature of endarteritis, and leads eventually to complete obliteration of the affected vessels. The corresponding capillaries and veins remain unaltered until the circulation through them is suspended, when they become obliterated by thrombosis. The beginnings of the process may be detected as early as the seventh month, and in the healthy placenta at term the total number of arteries showing the early stages of the affection is very large, although comparatively few of them become actually obliterated except in the marginal cotyledons.

A progressive diminution of the blood-supply to large tracts of villi results from these changes. The first effect upon the villi appears to be the atrophy and degeneration of their epithelial covering. The latter change is a form of hyaline or fibrinous degeneration (coagulation necrosis), the altered tissues possessing many of the staining reactions both of hyaline material and fibrin. Upon the degenerated areas layers of true fibrin are deposited by clotting from the maternal blood. In this manner villi become enclosed in thick rings of fibrinous material, and neighbouring villi be-

come welded together by extension of the fibrin deposit right across the intervening maternal spaces. Scattered areas of consolidation are thus formed in the spongy placental tissue, to which the name of "white infarct" has been applied. The greater number are of microscopic size, but in almost every ripe placenta some are large enough to be visible to the naked eye; they may, however, attain the size of a pea or a filbert, and sometimes even an entire cotyledon may be consolidated. They occur most frequently in the marginal cotyledons, and on the fœtal and maternal surfaces of the placenta.

The involved villi are of course functionless, because they are out of contact with the maternal blood. All the involved structures atrophy, and in the larger infarcts fatty and calcareous degenerations are found. They grow by peripheral extension: in the centre the changes are most advanced; passing outwards they become more and more recent, and all the stages may be studied in a single specimen. In the larger infarcts three distinct zones may be distinguished: a *central zone* of degenerating structureless material; a *middle zone* of atrophied and devascularised villi; and an *outer zone* of villi surrounded by more or less complete rings of fibrin, but not otherwise structurally altered.

Another form of consolidation, known as the "non-fibrinous infarct," sometimes occurs in the ripe placenta. It consists of areas of closely crowded villi in contact with one another by their epithelial covering, but containing very little fibrin. This form is probably due to blocking of the maternal arteries which supply the affected cotyledon, and not to fœtal endarteritis.

From a study of the structure of the membranes it becomes clear that a process similar to that of fibrinous infarction occurs in the extra-placental chorion, and results in the atrophy and disappearance of its villi. In the membranes immediately outside the placental margin villi may always be found in various stages of atrophy,

and surrounded by rings of fibrin, although in the parts more distant from the placenta they have entirely disappeared. It seems probable that the disappearance of the villi from the chorion during the second month of gestation is due to the same process, which in the neighbourhood of the placental margin continues throughout the period of growth of the membranes. Infarction, therefore, represents the extension, during the later months of gestation, to the placental chorion of changes which occur with regularity in the extra-placental chorion during the earlier months. It occurs to a greater or less extent in all healthy placentæ, and is not to be regarded as a pathological change, but as the outcome of the natural processes of evolution and decline.

(2) *Changes in the maternal structures.*—Thrombosis of the subplacental sinuses has been described as occurring under normal conditions as early as the seventh month by Friedländer,* and more recently by Minot.† The number of sinuses affected is not great, and it is probable that, in view of the free anastomoses present, the circulation through the intervillous spaces is not materially hindered. The process is associated with the presence of giant-cells in the veins, the origin of which is obscure.

The serotina of the ripe placenta consists of two layers, a superficial (compact) and a deep (cavernous) layer. The latter shows few changes. The former is the seat of a degenerative process similar to that which affects the chorionic epithelium. The change begins in the intercellular substance, which is converted into a deeply-staining fibrillated material allied to fibrin. Gradually the protoplasm of the decidual cells is involved, and finally their nuclei break up and disappear. The change begins on the surface, but often extends irregularly into

* 'Untersuchungen über den Uterus,' 1870.

† Minot, 'Buck's Reference Handbook of the Medical Sciences,' art. "Placenta," vol. v.

the deeper layers. Fibrin from the maternal blood is deposited upon the degenerated surface.

In the intra-placental decidual processes a form of cystic degeneration occurs.

At term, coiling serotinal arteries may sometimes be found thrombosed for a considerable distance, and the mouths of the maternal arteries and veins are often more or less completely blocked by deposits of fibrin.

Fatty and calcareous degenerations are common in the serotina at term.

II. *The Changes which occur in the Retained Placenta.*

By a "retained placenta" is meant a placenta retained *in utero* after the death of the fœtus, irrespective of the period of gestation to which it belongs, or of the length of time which has elapsed between the death of the fœtus and the evacuation of the uterus.

In studying the changes which are found in these placentæ it is important to bear in mind that there are, or may be, two factors in the causation of those changes. The first factor is the morbid condition which led to the death of the ovum, and which may have directly affected the placenta; the second factor is the arrest of the fœtal circulation, *i. e.* the death of the villi. Changes due to the operation of the first factor may be called *primary*, those due to the second factor *secondary* changes.

The difficulty of distinguishing primary from secondary changes when the latter are far advanced is very great, and forms a serious obstacle to the study of these placentæ. For practical purposes it is necessary to divide them into two groups: (1) cases where the placenta has been retained for but a short time after the death of the fœtus, which is born in a non-macerated or but slightly macerated state (Germ. *Frischtodt*); and (2) those in which the placenta has been retained for a considerable time, and the fœtus is more or less markedly

macerated (Germ. *Faultodt*). The primary changes are obscured in the second group by the superimposed secondary changes, and it is obvious that the first group offers the best chance of studying them. The secondary changes, on the other hand, are most pronounced in the second group, although their beginnings may be found in the first.

Pathology has been overweighted with a great deal of work upon the dead (retained) placenta, in which the need for this distinction between primary and secondary changes has been lost sight of, with the result that the death of the fœtus has been frequently ascribed to post-mortem changes. An example of this error may be found in the large number of papers which have been written in recent years by German observers with the view of determining the cause of the heavy fœtal mortality which is associated with maternal albuminuria.* In almost every case the observations were made upon the macerated fœtus and its placenta, and no attempt was made to distinguish primary from secondary changes. In this way a great deal of careful work has been invalidated.

This paper is not concerned at all with the group of primary changes, which belong to a different category, and should be studied separately from the secondary group. We have only to attempt to describe those changes which appear to result directly from the death of the fœtus, *i. e.* from the arrest of the circulation through the chorionic villi. The subject possesses both a scientific and a forensic interest, and deserves more attention than is usually given to it.

When the fœtus perishes, unless uterine action immediately ensue, the placenta remains attached to the uterine wall, and the maternal circulation through the

* Wiedow, "Ueber dem Zusammenhang zwischen Albuminurie und Placentarerkrankungen," 'Zeit. für Geburts. und Gynäk.,' 1888; Cohn, "Ueber das Absterben des Fœtus bei Nephritis der Mütter," 'Zeit. für Geburts. und Gynak.,' 1888; Von Franqué, "Klinische und pathologische Beobachtungen über Placentarerkrankungen," 'Zeit. für Geburts. und Gynäk.,' 1894.

intervillous spaces continues, although the fœtal circulation through the villi has ceased. The anomalous position results that the fœtal placental elements (villi), although technically dead, remain in contact with their normal source of nutrition, the maternal blood, and are thus preserved from decay. They are in fact embalmed, and may be preserved from post-mortem changes to an

FIG. 1.

× 130. Eight months' placenta, retained two to three weeks. Shows a part of the placenta from which the maternal circulation has not been cut off. There is fresh blood in the intervillous spaces, and some of the villi show blood-containing capillaries.

extent and for a period that is at first surprising. Thus, in a placenta which has been retained for some weeks, areas of villi may be found which can scarcely be distinguished from those of a living placenta; there is a complete absence of necrosis in these villi, their tissues show the normal staining reactions, and histological detail remains good (Fig. 1).

Although the villi are thus preserved for long periods from decay, it is important to remark that there is no evidence of recent growth or multiplication. It will be remembered that in the early months of gestation the villi show abundant activity; they multiply freely by budding, and all the different steps of the process may be traced. In the retained placenta these buds may be so well preserved that they have sometimes been mistaken for recent growths which have developed after the death of the ovum. That this is not so is proved, however, by the equally fresh condition of the villi to which they are attached.

The doctrine which has been advanced in connection with recent discussions upon the ætiology of so-called deciduoma malignum, that retained chorionic elements may proliferate after the death of the fœtus, obtains no support from the study of the retained placenta.

The condition of the extra-placental tissues forms a marked contrast to that of the placenta. The membranes, the cord, and the tissues of the fœtus itself, necrose with some rapidity, because there is nothing to preserve them from the usual fate of dead organic structures.

Where the maternal circulation through the intervillous spaces is maintained, no marked change occurs in the placental villi. But gradually that circulation is arrested, and as the villi become cut off from the maternal blood they perish. We have to trace (1) *the arrest of the maternal circulation*, (2) *the changes which result in the villi*, (3) *the changes in the decidua serotina*, (4) *the changes in the extra-placental tissues.*

(1) *The arrest of the maternal circulation* occurs by a process similar to that described in connection with the formation of white infarcts in the living placenta, *i. e.* by obliteration of the intervillous spaces by deposition of fibrin and clotting. The primary change in the process of infarction is probably a gradual arrest of the fœtal circulation, by obliterating endarteritis affecting the medium-sized and smaller arterioles. I have never been

able to convince myself that arterial changes ever occur after the death of the fœtus, although the assertion has been made that such is the case by a recent observer, Merttens.*

The writer describes a form of obliterating endarteritis in retained placentæ which he believes to be different in character from that which is found in the living organ, and therefore regards it as occurring subsequent to the death of the fœtus. Merttens asserts that arterial obliteration in the living placenta is always due to periarteritis, and never to proliferation of the intima; while in the retained placenta proliferation of the intima is the usual method by which obliteration occurs. But it has been shown in the first part of this paper that endarteritis, or proliferation of the intima, does occur in the living placenta, and in precisely the same vessels as those in which Merttens has found it in retained placentæ, viz. the medium-sized and smaller arterioles. It seems probable, therefore, that the latter has been led by the apparent freshness of the tissues into regarding as a recent process a change which in reality occurred during the life of the fœtus, *i. e.* he has mistaken a primary for a secondary change. In any case it is necessary to examine with great care all evidence adduced in support of the doctrine that a vital process such as cell proliferation may occur in fœtal tissues after the fœtus itself has perished.

The obliteration of the intervillous spaces in the retained placenta appears to be due rather to progressive failure of the maternal circulation from shrinking of the uterus, and loss of the stimulus of the growing ovum, than to fœtal arterial changes. The maternal blood, in consequence, clots more readily and deposits fibrin more freely than in the living placenta (Fig. 2). The process occurs in both cases in the same localities, spreading from previous deposits as foci. The intervillous spaces are therefore first obliterated around infarcts, wherever they lie, and

* "Ueber Obliteration foetaler Gefässe in retinirten Placenten," 'Zeits. für Geburts. und Gynäk.,' 1894.

upon the fœtal and maternal surfaces of the placenta, In this manner a retained placenta becomes in time extensively consolidated, and its tissues bear macroscopic characters closely allied to those of infarcts, and differing widely from those of spongy placental tissue.

A striking illustration of the change is often furnished by cases of fœtus compressus, in which one of twins has perished *in utero*, but has been retained along with its placenta until the birth of the survivor. The placenta of the macerated fœtus offers the most striking contrast to that of the living child; it is consolidated throughout, its tissues are anæmic and degenerating, and there may be found remaining no trace whatever of spongy tissue. The most complete examples of consolidation ever met with occur in these cases.

It is a point of some importance to trace the fate of the fibrin and blood-clot thrown down in the intervillous spaces. The statement has been frequently made that a new formation of fibrous tissue occurs in the retained placenta, but no satisfactory microscopic evidence has, so far as I can find, ever been offered in support of it. Fothergill,* in a recent paper, has expressed the belief that the blood-clot deposited in retained placentæ does become organised, and suggests that it is possible to estimate the period which has elapsed since the death of the fœtus, by the degree of organisation of the connective tissue around the villi. I have not, however, succeeded in finding any true connective-tissue formation in any of my specimens. The blood-clot often contains large numbers of leucocytes, and in the case of large clots the outer layers may be composed of stratified fibrin, but this appearance is readily distinguished from connective tissue. Occasionally a few ill-shaped spindle-cells may be found, but I have never been able to detect the formative cells characteristic of young connective tissue, nor

* "Placental Tissue, Fresh and Old," 'Brit. Med. Journ.,' 1896, vol. i, p. 1141.

any trace of new formation of blood-vessels. Fothergill's illustrations certainly show the presence of spindle-cells and fibrils around atrophied villi; but he does not allude to the new formation of blood-vessels in this "connective tissue," and it is therefore to be presumed that none were found. Without vascularisation there can of course be no true formation of connective tissue at all, and I am inclined to believe that none occurs.

On the contrary, the blood-clot, after undergoing the usual contraction, is rapidly overtaken by necrotic changes. The leucocytes break up, and their nuclei crumble into débris; all traces of the red cells disappear, and finally the fibrin reticulum also disintegrates.

As has been pointed out, the process of obliteration of

FIG. 2.



× 90. Five months' placenta, retained about eight weeks. Shows obliteration of the intervillous spaces by thrombosis. The villi around the large blood-clot in the middle of the photograph are in an advanced stage of atrophy.

the intervillous spaces does not proceed regularly throughout the placenta, but spreads from infarcts and previous fibrin deposits as foci. The organ, therefore, becomes irregularly consolidated, and the rate at which the process advances appears to vary considerably. As a rule, however, the placentæ which have been longest retained are most consolidated.

In the case of an extensively consolidated retained placenta it is obvious that there is little risk of mistaking primary for secondary changes; the greater part of the consolidation is of course secondary, because even a moderate amount of it must be incompatible with the continued existence of the fœtus, *i. e.* the physiological boundary line has been widely overstepped.

In the spongy areas of a retained placenta the villi can only with difficulty be distinguished from those of a living placenta of the same period. Their form and structure are perfectly retained, their capillaries are full of blood, and around them are traces of the blood which has circulated through the maternal spaces (see Fig. 1).

(2) *The changes which result in the villi* are practically the same as those which are found in the middle and inner zones of large infarcts in the living placenta. The conditions are identical in the two cases, *i. e.* the fœtal circulation through the villi, and the maternal circulation around them, are definitely arrested. In both cases the villi undergo atrophy and necrosis, losing first their epithelial covering, then their connective-tissue stroma and blood-vessels, and finally their nuclei. They are then represented in a stained section by pale structureless areas, having the general contour of villi, but possessing none of their structural characteristics, and surrounded by masses of fibrin and blood-clot (Fig. 4).

In addition to these changes, large areas of the placenta may become consolidated by the process of non-fibrinous infarction (Fig. 3).

Extensive fatty degeneration usually occurs in all the consolidated areas; the largest fat deposits ever found in

the placenta occur in these cases. Calcareous deposits are also abundant.

FIG. 3.

× 130. Another portion of the same placenta as Fig. 1. Shows a part of the placenta from which the maternal circulation has been cut off. The villi are closely packed together, obliterating the intervillous spaces; most of them have lost their epithelial covering, the stroma is degenerating, and the capillaries have entirely disappeared.

(3) *Changes in the decidua serotina.*—The most frequent cause of the death of the ovum in the earlier months of gestation appears to be some pathological condition of the decidua. Considerable caution must, therefore, be exercised in these cases, in distinguishing between primary and secondary decidual changes. In the case of the mature placenta the difficulty is not so great, as primary changes are less likely to be met with in the latter half of gestation. The following remarks apply only to retained placenta of the fifth month or later.

The compact layer is generally fused with a superjacent stratum consisting of several rows of villi embedded in

fibrin and blood-clot. It is this stratum which gives the characteristic yellow colour to the uterine surface of a

FIG. 4.

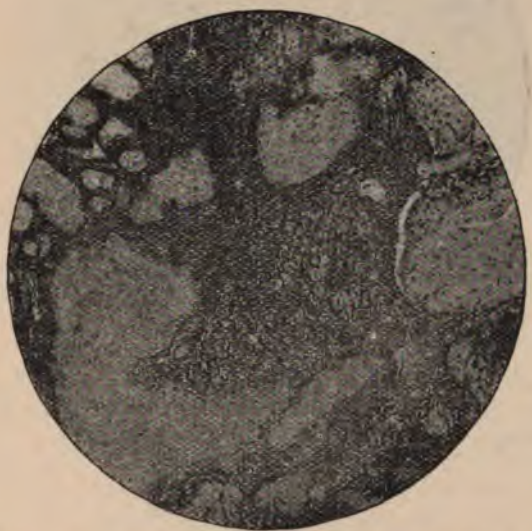

× 70. Four months' placenta, probably retained for twelve weeks. Shows extensive obliteration of intervillous spaces by dense masses of retracted fibrin (from old blood-clot); a few leucocytes persist in the meshes. The stroma and epithelial covering of most of the villi have entirely disappeared; on the right of the figure the changes are less advanced.

retained placenta. The structure of the compact layer itself is barely recognisable, so far has the process of fibrinous degeneration and disappearance of the decidual cells proceeded. This process, as already stated, commences during life, but proceeds apace after the death of the fœtus. The spongy layer, as a rule, is much less altered than the compact layer. It is generally thinned and atrophied, but the characteristic decidual cells are distinct, and the vessels often full of blood. Sometimes the walls of the latter are a good deal thickened by hyaline degeneration. The process of fibrinous degeneration never affects this layer

FIG. 5.

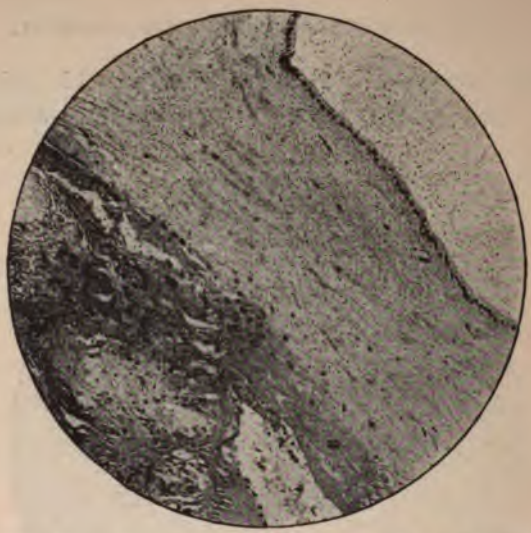

× 90. From the same specimen as Figs. 1 and 2. Vertical section through the membranes at the placental margin; the tissues are well preserved.

FIG. 6.

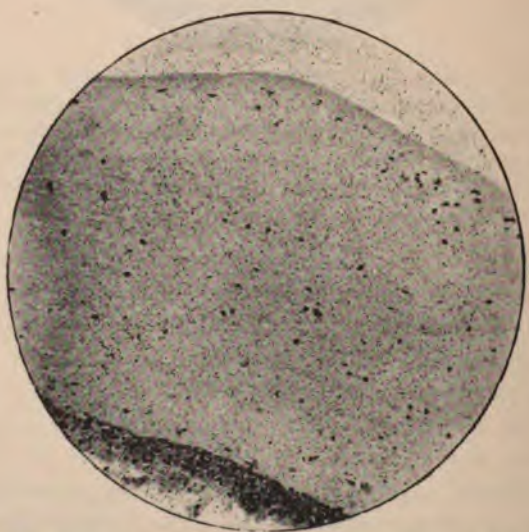

× 120. From the same specimen. Section through the membranes about one inch outside the placental margin. The amniotic epithelium has disappeared, and is represented by a thin structureless band. The remaining tissues are necrosed.

except to a very slight degree. This point is seen to be of some importance when it is remembered that any process tending to consolidate this stratum would inevitably render separation of the placenta difficult when uterine action occurs. As it is, there is nothing in the condition of the serotina which can hinder in any way the natural process of shedding.

(4) *Changes in the membranes.—Amnion.*—This membrane always necroses, although not rapidly, after the death of the fœtus. The delicate sub-epithelial tissue is first lost, and later the epithelium. Over the placenta the changes proceed much less rapidly than over the extra-placental chorion. The epithelium disappears in patches, and in a placenta retained for some weeks, small areas of more or less altered cells are met with alternating with wide stretches in which no trace of epithelium remains, but a thin structureless band (Figs. 5 and 6).

Extra-placental chorion and decidua vera.—These membranes necrose in all cases, but not so rapidly as the amnion. They are preserved the longest in the neighbourhood of the placental margin, and perish soonest in the parts most distant from it. The decidua retains traces of structure longer than the chorion.

III. *Conclusion.*

The changes in a retained ovum which follow the death of the fœtus may be summed up as follows:

1. Necrosis of the following structures, commencing immediately upon the death of the fœtus:

(*a*) The body of the fœtus.

(*b*) The umbilical cord.

(*c*) The amnion.

(*d*) The extra-placental chorion and decidua vera.

2. Gradual arrest of the maternal circulation through the placenta by thrombosis of the intervillous spaces.

3. Necrosis of the various branches of the placental chorion as they become shut off from the maternal blood.

4. Fatty and calcareous degeneration of the necrosing tissues.

Dr. Peter Horrocks asked if the author's observations had led him to any conclusion with regard to the manner in which the placenta received its nutrition. With the exception of the yelk in the ovum, which supplied a certain amount of nutrition, it was quite obvious that the source of the growth of the child and its coverings, including the placenta, was the maternal blood. But considering the intimate union between the villi of the chorion and the maternal tissues, was it not possible that the maternal blood might supply the necessary food directly? That is to say, instead of the requisite foodstuffs being absorbed into the fœtal blood and then circulated through the placenta for its nutrition, was it not possible for the placental tissue to take up what it required for its own growth directly from the maternal blood? And even if this were not its usual mode of growth, might it not occur sometimes? He asked these questions because, from a clinical point of view, it had always seemed to him possible for the placenta to grow after the death of the embryo. It was a well-known fact that it did so when undergoing the pathological change called hydatidiform degeneration. Here the embryo died, and yet the villi of the chorion grew and multiplied so as to attain an enormous bulk, all the food for which must come from the maternal blood. Another fact was that frequently one saw a miscarriage where the placenta was relatively much larger than corresponded with the size of the embryo. The amnial sac might be very small, and the embryo quite tiny or even invisible, and yet the placenta might be a considerable size. Obviously in such a case either the placenta had continued to grow after the death of the embryo, or the embryo had diminished in size after attaining to a certain development, which was not at all likely. If the denudation of the villi of their epithelium, shown in the section, was a physiological process and not an accident in the preparation of the slides, it was evident that the maternal and fœtal bloods were brought into the closest proximity. The question whether they actually mixed in the placenta had been discussed for generations; but none of the sections shown to-night exhibited any mixture, and he thought that clinical evidence could be brought to strongly support, if not to absolutely prove, the view that the maternal and fœtal bloods never did intermingle.

Dr. Amand Routh inquired whether the author meant to imply that the degenerative changes in the full-term placenta facilitated its detachment during the third stage of labour. If so, how did he explain the similarly easy detachment when labour was induced at an earlier period? Dr. A. Routh also

asked if the author would lay it down as an absolute rule that blood, extravasated into the placental structure, *never* became organised. Did it not become organised in apoplectic ova and fleshy moles? As regards the difficulty of determining the length of time during which a piece of placenta had remained *in utero*, he narrated the case of a woman whom he had seen with Dr. Murphy of Twickenham. The patient had had a child two years previously, and stated that she had been regular afterwards till six months ago, when she began to have irregular, frequently recurring hæmorrhages, amounting sometimes to "floodings." She denied the possibility of having been pregnant since the confinement above mentioned, as her husband had been away. The uterus was rapidly dilated, being still partly patent, and a piece of placenta, exactly resembling recent full-term placental tissue, was removed. It probably dated from a confinement six months previous or later, but according to the woman's statement had been *in utero* two years, causing no symptoms for the first eighteen months. Under the circumstances they declined to express a definite opinion.

Dr. Dakin asked if the author considered the presence of simple cysts in the placenta at term to be an abnormality. Cysts were not very uncommon, occurring always, in Dr. Dakin's experience, in the middle of firm masses resembling those Dr. Eden had described as infarcts, and containing clear or turbid serum, or in a few instances blood-clot in various stages of disintegration. Such cysts were found in the placentæ of quite healthy fœtuses.

Mr. Bellamy Gardiner said that an interesting clinical fact bearing upon Dr. Eden's demonstration of the vascular degeneration of the placenta at full term was shown by the absence of appreciable effect upon the child from the anæsthetic inhaled by the mother during parturition. It was a curious coincidence that in lately investigating this subject he had only come across one definite instance of anæsthesia in the fœtus produced in such a manner; that case was related by Mr. Lawson Tait in the 'British Medical Journal' for November 27th, 1880, in these words:—"In operating upon a case of extra-uterine fœtation where the child was living, we found it profoundly narcotised, and its breath smelt strongly of ether for some hours." The abnormal position and formation of the placenta in such cases might have some influence upon the result.

Dr. Eden said that it was always important that histological work should be reviewed from the standpoint of clinical experience, and he was therefore glad of the criticisms which had been passed by Fellows taking this point of view. In reply to Dr. Horrocks, he said that the case of the vesicular mole was so peculiar that no conclusions could be drawn from it regarding the normal chorion. Without actual demonstration of the fact,

we ought not to adopt the view that normal villi might develop or proliferate after the death of the fœtus. Up to the present time no satisfactory anatomical evidence of such growth had ever been advanced. Some years ago the statement was freely made that the extra-uterine placenta continued to grow after the death of the fœtus, but it had since been proved that the increase in size of the placenta observed in this condition was due not to growth, but to hæmorrhage into its substance. The instances of discrepancy between the size of the fœtus and that of the placenta might have been due to placental hypertrophy, or distension of the ovum by hydramnion, and no conclusions could be drawn from such cases. Dr. Griffith had raised the question whether the degenerative changes described exerted any marked influence upon the functional capacity of the placenta. He believed they did not, for the extent of these changes was usually very small in comparison with the total placental area, and probably ample spongy tissue remained to provide for the nutrition of the fœtus. At the same time their extent varied very considerably in different cases, and at times the boundary line might be overstepped, and the working capacity of the organ impaired. With regard to the cavernous layer of the serotina, he intended only to emphasise the importance of the absence of fibrinous degeneration in this layer, as any such process tending to its consolidation would cause difficulty in the separation of the placenta in the third stage of labour. In reply to Dr. Amand Routh, he believed that the statement so often made, that in the uterine mole the blood became organised into connective tissue, did not rest upon anatomical evidence, and he had failed to discover any trace of the process in his specimens. The clot retracted into firm masses, but there was no connective-tissue formation, and no trace of the development of new blood-vessels.

DECEMBER 2ND, 1896.

F. H. CHAMPNEYS, M.A., M.D., President, in the Chair.

Present—45 Fellows and 1 visitor.

Books were presented by Dr. Barbour, the Viscount de Saboia, Mr. Doran, the Edinburgh Medical Society, British Balneological and Climatological Society, and the Société de Médecine of Rouen.

Guthrie Rankin, M.D.Glas., was admitted a Fellow of the Society.

The following gentlemen were proposed for election :—Llewellyn C. P. Phillips, M.A., M.B., B.C.(Cantab.) ; William Gladstone Clark, M.A.(Cantab.) ; J. D. Rawlings, M.B.(Lond.) ; and Evan Laming Evans, M.B., B.C. (Cantab.).

The President nominated Messrs. Targett, Dawson, and Dr. Fairweather as Auditors for the year.

A TUBO-OVARIAN ABSCESS.

Shown by WALTER TATE, M.D.

October 7th, 1896.

THE specimen was removed from a patient aged 47, who had suffered from three attacks of pelvic inflammation, the last having occurred five years previous to her admission to St. Thomas's Hospital. For the last two years she had suffered from severe and increasing menorrhagia and pain in the left side. On examination there was a fibromyoma as large as an orange growing in the anterior wall of the uterus, and a second pedunculated tumour was found in connection with the left upper angle of the uterus. Abdominal section was performed on September 11th, 1896, and the latter swelling was seen to consist of the left Fallopian tube distended with pus, and connected by a small ulcerated opening with a cystic swelling measuring $3\frac{1}{2} \times 2 \times 2$ inches. The wall of this latter was seen to consist of ovarian tissue. Both the tube and cyst contained non-offensive pus. The appendages of the right side were also removed in order to arrest the growth of the fibro-myoma.

A committee, consisting of Mr. Bland Sutton, Dr. Roberts, and Dr. Tate, was appointed to report on the specimen.

Report on Dr. Walter Tate's specimen of tubo-ovarian abscess.

From the naked-eye character the specimen consists of two distinct parts,—a narrower tubal portion, which communicates with a larger cystic portion, the walls of which on microscopic examination present corpora lutea.

We are of opinion that the specimen is a tubo-ovarian abscess.

C. HUBERT ROBERTS.
J. BLAND SUTTON.
WALTER W. H. TATE.

NOTES OF A CASE OF PRIMARY EPITHELIOMA OF VAGINA.

By C. Hubert Roberts, M.D., F.R.C.S., M.R.C.P.

I venture to bring this case before the notice of the Society, as it is a somewhat rare form of disease. It occurred in a patient of mine at the Samaritan Hospital, who was admitted on October 3rd this year (1896).

E. N—, single, aged 38. History of present trouble :—In April, 1896 (six months ago), she first noticed a yellow thin discharge; there was then no bleeding. For the last two to three months the discharge has been watery, tinged with blood, and foul. It has of late been continuous but not excessive, necessitating no use of pads. She states that she has lost flesh. She has had slight pelvic pain in the back for two months. There was no syphilitic history. She came to the out-patient room of Dr. Tate in September, but could not come into hospital then.

On admission, October 3rd, a very curious condition was discovered on vaginal examination. On the posterior vaginal wall, about the middle third, was a raised rounded patch of ulceration about the size of a half-crown piece; its surface was of a dusky reddish colour, readily bleeding on the slightest touch. The surface was friable, but the deeper portions of the raised patch were quite firm and hard. There was some fœtor; the margins of the patch of ulceration were raised and somewhat everted, quite hard, and different from the surrounding vaginal wall, resembling exactly cases of vulval epithelioma. The ulcer was not exactly fixed, and moved freely on the subjacent rectal wall; the bowel was quite healthy. The lower third of vagina below the ulcer seemed normal, but above the ulcer towards the cervix there was some thickening like the leucoplakia seen in cancer of the tongue and mouth; laterally, except to the left of the

ulcer, the vagina seemed healthy. The inguinal glands were not involved. She was seen by my colleagues in consultation, and all diagnosed the case as one of primary cancer (probably epithelioma) of the vagina, and advised its removal.

I operated on her on October 12th. Great difficulty was experienced in exposing the growth, as the vagina was very small, and necessitated partial division of the perinæum. I excised the growth with a free margin of a quarter of an inch of what seemed healthy vagina, dissecting it off the rectal septum with the same difficulty, though there was no infiltration of the bowel. I think I got all the growth away satisfactorily, except, perhaps, at upper and left side. The vaginal wound could then be easily closed with silver sutures. There was not any severe hæmorrhage.

Subsequently the patient has done perfectly well, and the vaginal wound healed in a week, when the stitches were removed.

The growth after removal appeared to be a flattened epithelioma, and I had got well below the growth, and was clear laterally except at the part mentioned.

Microscopical examination proved the case to be a squamous epithelioma. Mr. Targett kindly examined a piece, and reports that "it is a very typical squamous-celled epithelioma, with a few cell-nests and much inflammatory infiltration around." Mr. Targett kindly sent me some sections.

Remarks.—Primary malignant disease of the vagina is very rare. Generally the cases of malignant disease that are met with result from extension from the cervix or vulva.

Primary malignant disease probably occurs about once in 5000 cases (Martin).

Distinctive forms met with are—

1. The papillary epithelioma.

2. The infiltrating epithelioma, generally in old women.

3. Sarcoma { Diffuse.
Circumscribed.
Sarcomatous degeneration of fibroid.

Epithelioma appears to be met with mostly in middle life (my case was æt. 38). Küstner ('Arch. f. Gyn.,' 1876, vol. ix, p. 279), who collected twenty-four cases, found that twenty occurred in women from thirty to forty, two in women from fifteen to twenty, two between twenty and thirty. Guersant reports a case in a child three and a half, Johannowski in a child of nine. Hegar reports a case due to ulceration of a pessary.

Epithelioma of the papillary variety usually commences on the posterior vaginal wall as an excrescence with a large base, that first of all invades the cul-de-sac, and afterwards extends downwards towards the vulva. Pozzi says it may start in plaques of chronic vaginitis.

The infiltrating variety, of which I have seen one case, commences over a large area of islands which rapidly become confluent. Another form seems particularly to affect the region of the urethra and anterior vaginal wall. These infiltrating forms soon block up the whole vaginal canal with dense, hard masses of cancerous material, causing complete atresia. Ulceration soon sets in.

Sarcoma appears as—

1. Diffuse sarcoma, developing later into papillary masses. Such cases seem to occur in quite young children from two to five years of age.

2. Fibro-sarcoma or sarcomatous changes occurring in vaginal fibroids.

3. Melanotic sarcoma as part of a general infiltration.

The course of cancer of vagina is usually a rapid one except in fibro-sarcoma. Extension takes place rapidly both in the surrounding tissues and lymphatics.

The symptoms are the same as cancer of the cervix,—foul discharge, hæmorrhage, pain, generally very late, and trouble with the bladder and rectum.

The diagnosis is generally easy from simple ulceration,

e. g. that due to pessaries; perhaps more difficult from cases of senile atrophic vaginitis. Tertiary syphilis of the vagina may be thought of. "Rodent ulcer" is described by Browicz ('Central. f. Gyn.,' 1887).

As regards treatment, extirpation in certain cases should be attempted, but according to statistics there seems little chance of any permanent benefit. The laxity of the vaginal walls allows of even extensive wounds being closed. Even opening the recto-vaginal septum is not contra-indicated. If the bladder be involved I fancy the case had better be left alone. Scraping, the use of actual cautery, careful antiseptic injections, iodoform tampons, are all the means possible in hopeless cases.

It is noteworthy that in the microscopical sections cell-nests are well seen, possibly pointing to the analogy of the vagina with true skin.

Dr. Lewers said he should like to say a word or two in regard to the treatment of cases such as that just narrated. He had seen a good many cases of primary cancer of the vagina, but had never seen one that seemed likely to obtain any benefit from operative treatment. Unless the whole diseased tissue, and a margin of healthy tissue round the morbid area, could be removed, there was no prospect even of a considerable interval without recurrence, still less of any permanent benefit. If he followed the notes of the case just read rightly the whole of the diseased tissue had not been removed. Operative treatment had always seemed to him useless in similar cases.

A CAST FROM THE UTERUS HAVING ALL THE CHARACTERS OF THE DECIDUAL MEMBRANE FOUND IN CONNECTION WITH ECTOPIC GESTATION, TOGETHER WITH A SMALL OVARIAN CYST FROM THE SAME CASE, WITH MICROSCOPIC SECTIONS OF EACH.

Shown by W. R. Dakin, M.D.

The history of the case from which the specimens were obtained was as follows.

The patient had menstruated regularly up to May of the present year, and the flow began on the 17th, being of the type natural to her. She did not lose again till June 27th, when she lost a little blood, the discharge being, however, mainly brownish in colour. It lasted three days, when she passed the cast shown, and then it ceased. She had had a good deal of abdominal pain of a dull kind with occasional paroxysms during all the fortnight or so before the cast appeared, but there was not much increase of this at the time of the expulsion.

Her age was twenty-seven. She had been married a little over two years. She had had a still-born child in South Africa in January of the previous year, and when first seen in August, 1895, she was suffering from subinvolution, with general pelvic tenderness, and some thickening of the tissues in the position of the right ovary. She was very anæmic from the menorrhagia which was present. Under treatment by ergot and iron, the menorrhagia and anæmia quite, and the subinvolution almost, disappeared. In October she was well except for some tenderness in the right posterior quarter of the pelvis, and a slightly bulky condition of the uterus. The patient at the time of the passage of the cast was in the

country, and her husband brought up the specimen on the following morning. It appeared to be a complete lining of the uterine body, and had a triangular shape when it was arranged in the position which it must have occupied in the uterus. It was split up the two sides very exactly, and when it was opened the two halves hinged on the fundal part. When placed in its natural position it measured $3\frac{1}{2}$ inches along the sides, and $1\frac{5}{8}$ inches across the base of the triangle representing the uterine cavity. It had an average thickness of $\frac{3}{16}$ inch. Its attached surface was very shaggy, its free one smooth, with two or three small polypi, the size of large pins' heads, hanging from it by pedicles, one of which was about $\frac{1}{8}$ inch long. There was no sign of the implantation of an ovum. It was obviously a cast of the endometrium, and since the history agreed well with the diagnosis of ectopic gestation, that idea appeared the most likely explanation.

She was brought to London next day. On abdominal examination she was found to have tenderness in both ovarian regions, and a mass—the fundus uteri—was felt behind the pubes, rising just above the pelvic brim. Bimanually the uterus was found to be enlarged to twice its usual size, and was freely moveable. The left side of the pelvis was normal, except for some tenderness and slight resistance. In the right side of the pelvis there was a lump as large as a hen's egg, freely moveable, and not very tender, which seemed to correspond to the outer third of the tube; and the inner part of the tube could be distinctly traced to this lump from the right cornu. There was serum in both breasts. On microscopic examination the cast was found to be decidual in character. It now appeared almost certain that the tube was occupied by an ovum. Dr. Dakin had the advantage of a consultation with the President, who agreed that that was the most probable explanation of the state of affairs, and that the right treatment was to open the abdomen.

This was done next morning. The lump was easily

found and carefully brought to the surface. It, and the portion of broad ligament and tube adjacent to it, were removed, the rest of the pelvic organs being found natural. The lump was found to consist of a thin-walled cyst containing clear fluid. The cyst appeared to be in the hilum of the ovary, and peeled out of the organ without difficulty. The following report was kindly made by Dr. Rolleston, who prepared the specimens shown under the microscopes :—" The *cyst* is lined with granulation tissue, which contains some blood-pigment, the remains of past hæmorrhage. More externally there is a layer of large cells, epithelial in character, and separated into columns by fibrous tissue. These cells are not unlike those of the supra-renal body or liver, and are perhaps relics of the Wolffian body. More externally there is a layer of fibrous tissue. The *cast* is composed of large cells with nuclei staining well, and resembling decidual cells. There are numerous spaces, probably blood-channels, and in places the remains of gland tubes."

Dr. Dakin recalled to the Society a specimen shown by Dr. Griffith, and recorded in vol. xxxvi of the 'Transactions.' In that case the passage of a cast similar in character to the one now shown was considered, even in the absence of any palpable swelling in the pelvis, to be sufficient ground for an abdominal section. At the operation the tubes and ovaries were found to be healthy.

The present case emphasised the fact that the passage of a decidual cast, or rather of a cast having the characters of a decidual cast, though, as a rule, very valuable evidence of pregnancy, was not to be absolutely relied on as proving the existence of an ovum in the genital passages of a woman, even though a swelling were found on one side of the uterus.

When the patient was last seen the uterus was of a quite natural size, and the pelvic organs were normal. She was now menstruating normally.

Dr. Griffith doubted if the cyst described as arising in the hilum had really this origin, for the microscopical section pre-

sented the typical characters of a cystic corpus luteum. His own case, with this one, opened up a question of the highest importance, to which at present no satisfactory explanation could be given.

AN ENTIRELY DETACHED UTERINE FIBROID.

Shown by Amand Routh, M.D.

Dr. Amand Routh showed this specimen, the size of a turkey's egg, which he had removed by laparotomy from a woman aged 50. She had ceased to menstruate for over two years. She had had severe pains in the pelvis for several months, with great tenderness over the abdomen, and some pyrexia.

The tumour was behind the uterus, apparently distinct from it, and in the absence of symptoms pointing to a fibroid, it was diagnosed as a dermoid.

At the operation it was found entirely separate from the uterus, lying amongst small intestines, to which it was loosely attached by vascular adhesions. The tumour was almost non-vascular, even when cut into, and was in an advanced state of calcareous degeneration. A scar on the fundus uteri showed where the fibroid had been attached.

MONSTROSITY RESULTING FROM AMNIOTIC ADHESION TO SKULL.

Shown by John Phillips, M.A., M.D.

A sub-committee, consisting of Drs. Giles, Roberts, and John Phillips, was appointed to examine and report on this specimen.

THREE CASES OF PORRO'S OPERATION, WITH INTRA-PERITONEAL TREATMENT OF THE STUMP.

By Herbert R. Spencer, M.D., B.S.

(Received August 10th, 1896.)

(*Abstract.*)

The author gives a full account, with charts and photographs, of the following three cases of Cæsarean hysterectomy.

Case 1.—A. D—, aged 28, no children, one abortion, after a protracted pregnancy (299 days from last menstruation) was operated upon in labour, which was absolutely obstructed by fibroids in the lower segment. The uterus removed weighed six pounds. Mother and child recovered and were quite well four years later; the former had gained twenty-one pounds in weight, and still had flushes occasionally. The sexual passion was lost for fourteen months after the operation, and then reappeared. The scar was quite sound and free from hernia.

Case 2.—H. G—, primipara, aged 21, was operated upon in labour, which was absolutely obstructed by a large sacral enchondroma. The patient was suffering from hydronephrosis and nephritis at the time of the operation, and died on the ninth day, apparently of uræmia. The child recovered. An account of the naked-eye and microscopic appearances of the tumour is given.

Case 3.—E. W—, aged 33, five children, was delivered of a living child through a cancerous cervix on March 25th, 1893.

The cervix was removed by the high amputation fifteen days later. Fourteen months later the patient became pregnant, and the fundus of the vagina became completely closed by cicatrix. Cæsarean hysterectomy was performed near term on March 6th, 1895, labour not having commenced. Mother and child recovered, and the patient was free from recurrence of the cancer and from hernia on April 30th, 1896, over three years after the supra-vaginal amputation of the cervix. The sexual passion was lost after the hysterectomy.

For simple cases of contracted pelvis the author prefers Cæsarean section to Cæsarean hysterectomy; he has performed the former operation also on three occasions, each time with success. He discusses the employment of Cæsarean hysterectomy in the cases now recorded, and directs attention to their chief features of interest.

Case I.—Protracted pregnancy (299 days from last day of last menstruation). Labour absolutely obstructed by fibroids of the lower segment of the uterus; Cæsarean hysterectomy (Porro's operation). Recovery of mother and child; both well four years later.

A. D—, aged 28 (children 0; abortion 1), married twelve months, was sent to me by my friend and colleague, Dr. Sidney Martin, on December 29th, 1890. She was a tall, well-made woman with a good colour, and had been in good health until June, 1890, when she had a miscarriage at three and a half months; subsequently she suffered a good deal of pain, being laid up for six weeks, bleeding nearly all the time. She had first menstruated at fourteen to fifteen, had always been regular, the bleeding lasting for seven days and requiring a dozen diapers. Since August, 1890, she has menstruated every four weeks for seven days, and used twenty diapers in all. It was on account of this increase in the loss that she came to me; she was otherwise in good health, but was a little weakened by the loss.

She had been told by Dr. Winterburn of Battersea that

she had a tumour, and had been in a hospital for women, where she was advised to have an operation performed.

The patient was found to be wearing a Hodge pessary. There was no tumour to be felt on abdominal examination. The uterus was in the normal position, slightly lengthened. At its posterior part was a mass of fibroids, somewhat irregular on the surface, which increased the uterus to twice its normal bulk. There was not much pain on examination, and the uterus was moveable. The patient was given an ergot mixture, with the result that from January until July, 1891, she felt quite well, and lost less than she had done since the miscarriage.

The local condition remained as before. On the 20th of July, 1891, the last menstruation ceased. At the end of the first week of August she had pain in the right ovarian region and across the back, with sickness. There was no discharge.

On August 31st I saw her. It was then six weeks since she had ceased menstruating, and she had never in her life gone a fortnight over her time except on the single occasion when she was pregnant. She occasionally had to get up at night to pass water during the last few weeks, but not often. The breasts were normal. The uterus could be felt on abdominal examination rising up to a height of 3¾ inches above the pubes, and by vaginal examination was found to be anteflexed, slightly irregular, and of the size of the organ at the third month of gestation. The cervix, situated far back, was fairly typical of early gestation. No projecting fibroid could be felt, though the front of the body was somewhat irregular and tender.

On October 28th the uterus reached up for nearly 2 inches above the umbilicus, 8¼ inches above the pubes. There was a small fibroid to be felt at the top of the uterus, and another on the left side of the body. The fœtus could not be distinctly felt. There was slight violet discoloration of the vagina. The cervix was quite typical of pregnancy. By the vagina a rounded tumour

of the size of a small orange was felt at the posterior part of the lower segment; it encroached a good deal on the pelvic cavity, and would prevent the head from entering the pelvis. It might possibly be pushed up during labour; if not, it would necessitate Cæsarean section.

The pelvic measurements were as follows:

Sp. il.	$10\frac{1}{4}$	inches.
Cr. il.	$11\frac{5}{8}$	„
Cong. ext. . . .	8	„

The promontory could not be felt.

The breasts were getting well developed, there was scarcely any pigmentation except on the tubercles; but the areolæ was otherwise typical of pregnancy.

At the end of November I had the advantage of a consultation with Dr. John Williams as to the advisability of inducing abortion, and it was decided to let the pregnancy go on until term; this conclusion was arrived at from considering the great rigidity of the cervix owing to the fibroids in its upper part, the great difficulty which would occur (and, indeed, did occur in the previous miscarriage) in delivering the ovum, and the possible prospect of the fibroids so far altering in consistence or in position as to allow a child to be born naturally at term.

On December 11th the uterus reached up to a point $9\frac{1}{2}$ inches above the pubes. There seemed to be a small fibroid set into the anterior wall of the uterus just above the pubes to the right of the middle line. The head was presenting, but the uterus was very difficult to examine.

Next day a small nodule was noted in the left hypochondrium, $11\frac{1}{2}$ inches above the pubes. There was a mass of fibroids, measuring about 2 inches across and 1 inch in thickness, overhanging the pelvic ilium on the right side and in front. There was a loud uterine souffle on the left side of the lower segment, also one less loud on the right side. The position of the child could not be made out.

January 15th, 1892.—Patient feels very well. For the last three or four months she has had pains like labour pains

regularly on the 28th of each month; for this she has taken fifteen drops of laudanum three or four times a day, with marked relief. (The pains recurred on the 28th of this month, but subsided under rest and the above medicine.)

22nd.—The uterus is broad, and reaches up to a point 11 inches above the pubes. The head (?) is below, not easily felt. The breech (?) is on the right side of the fundus. The placenta is apparently in front, but examination is very difficult.

February 1st.—The head is in the right hypochondrium, the breech in the left loin. The fibroid mass in the right side above the pubes measures 2 inches across. The uterus is very difficult to examine. *Per vaginam* there is a mass on the left side of the uterus as big as a small apple: it also passes like a collar behind the uterus; it is firm, fixed in the uterine wall, and would not allow the passage of the head. *Per rectum* the same thing is noticed, but not so well as *per vaginam*.

17th.—The examination of the abdomen is very difficult. The head appears to be high up on the left side, but it cannot be distinctly felt.

26th.—The uterus is very wide, measuring 11 inches across, and it rises up for twelve inches, vertically, above the pubes. From the pubes to the ensiform cartilage the measurement is 16½ inches. There is a fibroid on the right side of the lower segment rising above the brim and measuring 2½ inches vertically and 2¼ transversely. There is one pole of the fœtus (probably the head) in the right hypochondrium. There is another pole to be felt midway between the pubes and the umbilicus which feels like the breech; over this region the child can be felt fairly well in the middle line, and there seems to be no placenta there. The fœtal heart can be heard three inches to the right of the umbilicus, and seven inches above the pubes, in a position corresponding to that in which the child has been diagnosed to lie. A foot can be felt in the left corner of the uterus.

March 7th.—The child's head is in the right hypochondrium; the breech is unusually high up, 2 inches above the pubes. There appears to be no placenta in the middle line. The uterus is tilted a good deal to the right side, and the top of the fundus is 11½ inches above the pubes.

On March 14th the patient was admitted into University College Hospital, and the following note was taken by Dr. Williams:—"The uterus reaches up to within one inch of the ensiform cartilage, and to the costal cartilages on each side. There are no nodules to be felt anywhere except on the right side, where there is a thickening about 2 inches in diameter, situated about 1½ inches below the level of the umbilicus. Small parts are to be felt in the left hypochondrium, and another nodule is felt there which is probably some part of the small parts of the child. On the right side, about 4 inches to the right of the umbilicus and on a level with it, the hand comes down on some part of the child, but the outline of the child is not to be made out. The fœtal heart-sounds are distinctly made out at that point.

"On vaginal examination the cervix is in the normal position. In the brim of the pelvis on the right side a mass is felt; it extends like a collar round the cervix from the sacro-iliac synchondrosis on the right side to quite the end of the transverse diameter on the left."

On March 21st the fœtal head was felt in the right hypochondrium, being slightly overlapped by the edge of the costal cartilages, the breech high up, about 2 inches above the pubes, and to the left of the middle line, the back on the right side, the limbs on the left side of the body of the uterus. The fœtal heart-sounds (136) heard slightly above and about four inches to the right of the umbilicus. At this point there was a well-marked funic souffle. Two nodules were felt in the uterine wall, the one just described, and another somewhat larger, rising above the pelvic brim on the right side. Next day the funic souffle was still present, and remained for several

weeks; the child was lying much as before, but its head was somewhat lower in the abdomen.

On April 13th, at 5 a.m., slight pains occurred in the abdomen and back at intervals of about a quarter of an hour. At 8 a.m. they became somewhat more severe, but afterwards they gradually died away, and there was no "show."

On April 14th the nodule described under March 14th is much softer than before, and hardly to be defined. The mass felt by the vagina is very much softer, and the cervix patulous.

Very little change occurred during the next four weeks.

On May 13th labour set in early in the morning with dull intermittent aching pains in the lower part of the abdomen, and at 1 a.m. a pain more severe than the others caused the membranes to rupture. On vaginal examination the lower cervix was found to be very soft, the external os of the size of a shilling, but the internal os surrounded by a very irregular ridge of fibroid tissue, except posteriorly for about a finger's breadth.

At 9 a.m. the pains were strong, occurring every few minutes. Dr. Williams found the os about as big as a florin, a firm collar of fibroids around the cervix, and the internal os bounded by an irregular fibroid margin, except for a small space posteriorly. The finger could not reach any part of the child. It was clear that further dilatation would involve rupture of the lower segment, and that this would not render delivery possible. He decided that Cæsarean section should be performed, and kindly placed her under my care for that purpose.

May 14th, 1892, 11.30 a.m.—Operation with Listerian precautions including the spray, the patient being anæsthetised by nitrous oxide gas and ether, and being in good condition, but a little anæmic from her prolonged stay in the hospital.

When the patient was insensible the position of the child was easily made out; it was lying as before with its

head in the right hypochondrium, its breech halfway between the pubes and the umbilicus, and to the left of the middle line; a limb could be felt to the left side of the lower segment, the child's back to the right, the heart-sounds (140) 4 inches to the right of and 2 inches above the umbilicus. The fœtus could be fairly distinctly felt except in the middle line above and below the umbilicus; here the sensation was indefinite, and this region had somewhat the feel of the placental site as examined by the abdomen, but it was thought not to be due to the placenta on account of its shape, which was narrow and elongated.

An incision about 5 inches long was made through the abdominal wall in the middle line, four vessels being seized with forceps. No fluid and no adhesions in the peritoneum. The surface of the uterus was of the normal pale red colour, but scattered over it were white scar-like areas. The left broad ligament was found lying immediately to the left of the incision, so that the uterus was rotated for nearly a quarter of a circle. A second assistant now placed his hand on the abdomen under the child's head and pushed the uterus over to the left. An elongated vulcanite pessary (as suggested by Cameron) was now placed on the uterus in the middle line and firmly pressed down by the assistant; a vertical incision was then rapidly made within the pessary; violent hæmorrhage occurred; a second incision was made, and was followed by still further hæmorrhage, although the pessary was firmly pressed down. It was at once seen that a fibroid nearly as large as a hen's egg had been cut into, and that the hæmorrhage proceeded from the large surrounding sinuses. The fibroid was rapidly cut through, and it then bulged across the wound; on account of this and the hæmorrhage it was impossible to see to make an incision, so the two thumbs were employed to rupture the rest of the uterine wall. The operation so far had lasted but a few seconds, but the hæmorrhage was profuse and was not checked by the pessary, which

was discarded. Two fingers of my left hand having been passed into the uterus, the wound was enlarged upwards for 4½ inches by a blunt-pointed bistoury, my assistant meanwhile hooking his finger in the lower angle of the wound and partly controlling the flow from a large sinus. The hand was immediately thrust into the uterus and the head seized, but with all the force I could employ it was impossible to shift the head, which felt almost as if it was covered by a helmet formed by the fibrous uterus, so the right foot was seized and the child immediately extracted with ease. It breathed and cried at once.* The whole uterus (still bleeding) was then turned out of the abdomen and seized round the lower segment with the hands, the hæmorrhage being thus controlled. Sponges were placed in the abdomen, and blood wiped away. The uterus still showed no sign of contracting.

The bleeding was stopped by the pressure of the hands and by Wells forceps on a large sinus. After waiting for five minutes the placenta was removed by the hand, scarcely any blood being lost: during the removal the chorion tore. Sponges were now placed in the uterine cavity and the walls of the organ kept together by the hands of the assistant, and while waiting for the uterus to contract, a ligature was placed beneath the left ovary with a view to its removal. Large vessels of the size of the little finger rendered this difficult and dangerous, and it would have been impossible to remove the Fallopian tube on account of its extensive and short mesosalpinx. The uterus showed no sign of contracting, and after the removal of the sponges bleeding occurred to the extent of two or three ounces, but was checked by compression. After waiting for fifteen minutes—still no

* The child (a female) was not measured and weighed till next day. The following are the measurements then taken:—Weight 9½ lbs., with clothes on. Diameters of head:—Occipito-mental 5¾ inches; occipito-frontal 4¾ inches; cervico-bregmatic 4 inches; sub-occipito bregmatic 3⅞ inches; bi-parietal 3⅞ inches; bi-temporal 3¾ inches.

sign of contraction—as slight oozing continued, it was decided to remove the uterus, although the wire would have to be placed very low down on the cervix. It was further thought advisable to finish the operation, because the patient had an attack of syncope, from which she soon recovered on administering an enema of brandy and water. (She had for years suffered occasionally from fainting fits.) The serre-nœud was applied low down on the cervix and tightened, and the uterus and appendages removed by amputating the organ about 2½ inches above the wire, the peritoneum cleaned by sponges, the stump lessened by the excision of three fibroids of the size of hen's eggs, and the silk sutures applied to the abdominal wound, the one below and the one above the stump catching up the peritoneum of the stump below the wire and being tied before the others. No drainage-tube was employed. The wound was dressed with iodoform gauze and carbolic gauze. The total time of the operation until the dressing was applied was fifty-one minutes. The patient was in good condition at the end of the operation; the pulse was 92. Eight ounces of blood and clot were collected. She probably lost nearly twelve ounces in all.

The uterus removed weighed 5 lbs. 10 oz.; together with three fibroids excised from the stump and the stump itself it weighed almost exactly 6 lbs.

The length of the part removed was .	8¾ in.
Width ,, ,, .	7¾ in.
Thickness of the body removed .	5½ in.
,, ,, lower segment .	5¼ in.
,, ,, posterior wall of lower segment . .	3 in.
,, ,, wall at uterine incision	2½ in.

The length of the placenta (which was inserted on the posterior wall) was 7½ inches, the breadth 7½ inches, the thickness 1½ inch. The funis, inserted 2½ inches from one edge, measured 27 inches in length, and was straighter than usual.

The right Fallopian tube was $6\frac{1}{2}$ inches in length, the left $7\frac{1}{2}$ inches.

The right ovary measured . $2 \times 1\frac{1}{4} \times \frac{1}{2}$ in.
The left ,, ,, . $2\frac{1}{8} \times 1\frac{1}{4} \times \frac{3}{8}$ in.

The uterus was fairly regular in shape except for a prominent fibroid as big as a lemon in the right and anterior portion of the lower segment. There were two fibroids showing in the uterine incision, and nearly the whole of the inner surface of the organ was occupied by prominent fibroid growths of the size of walnuts, marbles, and peas.

At 3 p.m. the serre-nœud had to be tightened owing to oozing, and again at midnight the patient had to be dressed, owing to the oozing from the large and very vascular stump.

May 15th, 2 a.m.—Patient complained of pains in the region of the pedicle. ♏iij of hypodermic solution of morphia were injected. At 7 a.m. Liquor Ferri Perchloridi fortior was applied to two bleeding points on the stump. At 9 a.m. patient complained of severe pain as before; for this ♏iij of morphia solution were injected. No more morphia was given, as it was found that the pain was caused by dragging of the serre-nœud by the dressing, and on readjusting this the pains at once ceased.

At 11 a.m. the dressing had again to be changed, and consisted of iodoform gauze and wool. In spite of the almost continuous slight oozing the general condition has been good throughout. The pulse is regular, of fair tension, and usually ranges between 80 and 95. The patient was sick soon after the operation and three or four times last night, but has not been sick since early this morning. She took barley water at noon, peptones at 3 p.m., milk and barley water at 4 p.m.

Towards evening the pulse rose to 130, but the general condition remained good. At 5 p.m. the dressing was renewed, and turpentine applied to a bleeding point.

16th.—Patient slept well. Wound again dressed. Oozing checked by turpentine and sulphate of iron. Urine, ℥xv.

17th.—Flatus was passed *per anum* at 3 a.m. There is a scanty vaginal discharge tinged with blood. Part of stump removed with scissors. Oozing arrested with turpentine. Urine, ℥xix.

18th.—General condition good. Patient sleeps well; is taking bread and butter in addition to milk and peptones. Urine, ℥xx; sp. gr., 1036; abundant deposit of urates; acid, no albumen; no blood. 4 p.m.—Wound dressed; the skin is blistered on the left side of the pedicle (by the turpentine).

20th.—Dressings soaked through with slightly blood-stained discharge; a small piece of the stump removed by the knife; oozing (in spite of tightening of the serre-nœud and application of sulphate of iron) stopped by turpentine.

21st.—Bowels having been opened by aperient, all the stitches were removed. The wound has healed by the first intention, and there is neither redness, tenderness, nor pain. The abdomen has not been swollen in the least since the operation, but rather retracted. Patient is taking full diet from to-day.

25th.—There is some carbolic acid in the urine. The axillary temperature reached 101° to-night. On only one other occasion (May 27th, 101·4°) was this height reached during the month after the operation, and the temperature was taken every four hours.

26th.—Patient is dressed daily: a second serre-nœud is fixed on to the first, so as to permit further tightening of the wire; the stump is almost dry.

27th.—Stump quite dried.

June 7th.—The greater part of the pedicle was cut away with scissors, and the écraseur tightened. The stump is dry and perfectly sweet.

11th.—Mother and child in excellent condition, as they have been since the operation. This morning the wire

was found to have cut its way through, and was removed; but on cutting into the stump it was found to be vascular, and three small arterioles in it actually spurted. This vascularity was of course due to the union of the stump with the raw surface of the abdominal wound. The adhesion was separated by scissors, and the stump removed. An aperture was left measuring 1 inch by 1¼ inch. This was washed by sublimate solution, and dressed with boracic acid and iodoform gauze. A broad piece of plaster was applied around the belly.

July 5th.—The progress has been uninterrupted. There is a small raw surface about the size of a pin's head. Mother and child are well. Patient gets up.

9th.—The wound is perfectly healed. The finger introduced into the vagina passes up into a gradually contracting passage, and the cervix uteri cannot be easily reached. The patient (weighing 8 st. 6 lbs.) left the hospital to-day with her child (weight 14½ lbs.), both being in excellent health.

October 4th, 1892.—The patient looks and feels in perfect health, and the child weighs 21 lbs. with its clothes on. The mother still suckles her child, and has an abundance of milk, as she has had since the operation. There is neither swelling nor tenderness in the abdomen. The scar measures 3½ inches in length, and there is no hernia. The breasts are large and well developed; there is very little pigment in the areola. The patient has "hot flushes" occasionally. The vulva is apparently contracting, but is otherwise normal. There is a small aperture at the top of the vagina which feels like a small atrophied cervix. The stump at the top of the vagina is freely moveable, and there is no effusion. Patient has had no sexual desire and no sexual pleasure since the operation, which she always had before.

The patient was seen by me on May 15th, 1893, one year after the operation. She was in excellent health, and the scar quite sound. The infant also was very

flourishing, and weighed 25 lbs. The mother weighed 9 st. 2 lbs. in light summer clothing.

On May 22nd, 1894, I noticed several small round red patches (like those so common in elderly women) around the urethra and in the vestibule, and at the insertion of the hymen. The mother weighed (in a dressing-gown) 9 st. 5½ lbs., the infant 29 lbs.

On May 14th, 1895, I again saw the patient. She was in excellent health. The breasts were large, but with scarcely any pigment in the areola. There was about 1½ inches of fat on the abdominal wall. The scar was 3 inches long and quite sound. The orifice of the vagina had a whitish scar-like appearance, but the vagina was capacious with a little nodule at the top, the remains of the cervix. The patient has flushes about once a month during one day, but these do not trouble her. She weighed 9 st. 12 lbs. (in a dressing-gown), having gained 1 st. 6 lbs. since she left the hospital nearly three years ago.

On May 14th, 1896, I saw the mother and her child, both in blooming health. The former weighed 9 st. 13 lbs. in a dressing-gown, the latter weighed 36 lbs. The mother's breasts remained large and well developed, and the skin over the breasts was warm. There were a few red spots around the meatus urinarius; they were not tender. The vagina was moist and capacious. The remains of the cervix could be felt as a pea-like body, moveable, at the top of the vagina. The abdominal scar was 3 inches in length, and quite sound: there was no hernia. Flushes still occurred occasionally. She informed me that sexual pleasure, which was completely absent for fourteen months after the operation, returned after that period, and had continued ever since, though somewhat less marked than before the operation.

Case 2.—Labour absolutely obstructed by large sacral enchondroma; Porro's operation, with intra-peritoneal treatment of the stump; death of mother on ninth day; child living.

H. G—, primipara, aged 21, married, was sent to University College Hospital by Dr. G. A. Rountree, as a case requiring Cæsarean section, on April 16th, 1893. She last menstruated at the beginning of July, 1892. Labour pains (at term) came on about 7 a.m. on April 16th, and the patient called a midwife, who finding something wrong, sent for Dr. Rountree. When the patient was between three and four years old a horse kicked her on the pelvis. The mother thinks the tumour was noticed soon afterwards. Seven years ago the patient had retention of urine, which necessitated her admission into a hospital, and the passage of the catheter for three or four days. She remained in this hospital for six months, and was told she had a tumour by the obstetric physician and a surgeon who wished to operate upon her; but the mother would not allow this, and nothing was done. Since this time the abdomen has always been large, and the patient noticed a hard lump which caused her no pain, and which she said had not grown during the last seven years. There was no history of any acute illness, and no definite history of Bright's disease. She had suffered from morning headache, but there was no vomiting.

Micturition had been frequent (three or four times at night) as long as she could remember. She had only had retention on the occasion already mentioned. Defæcation was normal, the bowels being daily opened without pain.

Until her pregnancy the patient had menstruated regularly every four weeks, the period lasting five days usually, and requiring six diapers. There was some pain in the back during the first two days.

The patient's mother had a "tumour" removed from

her forehead when she was a young woman; she is still alive and well, and there is no other history of tumours in the family.

I saw the patient at 9.30 p.m. on April 16th, 1893. She was of small stature, but there was no obvious deformity. The general condition appeared good. The tongue was clean, the skin rather dry, the pulse 100, regular, of rather high tension. The urine contained a large quantity of albumen and some blood. Slight pains occurred every few minutes. The abdomen was as large as at the end of pregnancy, but of unusual shape, the uterus being longer and somewhat narrower than normal, and the abdominal tumour was curved in outline, the convexity being to the left. The uterus was difficult to examine. A hard mass above the pubes gave the impression of a hard fibroid about half as large again as a fœtal head. The fundus of the uterus lay slightly to the right of the middle line, and contained the breech of the child. The child's head appeared to merge into the mass above the pubes. [Under the anæsthetic it was clear that the right half of this mass was a hard tumour fixed to the pelvis, and that the head, of which the bones could be felt through the lower segment, lay to the left of this tumour.] The child's back was felt on the left side of the uterus; the fœtal heart-sounds were heard just to the left of the umbilicus at the rate of 152 to the minute, strong and regular. The placenta could not be felt. On examination by the vagina a large hard growth was felt occupying the cavity of the pelvis; it was fixed to the sacrum and the ischium, of stony hardness, nodulated on the surface, and appeared to be the tumour felt above the pubes. It projected forwards into the pelvic cavity, so that there was a space of less than an inch between the left side of the back of the pubes and the surface of the growth. The finger, introduced with difficulty, felt very high up the os uteri, of the size of a halfpenny, with a thin soft edge. There was a slight blood-stained discharge. The growth was found to lie behind the rectum

on examination *per anum*. It was evidently a cartilaginous or bony tumour of the pelvis. The patient having been shaved, and the vulva washed and douched with 1 in 500 sublimate solution, and the abdomen washed and covered with a towel soaked in 1 in 20 carbolic acid solution, was anæsthetised by gas and ether by Mr. Phear at 11 p.m. on Sunday, April 16th, 1893. Mr. Randall assisted me, and Mr. H. Ballance looked after the child.

At 11.5 p.m. an incision about 6 inches long was made from an inch above the umbilicus downwards. Three or four small vessels required clamping. Having opened the peritoneum the hand was introduced, and found the uterus almost mesially situated, the right broad ligament somewhat in front of the left, being apparently pushed forward by a hard, white, craggy tumour which grew up into the posterior part of the right broad ligament, and was immoveably fixed to the pelvis. The assistant pushed the uterus a little to the left, and an incision was rapidly made in the middle line of the uterus about 4½ inches long, during which pretty free but not serious bleeding occurred. Cuts were very rapidly made down to the membranes, which bulged at the top of the wound; the fingers introduced tore the remaining part of the muscular wall downward to the length of the superficial uterine incision without rupturing the membranes; the breech was seized and the child easily extracted, the membranes being ruptured at the same time. The exact time was not noted, but it was a matter of a few seconds from the commencement of the uterine incision to the delivery of the child and lifting the uterus out of the wound. Owing to this, although hæmorrhage was free, not much blood was lost. The assistant grasped the lower segment and controlled the oozing. The umbilical cord was clamped with forceps and cut, and the child* handed

* Measurement of child:—Weight 6¼ lbs.; length 19 inches; occipito-mental diameter 5¼ inches; occipito-frontal 5 inches; bi-parietal 3½ inches; bi-temporal 3⅛ inches; bi-mastoid 3 1/16 inches; cervico-bregmatic 4¼ inches; suboccipito-bregmatic 4 inches.

to Mr. Ballance. It was rather paler than new-born children usually are, but soon breathed and cried without any particular attention. The right side of the child's head was flattened by pressure against the pelvic tumour. It was decided to amputate the uterus, chiefly because it was feared that the bandaging would press the uterus against the growth (which formed a marked prominence above the pubes on the right side) and lead to gangrene and septicæmia. [The lower segment of the uterus had already been bruised between the child's head and the tumour.]

The uterus was therefore removed by placing the wire of the serre-nœud around the lower segment low down beneath the left, but above the right ovary, which it was impossible conveniently to include. The wound was closed, as in the former case, by deep thick silk sutures (eight in number) passing through the entire thickness of the abdominal wall, and by superficial silk sutures, and was dressed with iodoform gauze and carbolic gauze. No drainage was employed. The total duration of the operation till the dressing was applied was thirty-two minutes.

Mother and child were in good condition; the mother's pulse 100. She had lost only four or five ounces of blood.

April 17th.—The wound required dressing at 7 a.m., and at 11 a.m. on account of oozing. The patient was sick several times from the anæsthetic until 4 a.m., but not after. At 10.30 p.m. the wound was again dressed; the pulse was 120, the axillary temperature 100·4°, and the patient was rather restless, but had little pain. The urine was alkaline, dark-coloured, contained about one third of albumen and some blood. Barley water was given by the mouth at midnight, and milk and barley water at 3 a.m.

18th.—At 2 a.m. the breathing was 40 to the minute; there was pain at each side of the lower axillary region. There was no cyanosis. The pulse 140, regular, of high

tension. Relief was obtained after a dose of ammonium carbonate and spirits of chloroform. The patient slept for periods of twenty minutes at intervals, and for about an hour in the early morning. The stump was dressed in the afternoon, and iodoform applied to it.

19th.—The patient slept better last night, and took barley water and chicken broth. A piece of the stump was cut away to-day. Iodoform gauze was applied. The pulse was 108, regular and of lower tension.

20th.—Patient slept little last night owing to the troublesome cough; the wound was not dressed to-day. The patient passed two natural motions at 7 p.m., after which she complained of pain in the back. She took her food well. The axillary temperature rose to 102°, the highest temperature after the operation. The patient still has pain in the back.

21st.—The wound was dressed and a piece of the stump cut away. The pulse (134) is compressible. The patient is rather cyanosed; she is taking ʒj of brandy every hour.

22nd.—Pulse of very low tension, 140 to 150; resp. 44. Patient does not feel so well. Boric lint and salicylic wool substituted for the iodoform gauze. The tongue is dry, red at the edges and tip, and the dorsum covered with a thick white fur.

23rd.—Pulse 160, feeble, of low tension, irregular. Patient sleeps little in spite of bromide, and does not take the milk so well. She wandered slightly during the night, and passed urine once or twice under her; the urine contains blood and hyaline and granular casts. Numerous bubbling râles at the front base of each lung, especially the left (back of chest not examined).

24th.—The five upper deep stitches were removed; the wound had healed by first intention, but just above the stump, which was quite sweet, there was a little gaping. The patient was very restless, and became more and more feeble during the day; the hands and feet grew blue and cold, the face anxious, the forehead clammy. She wanted to get out of bed, and threw her legs about. She con-

tinued to take her food well. During the sixteen hours preceding death, only seven ounces of urine were secreted: this was drawn off by catheter. The patient became extremely restless, screaming and tossing about very wildly; she then became exhausted, and died at 3 a.m. on April 25th, on the ninth day after operation. The infant left the hospital in good health.

Autopsy eight hours after death.

The body measures 4 feet 10 inches. Pelvic measurements: sp. il., 9 inches; cr. il., 10¾ inches; conj. ext., 8 inches.

The stump measures 2½ inches across, and is black and dry. The wound has healed by the first intention except just above the stump, where it gapes a little, exposing the hard cartilaginous tumour. There is a little lymph on the surface of tumour in this situation, and on the remains of the left broad ligament, and on a coil of intestine adherent to this; but neither lymph, nor serum, nor pus, nor inflammation elsewhere in the peritoneum. The pelvis (exhibited) was removed entire, and shows a large tumour (see Fig. 1), measuring laterally 5½ inches and antero-posteriorly 4¾ inches, and rising 2¼ inches above the top of the iliac crests. It is somewhat uneven on the surface, and of the colour of fat. On its summit is a shallow depression, and here the contents may be fluid, but the tumour appears to be made of firm fibrous tissue, with masses of cartilage in it. The main bulk of the tumour, however, appears to be bony. The rectum passes obliquely down from the left side to the anterior part of the tumour. The tumour fills the cavity of the pelvis, a space being left between the tumour and the anterior pelvic wall, which at the brim is 1¾ inches wide in the middle line, but which, owing to the prominence of the tumour, measures only ¾ inch to the right of the middle line (see diagram, Fig. 3).

A median sagittal section of the pelvis (see Fig. 2) shows an irregularly oblong tumour rather wider above than below, measuring 7⅛ inches in length and 4¾ inches in thickness. It grows from the third, fourth, and fifth

FIG. 1.

Pelvis with several enchondroma, showing the relations of the tumour and the dilated ureters.

FIG. 2.

A sagittal section of the pelvis and tumour.

sacral vertebræ, the coccygeal bones, though closely applied to the lower end of the growth, not being implicated in it. At the upper end of the tumour is a fibrous capsule about

Fig 3.

Diagram (made carefully to measure, half-size) showing the relation of the tumour, rectum, uterus, and bladder at the pelvic brim in Case 2.

½ inch in thickness. The upper third of the tumour is generally of the appearance of fibrous tissue, but in places it looks more like cartilage, and at one spot there is a piece of bone. The lower two-thirds of the tumour is of a darker, apparently fibrous tissue, in the shape of a coarse network: in the meshes of this network is a soft reddish substance, which is found on microscopic examination to be coagulated mucoid material, on removal of which about a dozen cysts are seen, varying in size from that of a walnut downwards. These cysts have smooth walls, but no epithelial lining. Microscopic sections of the capsule and of the tumour itself show fibrillated hyaline substance, fibrous tissue, and in places myxomatous tissue. The hyaline substance contains round,

oval, and slit-like spaces in great abundance, and in places these spaces are occupied by one or more round cells, having a fairly characteristic appearance of cartilage cells, but the cells are throughout the whole of the tumour in very small numbers. In amongst the fibres of the fibrous tissue, and especially in the myxomatous parts, are a few branched cells, and a considerable number of cells resembling leucocytes. Many of the cell spaces in the hyaline portions are occupied by pigment and fat globules.

A microscopic section from the remaining sacral intervertebral disc showed appearances exactly similar to those in the tumour.

The *kidneys* were extremely pale, mottled, and very fatty on section. The calices (dilated) contained pus. The left kidney was small (3½ inches × 2 inches × 1 inch). Both ureters were dilated to the size of the end of the middle finger. Microscopic examination of the kidneys showed dilatation of the tubules, and consecutive chronic interstitial nephritis with fatty change in the tubular epithelium.

The bases of both *lungs* were consolidated and collapsed, the pleura over them a little inflamed. Microscopically these portions showed simple broncho-pneumonia with no indication of its having a septic origin.

The *left ventricle* was somewhat hypertrophied, and there was atheroma of the mitral valve.

The *liver* was normal.

The *spleen* had a normal appearance, and was small (4 inches × 2½ inches, weight 3 oz.): its consistence was firmer than normal.

Urine Sheet of Case 2.

Date.	Ounces in 24 hours	Colour.	Smell.	Reaction.	Sp. gr.	Urea grains per diem.	Albumen.	Deposits.	Casts.
April 17	10 (12 hours)	...	...	...	...	...	$\frac{1}{3}$	Blood	...
„ 18	34	...	...	...	...	197·54	$\frac{3}{8}$	„	Granular and hyaline.
„ 19	54½	Light red	...	Alk.	1014	294·02	$\frac{1}{3}$	„	..
„ 20	66	„	Ammoniacal	„	1010	...	$\frac{1}{2}$	„	...
„ 21	56	...	„	Strg. alk.	...	390 10	$\frac{1}{2}$	„	...
„ 22	44	Smoky red	„	„	...	...	$\frac{1}{2}$	„	...
„ 23	35	„	„	„	...	183·00	$\frac{3}{8}$	„	Hyaline and granular; large round cells.
„ 24	28	„	„	„	...	...	$\frac{2}{3}$	„	...
„ 25	7 (16 hours)	red	„	„	...	12·18	...	Blood & mucus.	Blood, pus-cells.

Case 3.—Delivery of a living child through epitheliomatous cervix at term; high amputation of cervix fifteen days later; fourteen months later pregnancy, with subsequent complete closure of vagina by cicatrix; Porro's operation with intra-peritoneal treatment of the stump at term; recovery of mother and child; patient free from recurrence of the cancer after three years.

E. W—, aged 33, the mother of five children, was delivered by forceps in the maternity of University College Hospital of a living child through a cancerous cervix on March 25th, 1893, by my assistant, Mr. H. Ballance, who correctly diagnosed the condition. The patient made an uninterrupted recovery, the puerperal temperature not rising above normal.

She had been suffering from a discharge of "matter" and bright blood for eight months; during the last month of her pregnancy she had had bearing-down pains. She did not think she had lost flesh at all, and looked in very good health, as she had always been, except when she had two attacks of rheumatic fever, one occurring at the age of fifteen, and one a year ago.

She began to menstruate at the age of fourteen, was always regular, the periods lasting four days, and being usually accompanied by a good deal of pain at the beginning.

During the ten years of her married life she had "scarcely seen anything from one child to another." She had occasionally had a white discharge before her present illness.

There was no history in the family of tumours or of phthisis.

On April 5th, 1893, eleven days after delivery, I admitted the patient into University College Hospital. There was an ulcerated epitheliomatous growth (measuring $1\frac{7}{8}$ inch by $1\frac{1}{2}$ inch) on the anterior lip of the cervix, typical both clinically and to microscopic examina-

tion. (Specimens and sections exhibited.) The growth was limited to the anterior lip, and did not invade the vaginal wall.

On April 8th, 1893, I performed the high amputation of the cervix, using catgut for the ligature of the broad ligaments, and severing the stump with Paquelin's cautery. The operation was difficult owing to the proximity of the growth to the bladder. The patient recovered well from the operation, and the wound had healed on the 4th of May, and the patient left the hospital on May 8th feeling and looking very well.

Subsequently I saw the patient at frequent intervals. She continued in excellent health, menstruated regularly but with pain, and gained in weight. On February 8th, 1894, the position of the uterine wound was indicated by a small red spot in the middle of an extensive scar.

Patient menstruated for the last time on June 4th, 5th, and 6th, 1894, and on October 11th came to see me. The breasts were typical of pregnancy, and the body of the uterus could be felt rising up to a height of five inches above the pubes. There was slight violet colorisation of the vagina, which contained a copious milky discharge. The top of the vagina was scarred in all directions, and the scar was quite healthy, and had no aperture in it: the patient was carefully examined under an anæsthetic to settle this point.

It was decided to deliver the patient by Cæsarean section at term.

On November 8th the uterus reached to a height of 5¾ inches above the pubes, and ballottement and spontaneous movements could be felt.

On January 3rd, 1895, the breasts were typical of advanced pregnancy; the fundus was 8½ inches above the pubes, 2¾ inches above the umbilicus. The head presented: the heart-sounds (168) were heard midway between the pubes and the umbilicus. The head was felt rather more readily on the left side than ordinarily, apparently owing to the wall being thin there. The round

ligaments could not be distinctly felt. The patient weighed 9 st. 6 lbs.

January 17th, 1895.—The uterus reached up vertically 9½ inches above the pubes. The head presented; the back was on the right side, the forehead on the left side; the child's loin 3 inches to the right of and ½ inch above the umbilicus; the heart-sounds were heard 3 inches to the right of and 2 inches below the umbilicus. The right round ligament was felt in about its normal position, showing apparently that the uterus was not much rotated. The patient had not noticed any discharge during the pregnancy.

February 7th, 1895.—The uterus rose to a height of 11 inches above the pubes. The fœtal pulse was 124. No uterine souffle could be heard.

On February 16th, 1895, the patient was admitted to University College Hospital. She then weighed 10 st. 1 lb. (in May, 1894, 8 st. 9 lbs.).

On February 21st, 1895, the patient appeared in extremely good health; the tongue was red and clean, the pulse and temperature and urine normal.

The abdomen was distended as at eight and a half months of gestation. The uterus reached 10¼ inches above the pubes. The following measurements were also taken:

Abdominal girth on left side .	17¼	inches.
Abdominal girth on right side .	17¾	,,
Ensiform to pubes (over skin) .	17½	,,
Umbilicus to right iliac spine .	8¼	,,
Umbilicus to left iliac spine .	8¼	,,
Umbilicus to pubes (over skin) .	8¼	,,
Umbilicus to pubes (vertically) .	6½	,,

There were very few skin-cracks on the abdomen. The uterus was slightly dextroverted, reaching 5 inches to the right and 4½ inches to the left of the middle line.

Abdominal palpation was easy. The child's head lay below, resting in the pelvic brim, slightly flexed, the forehead on the left side, the back on the right side; the right posterior axillary fold 3½ inches below and 3 inches to the

right of the middle line. The breech was in the right corner of the uterus, the left loin 4½ inches to the right of the middle line, and 1 inch above the umbilicus. The knee, leg, and arm could be felt at times in the middle line with such distinctness as showed the absence of the placenta from the front of the uterus. The fœtal heart was beating 140 to the minute. Limbs could be felt on the left side of the uterus. There were blue veins in each labium, and well-marked purple colorisation of the vagina. The vagina was quite closed above, and there was a thin septum of scar tissue between the examining finger and the head. There was no sign of any growth.

28th.—At a point 1 inch to the left of and 2 inches above the right anterior superior iliac spine a funic souffle was heard; the uterine souffle was inaudible.

On March 2nd, 1895, the uterus was slightly tilted to the left side. The round ligaments could be felt, and showed that the right side of the uterus was perceptibly though slightly twisted in front of the left. The uterine souffle was heard on deep pressure 3 inches to the left of the middle line.

On March 5th the patient had an aperient and enema, and a vaginal douche of 1 in 1000 corrosive sublimate solution.

On March 6th, 1895, I performed Cæsarean hysterectomy at 9.45 a.m., labour not having commenced. The patient complained of headache, had a slight cough, and was sick after the administration of an enema, but seemed otherwise in good health. My colleague, Dr. Blacker, kindly assisted me at the operation. Gas and ether were administered.

An incision 5 inches long was made downwards from just above the umbilicus. A few Spencer Wells forceps were applied to the bleeding vessels. The peritoneum was opened on a director, and the uterus, being found to be nearly symmetrically situated, was opened in the middle line towards the lower part of the abdominal wound. The membranes being accidentally punctured,

the wound was rapidly slit up by scissors protected by the fingers, and the child, which lay in the second position, was easily extracted by the head. Then the cord was clamped and the child removed. It breathed and cried at once. After removal of the placenta and membranes the scar was examined between the left forefinger in the uterus and the right in the vagina; then, retaining the left forefinger in place, I passed a pair of long dressing forceps into the vagina and through the septum into the uterus. A long piece of drainage-tube was placed in the jaws of the forceps and drawn into the vagina and out at the vulva, the other end remaining in the uterus. Then the wire of the serre-nœud was placed around the lower segment of the uterus containing the drainage-tube, beneath the ovaries and Fallopian tubes, which, with the uterus, were cut away after the wire had been tightened. The serre-nœud (held down by a pin) thus served to hold the drainage-tube in position as well as to compress the stump.* The wound was closed by thick silk sutures passing through the whole thickness of the abdominal wall (the sutures next the stump above and below catching up the peritoneum below the wire), and superficial sutures of fine silk. The stump was powdered with boracic acid, and the wound dressed with iodoform gauze and a many-tailed flannel bandage. No drainage was employed. The total duration of the operation till the dressing was applied was twenty-two minutes. The child was delivered in one and a half minutes, and the uterus amputated at the end of eleven minutes. There was very little bleeding during the operation, and very little shock afterwards. The pulse was 87. The child, a boy, measured 19 inches, and weighed 7 lbs. 5 oz. It had slight double talipes calcaneus.

* It would have been better to tie a piece of silkworm gut to the upper end of the drainage-tube, and to let the silkworm gut hold the tube in position.

Measurements of child's head:

Occipito-frontal . . .	$4\frac{5}{8}$ inches.
Occipito-mental . . .	$5\frac{1}{4}$,,
Bi-parietal . . .	$3\frac{3}{4}$,,
Bi-temporal . . .	$3\frac{1}{2}$,,
Suboccipito-bregmatic . .	$3\frac{3}{4}$,,
Cervico-bregmatic . .	4 ,,

The placenta, which was situated at the posterior part of the uterus, weighed (with the cord) 1 lb. $7\frac{1}{2}$ oz. It measured $7\frac{1}{4}$ inches vertically by 8 inches laterally. The cord was attached $1\frac{1}{2}$ inches from the lower edge of the placenta, and was $28\frac{1}{2}$ inches long.

The uterus removed weighed 1 lb. $9\frac{1}{2}$ oz., and measured 6 inches vertically by 6 inches laterally, and $13\frac{1}{2}$ inches in circumference at its widest part. There was a well-marked corpus luteum in the right ovary. The patient was a little sick when she came from under the influence of the anæsthetic. At 4.30 p.m. she had a good deal of pain, and an attack of bronchitis was coming on, the breathing getting more rapid and numerous râles and rhonchi being heard all over the chest. For this the patient was ordered the steam atmosphere. At 6.30 p.m. the catheter was passed, and ℥x of urine drawn off. At 9.35 p.m., the abdominal pain being great, ♏ij of hypodermic injection of morphia were given. At 11.30 p.m. the dressings were soaked through; the serre-nœud was tightened by three turns, and fresh iodoform gauze packed in. The patient had a well-marked attack of bronchitis, and the breathing was 44 to the minute.

March 7th.—12.45 a.m., breathing 52, pulse 128, temp. 98°. At 2.25 a.m. the wound was dressed, patient coughing up a good deal of frothy mucus. Breathing 50, easier; temp. 99·6°. At 1.30 p.m. wound again dressed. The rubber tube was cut off deep down in the stump. It then evidently slipped past the serre-nœud, for profuse arterial bleeding occurred, which was at once stopped by tightening the serre-nœud. An injection *per vaginam* of 1 in 3000 corrosive sublimate solution was

given by the tube. The patient took ammonia and ipecacuanha for the cough, milk and barley water as food.

8th.—Patient better. Flatus was passed at 3 a.m. Temperature varied from 98·6° to 99·8°; pulse 94 to 124.

9th.—The temperature rose to 102·8°, and next day to 104°. Dulness, tubular breathing, and râles were heard in the left axilla. The stump was dressed; it was dry and sweet. The tube was removed from the vagina. There was a slight blood-stained sweet discharge from the cavity, which was syringed out with perchloride solution. The bowels were opened by saline mixture.

11th.—Dr. Ringer kindly examined the patient. There was dulness up to angle of the left scapula; well-marked bronchophony and the typical dry crackling râles of pneumonia were to be heard. There was slight dulness at the base of the right lung and moist râles.

13th.—The deep stitches were removed; the wound had united by first intention. The remainder of the convalescence was only interrupted by the pneumonia, which ran a favourable course. The general condition of the patient was excellent throughout.

On March 16th Dr. Ringer found only slight dulness at the left base, with weak breath-sounds and tubular breathing. The temperature on this day fell to normal, and remained practically normal throughout the rest of her stay in the hospital.

On March 18th the stump was cut away. There was a little offensive discharge around it. The stump cavity was washed with 1 in 20 carbolic acid, and dressed with boracic acid and iodoform gauze.

On March 23rd the cough had quite ceased, and the chest was practically normal. The superficial stitches were removed on March 28th, the wound being soundly healed except where the stump lay. This cavity did not completely close until April 23rd.

On April 26th patient left the hospital quite well with

her infant, which she had suckled throughout, and which weighed 8 lbs. 13½ oz.

On May 28th, 1895, the patient returned from the Eastbourne Convalescent Home. She looked and felt perfectly well. The scar was sound. At the top of the vagina in the situation of the stump was felt a small moveable nodule, about the size of the tip of the forefinger. It was apparently the remains of the lower segment of the uterus. There was no ulceration or discharge, and no sign of new growth in the pelvis. The mother weighed 9 st. 3 lbs., the infant 11 lbs. The infant's feet were practically normal, having been extended from time to time by the mother.

On November 26th, 1895, the patient was well. She weighed 8 st. 5 lbs. She had lost sexual desire and sexual pleasure since the removal of the uterus and ovaries.

On April 30th, 1896, I saw the patient and her infant, both in perfect health; the former weighed 8 st. 8 lbs., the latter 16¼ lbs. The abdominal scar was quite sound, and there was no hernia; the vaginal scar was also perfectly sound, and the stump of the lower segment was of the size of the tip of the forefinger, freely moveable without any tenderness, and there was not the slightest sign of recurrence more than three years after the supravaginal amputation of the cervix.

Remarks.

The three cases now recorded are the only ones in which I have performed Cæsarean hysterectomy, though I have performed the conservative Cæsarean section on three occasions, each time with success. There can be no doubt that the conservative operation is generally to be preferred for cases of simple contraction of the pelvis. For fibroids obstructing labour (as in Case 1) Cæsarean hysterectomy is, I think, when practicable, the better operation. For enchondroma of the sacrum I believe that the conservative operation is preferable; or if, as in the

case recorded, on account of injury to the uterus it be thought advisable to remove the organ, the extra-peritoneal treatment of the stump should not be adopted in the case of a large tumour, for the non-vascular tumour interferes with that close apposition and union of the parietal and visceral peritoneum which is such an important factor in the success of that method of operating.

Cases 1 and 2 had, at term, the absolute indication for Cæsarean section, being incapable of delivery by any other means. The first case, however, was seen by me when six weeks pregnant, and might have been treated by the induction of abortion. The risk of septicæmia in such cases is, however, great; and for this and other reasons stated in the text I should be very unwilling to induce abortion on account of fibroid tumours of the uterus. Opinions will probably differ most in regard to Case 3. In the first place it offers an argument against those who, like myself, perform high amputation instead of total hysterectomy for cancer of the cervix. It is the only instance in which I have known pregnancy to occur after the high amputation; and the fact that the patient is, after three years, free from recurrence and in excellent health, and has in addition a child, may be set off against the extra risk which she ran owing to the body having been left behind. When the patient became pregnant and complete cicatricial stenosis occurred, four methods of treatment suggested themselves: (1) incision of the cicatrix and induction of abortion; (2) incision of the cicatrix and dilatation during labour; (3) hysterectomy during the early months of pregnancy; (4) Cæsarean hysterectomy. The first two of these methods would have involved great risk of opening the peritoneum and of subsequent septicæmia.

Clivio ('Annali di Ostetriciae Ginecologia,' 1896, p. 237) has collected twenty cases in which labour (in most cases also pregnancy) occurred after amputation of the cervix. In most if not all of these cases the vaginal portion only was amputated, yet the labour was attended by a mor-

tality of 35 per cent. for the mothers and 50 per cent. for the children, and there is no doubt that the mortality would have been greater after the high amputation. Hysterectomy during early pregnancy would have offered no advantage over Cæsarean hysterectomy, since the vaginal operation would have endangered the ureters and bladder owing to the absence of landmarks. These dangers and the increased risk of the operation also prevented me from removing the *whole* of the remains of the uterus, and the difficulty of efficiently draining the body through the cicatrix, and the risk of subsequent hæmatometra and of pregnancy, decided against the conservative Cæsarean section.

As regards the inflammation of the lungs from which this patient suffered, there is reason for believing that it commenced before the operation was performed, though no doubt it was aggravated by the ether administered.

The death of Case 2 was, I believe, due to the hydronephrosis and nephritis from which the patient was suffering.

There remain a few points to which I would briefly allude. The protracted pregnancy in Case 1—299 days (or if both the last day of menstruation and the day of labour be included, 300 days) from the last day of the last menstruation—is the longest I have observed. This patient gained 21 lbs. in weight in the four years after the operation, and flushes still occurred at the end of that time. After the operation the sexual passion was lost for fourteen months and then reappeared; this is the only instance I have met with of reappearance of the sexual passion when it has been lost after removal of the ovaries, though I have known it to completely disappear after that operation in a number of instances, of which Case 3 is also an example.

The history and microscopic appearances of the case of enchondroma of the sacrum, of which there are very few records, suggest that the disease possibly arose from an injury to a sacral intervertebral disc in early life. From

the pathological point of view this case is the most important, but I hope that all the three cases will present some features of interest to the Fellows of this Society.

Dr. ARTHUR GILES, in referring to Dr. Spencer's second case, said that enchondroma or osteoma of the sacrum impeding labour was such a rare complication that he thought it would be of interest to the Fellows if he mentioned a case he had met with when house physician to the General Lying-in Hospital, Lambeth. The patient had had two children; the last, born eight years previously, was delivered with forceps. On examining by the vagina a hard hemispherical mass, the size of half an orange, was found springing from the situation of the second and third sacral vertebræ in the middle line. The conjugata vera was in consequence reduced to 3¾ inches. It was thought advisable to perform podalic version, and he did so before the membranes were ruptured. The labour then proceeded in a natural manner. He had not an opportunity of ascertaining the true nature of the tumour, but from its position and extreme hardness thought it to be either an enchrondroma or an osteoma. He had lost sight of the patient afterwards. It would have been interesting to know her subsequent history, because if the tumour increased in size, and the patient became pregnant again, Cæsarean section would probably be required, as in Dr. Spencer's case. He had not gathered clearly from the paper Dr. Spencer's reason for passing a drainage-tube, in the third case, into the vagina from the interior of the uterus; for, as the upper end of the tube was apparently fixed in the tissues grasped by the serre-nœud, its value for drainage would seem to be limited.

Dr. ROBERTS asked Dr. Spencer if, in ordinary cases of abdominal section, he considered it necessary to take the uterus out of the abdominal cavity after extraction of the child, since it could be sutured *in situ*, and taking out the uterus and exposing it to cold, &c., appeared to involve greater shock. Dr. Roberts also asked if Dr. Spencer, in the ordinary Cæsarean section, used vaginal drainage, or used douches, vaginal or intra-uterine, after the operation. Another point also occurred to Dr. Roberts; that was that the use of the elastic ligature or even constriction by the hands applied to the neck of the uterus during Cæsarean section seemed to paralyse the uterine contractions subsequently, and consequently there was a neck of the uterus not contracting after the extraction of the child. Dr. Roberts asked Dr. Spencer if any such failure of contraction had been noted in his cases where the neck of the uterus had been grasped.

Dr. PETER HORROCKS thought that possibly the intra-peritoneal method would have been a more satisfactory operation in two of the cases at least. He asked if there had been any pain through dragging on the scar subsequently. He suggested that the fatal case might possibly have died through absorption from the distal end of the stump of septic matter, which was always a danger unless the vessels were kept thoroughly compressed by the serre-nœud.

Dr. G. D. ROBINSON referred to the method of completing the uterine wound adopted by Dr. Spencer in two of his cases, viz. tearing with the fingers. Dr. Robinson had recently, when assisting at a case of Cæsarean section, been surprised at the ease with which the uterine tissue tore. He asked whether this was also Dr. Spencer's experience, and whether, in the cases narrated in his paper, he had been able to regulate the amount and direction of the tear.

Dr. SPENCER thanked the Society for the reception given to his paper. In reply to the remarks which had been made he stated that the drainage-tube was employed in Case 3 because, owing to the complete closure of the vaginal cicatrix, a small cavity was left below the wire of the serre-nœud in which blood might have collected, and have become infected without means of exit until the stump came away. He thought that the uterus should not be removed from the abdomen before the Cæsarean incision was made; but after the delivery of the child he withdrew the organ from the abdomen in order to avoid soiling the peritoneum, and to facilitate compression. He did not use a drainage-tube or douche in ordinary Cæsarean section, and depended on rapidity of operating for the avoidance of severe hæmorrhage, and never used an elastic ligature, which he considered harmful and quite unnecessary. He had adopted the extra-peritoneal method of treating the stump because he believed it to be the safer method for severe operations. He had never known patients complain of dragging upon the scar left by the extra-peritoneal stump, and regarded the greater liability to hernia as the only serious objection to that method of operating. It was possible that absorption from the stump had something to do with the death of the patient in Case 2, but he thought the renal disease was the chief factor, and experience showed that Cæsarean section was very dangerous in advanced disease of the kidney. In reply to Dr. Robinson he could state that it was very easy to tear the uterine muscle, but his experience in another case showed that the direction of the tear could not be sufficiently controlled by the operator. He would therefore only employ it in such a case as Case 1, where, owing to the presence of fibroids and severe hæmorrhage, it was impossible to use the knife with safety.

INDEX.

PAGE

Abdominal hysterectomy with intra-peritoneal treatment of the stump, with notes of eight cases (Harrison Cripps) . 41
—— section, chorionic villi from a tubal mole removed by (A. H. N. Lewers) 106
—— —— dermoid ovarian cyst impacted in the pelvis removed by, during the ninth month of pregnancy (Thomas H. Morse) 221
Abortion, notes of a case of malignant disease of the uterus with numerous deposits in the lungs, and death following (John D. Malcolm) 125
—— simple maieutic for the induction of premature labour or (Peter Horrocks) 168
Abscess, tubo-ovarian (Walter Tate) . . . 319
Address (Annual) of the President, F. H. Champneys, M.A., M.D., February 5th, 1896 60
Ætiology of gonorrhœa (Frederick J. McCann) . . 225
Annual General Meeting, February 5th, 1896 . . 29
Auditors for 1896 379

Balance-sheet for the year 1895 57
Betts, Frederick Bernard, L.R.C.P., of Autofagasta, obituary notice of 73
BLACKER (G. F.) and T. W. P. LAWRENCE, a case of true unilateral hermaphroditism with ovotestis occurring in man, with a summary and criticism of the recorded cases of true hermaphroditism 265
BOXALL (Robert), *Remarks* in discussion on Leonard Remfry's paper on the effects of lactation on menstruation and impregnation 27
—— —— in discussion on Thomas A. Morse's case of dermoid ovarian cyst impacted in the pelvis, which was removed by abdominal section during the ninth month of pregnancy 221

PAGE

Cancer, independent, of the body and of the cervix uteri (Amand Routh) 100
—— of the cervix, two uteri removed by vaginal hysterectomy for (A. H. N. Lewers) 164
—— of the Fallopian tubes, unreported case of primary, in 1847, with notes on primary tubal cancer (Alban Doran) 322
—— of the uterus, fibroid tumours and (Amand Routh) . 99
Cancerous uterus with pyometra (A. H. N. Lewers) . . 14
Carcinoma, uterine fibroid associated with (A. L. Galabin) . 102
Cast from the uterus having all the characters of the decidual membrane found in connection with ectopic gestation, together with a small ovarian cyst from the same case, with microscopic sections of each (W. R. Dakin) . 385
Cervix, see *Uterus* (*cervix of*).
CHAMPNEYS (F. H.), *Annual Address* as President . . 60
—— *Remarks* in discussion on C. J. Cullingworth's specimen of large fibro-cystic myoma growing from the cervix uteri 12
—— —— in discussion on Harrison Cripps's paper on abdominal hysterectomy with intra-peritoneal treatment of the stump, with notes of eight cases . . . 113
—— —— in discussion on Peter Horrocks's simple maieutic for the induction of miscarriage or premature labour . 168
—— —— in discussion on J. R. Morison's, Herbert R. Spencer's, and T. W. Eden's papers on deciduoma malignum . 181
—— —— in discussion on Alban Doran's paper on cases of fibroma of the ovary and ovarian ligament removed by operation 211
—— —— in discussion on John Phillips's paper on anterior colpotomy 220
—— —— in discussion on G. F. Blacker's and T. W. P. Lawrence's paper on a case of true unilateral hermaphroditism with ovotestis occurring in man, with a summary and criticism of the recorded cases of true hermaphroditism 309
—— —— in discussion on W. Rivers Pollock's specimen of fœtus papyraceus 321
—— —— in discussion on A. H. N. Lewers's paper on a case of double uterus with double hæmatometra and complete absence of the vagina 340
Chance, Edward John, F.R.C.S.I., of Russell Square, obituary notice of 73

PAGE

Chorion, villi of, and doubtful sarcoma, microscopical sections of uterus showing (Leonard Remfry) . . . 223
—— —— from a tubal mole removed by abdominal section (A. H. N. Lewers) 106
Colpotomy, anterior (John Phillips) . . . 213
—— hydrosalpinx and small ovarian cyst removed by anterior (Amand Routh) 185
Cord, see *Funis, Umbilical.*
Corpus luteum, ovarian tumour containing (A. L. Galabin) . 101
CRIPPS (Harrison), abdominal hysterectomy with intra-peritoneal treatment of the stump, with notes of eight cases 41
—— *Remarks* in reply 115
CULLINGWORTH (C. J.), large fibro-cystic myoma growing from the cervix uteri (shown) 8
—— *Remarks* in reply 12
—— multiple fibro-myomata of the uterus (shown) . . 6
—— *Remarks* in discussion on Harrison Cripps's paper on abdominal hysterectomy with intra-peritoneal treatment of the stump, with notes of eight cases . . 107
—— —— in discussion on Alban Doran's paper on cases of fibroma of the ovary and ovarian ligament removed by operation 209
—— —— in discussion on Frederick J. McCann's paper on the ætiology of gonorrhœa 264
—— —— in discussion on Alban Doran's unreported case of primary cancer of the Fallopian tubes in 1847, with notes on primary tubal cancer 325
—— —— in discussion on A. H. N. Lewers's paper on a case of double uterus with double hæmatometra and complete absence of the vagina 337
—— *Report* of Committee 4
—— —— on Leith Napier's specimen of solid ovarian tumour 32
—— ruptured tube and three weeks embryo from the sac of an old pelvic hæmatocele 122
—— supposed case of tubo-ovarian cyst (shown) . . 1
CURATULO (J. Emilio), on the influence of the removal of the ovaries on metabolism in connection with osteomalacia . 17
Cyst, dermoid ovarian, impacted in the pelvis, which was removed by abdominal section during the ninth month of pregnancy (Thomas H. Morse) . . . 221
—— large double tubo-ovarian (William Duncan) . . 37

PAGE

Cyst, myoma of uterus weighing over fifteen pounds (Alban Doran) 164
—— small ovarian, and hydrosalpinx removed by anterior colpotomy (Amand Routh) 185
—— small ovarian, with cast from the uterus having all the characters of the decidual membrane found in connection with ectopic gestation (W. R. Dakin) . . . 385
—— supposed case of tubo-ovarian (C. J. Cullingworth) . 1
—— supposed tubo-ovarian (C. J. Cullingworth) . . 4

DAKIN (W. R.), cast from the uterus having all the characters of the decidual membrane found in connection with ectopic gestation, together with a small ovarian cyst from the same case with microscopic sections of each (shown) . 385
—— *Remarks* in discussion on Frederick J. McCann's paper on the ætiology of gonorrhœa 264
—— —— in discussion on Thomas G. Stevens's paper on completely cleft spine associated with an unusual visceral malformation in an anencephalic fœtus . . 359
—— —— in discussion on T. W. Eden's paper on the structure of the ripe placenta, and the changes which occur in placentæ retained *in utero* after the death of the fœtus . 377
—— *Report* on Amand Routh's specimen of fœtus diprosopus anencephalicus 99
Dawson (Ernest), nomination as auditor for 1896 . . 379
Deciduoma malignum (Herbert R. Spencer) . . 135
—— —— a criticism (T. W. Eden) . . . 149
—— —— addendum to paper on (T. W. Eden) . . 162
—— —— adjourned discussion on . . . 171
—— —— occurring in England (J. Rutherford Morison) . 130
—— —— *Report* of Committee on specimens of . . 183
Dermoid ovarian cyst impacted in the pelvis which was removed by abdominal section during the ninth month of pregnancy (Thomas H. Morse) . . . 221
DORAN (Alban), cases of fibroma of the ovary and ovarian ligament removed by operation; with a series of after-histories of cases reported in the 'Transactions' since 1879 . 187
—— *Remarks* in reply 211
—— cystic myoma of uterus weighing over fifteen pounds (shown) 164
—— *Remarks* in discussion on C. J. Cullingworth's specimen of supposed case of tubo-ovarian cyst . . . 3

PAGE

DORAN (Alban), *Remarks* in discussion on A. L. Galabin's specimen of extra-uterine fœtation not primarily tubal . 92
—— —— in discussion on J. R. Morison's, Herbert R. Spencer's, and T. W. Eden's papers on deciduoma malignum 180
—— —— in discussion on A. H. N. Lewers's paper on a case of double uterus with double hæmatometra and complete absence of the vagina 341
—— *Report* on C. J. Cullingworth's specimen of supposed tubo-ovarian cyst 4
—— —— on A. L. Galabin's specimen of extra-uterine gestation 90
—— —— on A. H. N. Lewers's specimen of tubal mole . 87
—— —— on J. R. Morison's and Herbert R. Spencer's specimens of deciduoma malignum, and J. D. Malcolm's specimen of sarcoma of the uterus . . . 184
—— unreported case of primary cancer of the Fallopian tubes in 1847, with notes on primary tubal cancer . . 322
DUNCAN (William), large double tubo-ovarian cysts (shown) . 37
—— *Remarks* in discussion on C. J. Cullingworth's specimen of multiple fibro-myomata of the uterus . . 8
—— —— in discussion on C. J. Cullingworth's specimen of large fibro-cystic myoma growing from the cervix uteri . 11
—— —— in discussion on A. H. N. Lewers's specimen of cancerous uterus with pyometra 14
—— —— in discussion on J. E. Curatulo's paper on the influence of the removal of the ovaries on metabolism in connection with osteomalacia 21

Ectopic gestation, see *Pregnancy* (*extra-uterine*).
EDEN (T. W.), addendum to paper on deciduoma malignum . 162
—— deciduoma malignum: a criticism . . . 149
—— *Remarks* in reply 182
—— —— in discussion on Leonard Remfry's paper on the effects of lactation on menstruation and impregnation . 26
—— on the structure of the ripe placenta, and the changes which occur in placentæ retained *in utero* after the death of the fœtus 360
—— *Remarks* in reply 377
—— —— in discussion on Leonard Remfry's specimen of microscopical sections of uterus showing chorionic villi and doubtful sarcoma 224

PAGE

EDEN (T. W.), *Report* on A. L. Galabin's specimen of extra-uterine gestation 90
—— —— on J. R. Morison's and Herbert R. Spencer's specimens of deciduoma malignum and J. D. Malcolm's specimen of sarcoma of the uterus . . . 184
Election of New Fellows . . 1, 87, 117, 163, 185, 223, 319, 345
Embryo, three weeks, and ruptured tube from the sac of an old pelvic hæmatocele (C. J. Cullingworth) . . 122
Epithelioma of vagina, primary (C. Hubert Roberts) . 381

Fairweather (David), nomination as auditor for 1896 . 379
Fallopian tubes, unreported case of primary cancer of, in 1847, with notes on primary tubal cancer (Alban Doran) . 322
Fellows, see *Lists, Elections.*
Fibroid, see *Tumours (fibroid).*
Fibroma of the ovary and ovarian ligament removed by operation; with a series of after-histories of cases reported in the 'Transactions' since 1879 (Alban Doran) . . 187
Fibro-myomata, multiple, of the uterus (C. J. Cullingworth) . 6
Fœtation, see *Pregnancy.*
Fœtus, anencephalic, completely cleft spine associated with an unusual visceral malformation in (Thomas G. Stevens) . 346
—— deformed, with cystic tumour of neck (A. H. N. Lewers) . 106
—— diprosopus anencephalicus, see *Monsters.*
—— five months, and placenta, from a case of twin pregnancy in which the second child was delivered alive at or near full term along with the dead fœtus (G. G. Genge) . 5
—— papyraceus (W. Rivers Pollock) . . . 320
—— placenta, cord, and membranes (Robert Wise) . . 166
—— see *Monsters.*
—— structure of the ripe placenta, and the changes which occur in placentæ retained *in utero* after the death of (T. W. Eden) 360
FOTHERGILL (W. E.), *Remarks* in discussion on J. R. Morison's, Herbert R. Spencer's, and T. W. Eden's papers on deciduoma malignum 176
Funis (umbilical), placenta, fœtus, and membranes (Robert Wise) 166

GALABIN (A. L.), extra-uterine fœtation not primarily tubal (shown) 91
—— intra-ligamentous gestation retained for twenty-one years (shown) 38
—— *Remarks* in reply 39

PAGE

GALABIN (A. L.), microscopic sections of tissue removed from the uterus (shown) 121
—— myxo-sarcoma of urethra in a child (shown) . . 120
—— ovarian tumour containing corpus luteum (shown) . 101
—— sarcoma of cervix uteri (shown) . . . 120
—— tubal gestation ruptured at the sixth week (shown) . 39
—— uterine fibroid associated with carcinoma (shown) . 102
—— *Remarks* in discussion on Harrison Cripps's paper on abdominal hysterectomy with intra-peritoneal treatment of the stump, with notes of eight cases . . . 111
—— *Report* of Committee on specimen of extra-uterine gestation 88
—— *Remarks* on *Report* of Committee . . . 88
GALTON (J. H.), *Remarks* in discussion on J. Sidney Turner's specimen of hydronephrosis of the left kidney . . 105
GANDY (W.), *Remarks* in discussion on Peter Horrocks's simple maieutic for the induction of miscarriage or premature labour 170
GARDINER (Bellamy), *Remarks* in discussion on T. W. Eden's paper on the structure of the ripe placenta, and the changes which occur in placentæ retained *in utero* after the death of the fœtus 377
GENGE (G. G.), five months' fœtus and placenta, from a case of twin pregnancy in which the second child was delivered alive at or near full term along with the dead fœtus (shown) 5
Gestation, see *Pregnancy*.
GILES (Arthur E.), *Report* on Amand Routh's specimen of fœtus diprosopus anencephalicus . . . 99
—— *Remarks* in discussion on H. R. Spencer's paper on three cases of Porro's operation, with intra-peritoneal treatment of the stump 423
Gonorrhœa, ætiology of (Frederick J. McCann) . . 225
GRIFFITH (W. S. A.), *Report* on C. J. Cullingworth's specimen of supposed tubo-ovarian cyst 4
—— —— on Leith Napier's specimen of solid ovarian tumour 32
—— —— on J. R. Morison's and Herbert R. Spencer's specimens of deciduoma malignum, and J. D. Malcolm's specimen of sarcoma of the uterus 184
—— *Remarks* in discussion on A. H. N. Lewers's specimen of cancerous uterus with pyometra . . . 14

PAGE

GRIFFITH (W. S. A.), *Remarks* in discussion on J. E. Curatulo's paper on the influence of the removal of the ovaries on metabolism in connection with osteomalacia . . 20

—— —— in discussion on W. R. Dakin's cast from the uterus having all the characters of the decidual membrane found in connection with ectopic gestation, together with a small ovarian cyst from the same case, with microscopic sections of each 387

—— see *A. F. Stabb*.

Grove, William Richard, M.D., of St. Ives, obituary notice of . 74

Hæmatocele, ruptured tube and three weeks' embryo from the sac of an old pelvic (C. J. Cullingworth) . . 122

Hæmatometra, case of double uterus with double, and complete absence of the vagina (A. H. N. Lewers) . . 327

HANDFIELD-JONES (M.), *Remarks* in discussion on Alban Doran's paper on cases of fibroma of the ovary and ovarian ligament removed by operation . . . 208

HERMAN (G. E.), *Remarks* in discussion on C. J. Cullingworth's specimen of large fibro-cystic myoma growing from the cervix uteri 11

—— —— in discussion on Peter Horrocks's simple maieutic for the induction of miscarriage or premature labour . 169

—— —— in discussion on G. F. Blacker's and T. W. P. Lawrence's paper on a case of true unilateral hermaphroditism with ovotestis occurring in man, with a summary and criticism of the recorded cases of true hermaphroditism 309

—— —— in discussion on A. H. N. Lewers's paper on a case of double uterus with double hæmatometra and complete absence of the vagina 338

Hermaphroditism, true unilateral, with ovotestis occurring in man, with a summary and criticism of the recorded cases of true hermaphroditism (G. F. Blacker and T. W. P. Lawrence) 265

Hodges, Richard, M.D., F.R.C.S., of Camden Road, obituary notice of 74

HORROCKS (Peter), simple maieutic for the induction of miscarriage or premature labour (shown) . . 168

—— *Remarks* in discussion on Harrison Cripps's paper on abdominal hysterectomy with intra-peritoneal treatment of the stump, with notes of eight cases . . . 112

PAGE

HORROCKS (Peter), *Remarks* in discussion on Alban Doran's paper on cases of fibroma of the ovary and ovarian ligament removed by operation 208
—— —— in discussion on Frederick J. McCann's paper on the ætiology of gonorrhœa 264
—— —— in discussion on T. W. Eden's paper on the structure of the ripe placenta, and the changes which occur in placentæ retained *in utero* after the death of the fœtus . 376
—— —— in discussion on H. R. Spencer's paper on three cases of Porro's operation, with intra-peritoneal treatment of the stump 424
Hydronephrosis of the left kidney (J. Sidney Turner) . 103
Hydrosalpinx and small ovarian cyst removed by anterior colpotomy (Amand Routh) 185
Hysterectomy, abdominal, with intra-peritoneal treatment of the stump, with notes of eight cases (Harrison Cripps) . 41
—— vaginal, two uteri removed by, for cancer of the cervix, the disease being apparently at the same stage in each (A. H. N. Lewers) 164

Impregnation, effects of lactation on menstruation and (Leonard Remfry) 22
Induction of miscarriage or premature labour, a simple maieutic for (Peter Horrocks) . . . 168

James, James Prytherck, of Eastleigh, obituary notice of . 73
JONES (H. Macnaughton), self-retaining glass retractors (shown) 345
—— *Remarks* in discussion on Alban Doran's paper on cases of fibroma of the ovary and ovarian ligament removed by operation 208
Jones, Jones, of King Street, Regent Street, obituary notice of 73

KANTHACK (A. A.), *Remarks* in discussion on J. R. Morison's, Herbert R. Spencer's, and T. W. Eden's papers on deciduoma malignum 171
—— *Report* on J. R. Morison's and Herbert R. Spencer's specimens of deciduoma malignum and J. D. Malcolm's specimen of sarcoma of the uterus . . . 184

PAGE

Kidd, George Hugh, M.D., F.R.C.S.I., of Dublin, obituary notice of 74
Kidney, hydronephrosis of the left (J. Sidney Turner) . 103

Lactation, effects of, on menstruation and impregnation (Leonard Remfry) 22
LAWRENCE (T. W. P.) and G. F. BLACKER, case of true unilateral hermaphroditism with ovotestis occurring in man, with a summary and criticism of the recorded cases of true hermaphroditism 265

LEWERS (Arthur H. N.), cancerous uterus with pyometra (shown) 14
—— case of double uterus with double hæmatometra and complete absence of the vagina 327
—— *Remarks* in reply 342
—— chorionic villi from a tubal mole removed by abdominal section (shown) 106
—— deformed fœtus with cystic tumour of neck (shown) . 106
—— two uteri removed by vaginal hysterectomy for cancer of the cervix, the disease being apparently at the same stage in each (shown) 164
—— *Remarks* in discussion on C. J. Cullingworth's specimen of large fibro-cystic myoma growing from the cervix uteri 11
—— —— in discussion on Leonard Remfry's paper on the effects of lactation on menstruation and impregnation . 27
—— —— in discussion on J. R. Morison's, Herbert R. Spencer's, and T. W. Eden's papers on deciduoma malignum 177
—— —— in discussion on C. Hubert Roberts's notes of a case of primary epithelioma of vagina . . . 384
—— *Report* of Committee 87
List of Officers elected for 1896 84
—— —— *for* 1897 v
—— *of past Presidents* vii
—— *of Referees of Papers for* 1897 . . . viii
—— *of Standing Committees* ix
—— *of Honorary Local Secretaries* . . . x
—— *of Honorary Fellows* xi
—— *of Corresponding Fellows* xii
—— *of Ordinary Fellows* xiii
—— *of Deceased Fellows* [with obituary notices, which see] 72—75

PAGE

Lungs, notes of a case of malignant disease of the uterus with numerous deposits in, and death following an abortion (John D. Malcolm) 125

MACLEAN (Dr. Ewen), *Remarks* in discussion on A. H. N. Lewers's paper on a case of double uterus with double hæmatometra and complete absence of the vagina . 341
Maieutic, simple, for the induction of miscarriage or premature labour (Peter Horrocks) 168
MALCOLM (John D.), large solid ovarian tumour (shown) . 167
—— notes of a case of malignant disease of the uterus with numerous deposits in the lungs, and death following an abortion 125
—— solid ovarian tumour (shown) . . . 167
—— two solid ovarian tumours (shown) . . . 166
—— *Remarks* in discussion on Alban Doran's specimen of cystic myoma of uterus weighing over fifteen pounds . 165
—— —— in discussion on John Phillips's paper on anterior colpotomy 220
Malformation in an anencephalic fœtus, completely cleft spine associated with an unusual visceral (Thomas G. Stevens) . 346
Maunsell, H. Widenham, A.M., M.D., of Kensington, obituary notice of 72
McCANN (Frederick J.), ætiology of gonorrhœa . . 225
—— *Remarks* in discussion on Leonard Remfry's paper on the effects of lactation on menstruation and impregnation . 27
Membranes, placenta, cord, fœtus, and (Robert Wise) . 166
Menstruation, effects of lactation on impregnation and (Leonard Remfry) 22
MEREDITH (W. A.), *Remarks* in discussion on Harrison Cripps's paper on abdominal hysterectomy with intra-peritoneal treatment of the stump, with notes of eight cases . 113
Miscarriage, see *Abortion*.
Mole removed by abdominal section, chorionic villi of a tubal (A. H. N. Lewers) 106
—— tubal (A. H. N. Lewers) 87
Mollities ossium, see *Osteomalacia*.
Monster, anencephalic, completely cleft spine associated with an unusual visceral malformation in (Thomas G. Stevens) 346
—— deformed fœtus with cystic tumour of neck (A. H. N. Lewers) 106

PAGE
Monster, fœtus diprosopus anencephalicus (Amand Routh) . 92
—— —— papyraceus (W. Rivers Pollock) . . . 320
—— skiagram of sireniform (Herbert Spencer) . . 118
Monstrosity resulting from amniotic adhesion to skull (John Phillips) 388
MORISON (J. Rutherford), a case of deciduoma malignum occurring in England 130
MORSE (Thomas H.), case of dermoid ovarian cyst impacted in the pelvis which was removed by abdominal section during the ninth month of pregnancy . . . 221
Myoma, cystic, of uterus weighing over fifteen pounds (Alban Doran) 164
—— large fibro-cystic, growing from the cervix uteri (C. J. Cullingworth) 8
Myxo-sarcoma of urethra in a child (A. L. Galabin) . . 120

NAPIER (Leith), *Report* of Committee . . . 32
—— solid tumours (shown) 29

Obituary notices of deceased Fellows:
Philps, George Philip, Kensington . . . 72
Maunsell, H. W., A.M., M.D., Kensington . . 72
Jones, John, of King Street, Regent Street . . 73
Chance, Edward John, F.R.C.S., Russell Square . 73
Thomas, Hugh, of Small Heath, near Birmingham . 73
James, James Prytherck, Eastleigh . . . 73
Betts, Frederick Bernard, L.R.C.P., Autofagasta . 73
Hodges, Richard, M.D., F.R.C.S., Camden Road . 74
Grove, William Richard, M.D., St. Ives . . 74
Kidd, George Hugh, M.D., F.R.C.S.I. (*Hon. Fellow*), Dublin 74
Osteomalacia, on the influence of the removal of the ovaries on metabolism in connection with (J. E. Curatulo) . 17
Ovarian cyst and hydrosalpinx removed by anterior colpotomy (Amand Routh) 185
—— —— dermoid impacted in the pelvis, which was removed by abdominal section during the ninth month of pregnancy (Thomas H. Morse) 221
—— ligament removed by operation, cases of fibroma of the ovary and (Alban Doran) 187

PAGE
Ovarian tumour containing corpus luteum (A. L. Galabin) . 101
—— —— large solid (John D. Malcolm) . . . 167
—— tumours, two solid (John D. Malcolm) . . 166
Ovaries, on the influence of the removal of, on metabolism in connection with osteomalacia (J. E. Curatulo) . . 17
Ovary, cases of fibroma of, and ovarian ligament removed by operation (Alban Doran) 187
Ovotestis occurring in man, true unilateral hermaphroditism with (G. F. Blacker and T. W. P. Lawrence) . . 265

Pelvis, dermoid ovarian cyst impacted in, which was removed by abdominal section during the ninth month of pregnancy (Thomas H. Morse) 221
PHILLIPS (John), anterior colpotomy . . . 213
—— monstrosity resulting from amniotic adhesion to skull (shown) 388
Philps, George Philip, of Kensington, obituary notice of . 72
Placenta and five months' fœtus, from a case of twin pregnancy in which the second child was delivered alive at or near full term along with the dead fœtus (G. G. Genge) . 5
—— cord, fœtus, and membranes (Robert Wise) . . 166
—— structure of the ripe, and the changes which occur in placentæ retained *in utero* after the death of the fœtus (T. W. Eden) 360
—— velamentosa and an abnormally large placenta (A. F. Stabb) 4
PLAYFAIR (W. S.), ruptured tubal gestation (shown) . 34
—— slough forming a complete cast of the vagina, from a case of enteric fever (shown) 33
—— unruptured tubal gestation (shown) . . . 36
POLLOCK (W. Rivers), fœtus papyraceus (shown) . . 320
Porro's operation with intra-peritoneal treatment of the stump, three cases of (H. R. Spencer) . . . 389
Pregnancy, dermoid ovarian cyst impacted in the pelvis which was removed by abdominal section during the ninth month of pregnancy (Thomas H. Morse) . . . 221
—— extra-uterine (A. L. Galabin) . . . 88
—— —— cast from the uterus having all the characters of the decidual membrane found in connection with, together with a small ovarian cyst from the same case, with microscopic sections of each (W. R. Dakin) . . . 385
—— —— not primarily tubal (A. L. Galabin) . . 91

PAGE

Pregnancy, five months' fœtus and placenta from a case of twin, in which the second child was delivered alive at or near full term along with the dead fœtus (G. G. Genge) . . 5
—— intra-ligamentous, retained for twenty-one years (A. L. Galabin) 38
—— ruptured tubal (W. S. Playfair) . . . 34
—— tubal, ruptured at the sixth week (A. L. Galabin) . 39
—— unruptured tubal (W. S. Playfair) . . . 36
Pyometra, cancerous uterus with (A. H. N. Lewers) . . 14

REMFRY (Leonard), effects of lactation on menstruation and impregnation 22
—— microscopical sections of uterus showing chorionic villi and doubtful sarcoma (shown) . . . 223
Report (audited) of the Treasurer for 1895 . . . 57
—— *of the Honorary Librarian for* 1895 . . . 58
—— *of the Chairman of the Board for the Examination of Midwives* 58
—— *of Committee on specimen of supposed tubo-ovarian cyst, shown by C. J. Cullingworth on December 4th*, 1895 ('*Transactions*,' vol. xxxvii, p. 295) . . . 4
—— *of Committee on specimen of solid ovarian tumour shown by Leith Napier on November 6th*, 1895 ('*Transactions*,' vol. xxxvii, p. 283) 32
—— *of Committee on A. H. N. Lewers's specimen which was shown as a tubal mole on March 6th*, 1895 ('*Transactions*,' vol. xxxvii, p. 78) 87
—— *of Committee on specimen of extra-uterine gestation shown by A. L. Galabin on February 5th*, 1896 . . 88
—— *of Committee on a specimen of fœtus diprosopus anencephalicus shown by Amand Routh on May 1st*, 1895 ('*Transactions*,' vol. xxxvii, p. 162) 92
—— *of Committee on J. Rutherford Morison's and Herbert R. Spencer's specimens of deciduoma malignum and J. D. Malcolm's specimen of sarcoma of the uterus, shown on April 1st*, 1896 183
—— *of Committee on specimen of tubo-ovarian abscess, shown by Walter Tate on October 7th*, 1896 . . . 380
Retractors, self-retaining glass (Macnaughton Jones) . 345
ROBERTS (C. Hubert), notes of a case of primary epithelioma of vagina 381

PAGE

ROBERTS (C. Hubert), *Remarks* in discussion on H. R. Spencer's paper on three cases of Porro's operation, with intra-peritoneal treatment of the stump 423
—— *Report* on Amand Routh's specimen of fœtus diprosopus anencephalicus 99
—— —— of Committee 380
ROBINSON (G. D.), *Remarks* in discussion on H. R. Spencer's paper on three cases of Porro's operation, with intra-peritoneal treatment of the stump 424
ROUTH (Amand), entirely detached uterine fibroid . . 388
—— fibroid tumour and cancer of the uterus (shown) . 99
—— hydrosalpinx and small ovarian cyst removed by anterior colpotomy (shown) 185
—— independent cancer of the body and of the cervix uteri (shown) 100
—— *Remarks* in discussion on J. E. Curatulo's paper on the influence of the removal of the ovaries on metabolism in connection with osteomalacia 20
—— —— in discussion on Leith Napier's specimen of solid tumours 31
—— —— on *report* of committee on specimen of extra-uterine gestation 90
—— *Report* on A. L. Galabin's specimen of extra-uterine gestation 90
—— —— in discussion on A. L. Galabin's specimen of extra-uterine fœtation not primarily tubal . . . 92
—— *Report* of Committee 92
—— *Remarks* in discussion on John Phillips's paper on anterior colpotomy 219
—— —— in discussion on A. H. N. Lewers's paper on a case of double uterus with double hæmatometra and complete absence of the vagina 337
—— —— in discussion on T. W. Eden's paper on the structure of the ripe placenta, and the changes which occur in placentæ retained *in utero* after the death of the fœtus . 376

Sarcoma, doubtful, microscopical sections of uterus showing chorionic villi and (Leonard Remfry) . . 223
—— of cervix uteri (A. L. Galabin) . . . 120
Skiagram of sireniform monster (Herbert Spencer) . . 118
Skull, monstrosity resulting from amniotic adhesion to (John Phillips) 388

PAGE

Slough forming a complete cast of the vagina, from a case of enteric fever (W. S. Playfair) 33
SMITH (Heywood), *Remarks* in discussion on C. J. Cullingworth's specimen of large fibro-cystic myoma growing from the cervix uteri 11
—— —— in discussion on A. L. Galabin's specimen of intra-ligamentous gestation retained for twenty-one years . 39
—— —— in discussion on J. Sidney Turner's specimen of hydronephrosis of the left kidney 105
Speculum (Herbert Spencer) 117
SPENCER (Herbert R.), case of deciduoma malignum . 135
—— *Remarks* in reply 181
—— skiagram of sireniform monster (shown) . . 118
—— speculum (shown) 117
—— three cases of Porro's operation, with intra-peritoneal treatment of the stump 389
—— *Remarks* in reply 424
—— *Report* on J. R. Morison's and Herbert R. Spencer's specimens of deciduoma malignum, and J. D. Malcolm's specimen of sarcoma of the uterus 184
—— *Remarks* in discussion on Alban Doran's paper on cases of fibroma of the ovary and ovarian ligament removed by operation 210
—— —— in discussion on A. H. N. Lewers's paper on a case of double uterus with double hæmatometra and complete absence of the vagina 339
Spine, completely cleft, associated with an unusual visceral malformation in an anencephalic fœtus (Thomas G. Stevens) 346
STABB (A. F.), for *W. S. A. Griffith*, placenta velamentosa and an abnormally large placenta 4
STEVENS (Thomas G.), case of completely cleft spine associated with an unusual visceral malformation in an anencephalic fœtus 346
—— *Remarks* in reply 359
SUTTON (J. Bland), *Report* on C. J. Cullingworth's specimen of supposed tubo-ovarian cyst 4
—— —— on Leith Napier's specimen of solid ovarian tumour 32
—— —— on A. H. N. Lewers's specimen of tubal mole . 87
—— —— of Committee 380
—— *Remarks* in discussion on J. R. Morison's, Herbert R. Spencer's, and T. W. Eden's papers on deciduoma malignum 178

PAGE

SUTTON (J. Bland), *Report* on J. R. Morison's and Herbert R. Spencer's specimens of deciduoma malignum, and J. D. Malcolm's specimen of sarcoma of the uterus . . 184
—— *Remarks* in discussion on W. Rivers Pollock's specimen of fœtus papyraceus 320

TARGETT (J. H.), *Report* on J. R. Morison's and Herbert R. Spencer's specimens of deciduoma malignum, and J. D. Malcolm's specimen of sarcoma of the uterus . . 184
—— nomination as auditor for 1896 . . . 379
TATE (Walter), tubo-ovarian abscess (shown) . . 319
—— *Report* of Committee 380
Thomas, Hugh, of Small Heath, Birmingham, obituary notice of 73
Tubo-ovarian abscess (Walter Tate) . . . 319
—— cysts, see *Cysts* (*tubo-ovarian*).
Tumour, cystic, of neck of uterus (A. H. N. Lewers). . 106
—— fibroid, and cancer of the uterus (Amand Routh) . 99
—— —— entirely detached uterine (Amand Routh) . 388
—— large solid ovarian (John D. Malcolm) . . 167
—— solid (Leith Napier) 29
—— solid ovarian (Leith Napier) 32
—— two solid ovarian (John D. Malcolm) . . . 166
—— uterine fibroid, associated with carcinoma (A. L. Galabin) 102
TURNER (J. Sidney), hydronephrosis of the left kidney (shown) 103

Umbilical cord, placenta, fœtus, and membranes (Robert Wise) 166
Urethra in a child, myxo-sarcoma of (A. L. Galabin) . 120
Uterus, cancerous, with pyometra (A. H. N. Lewers) . 14
—— case of double, with double hæmatometra and complete absence of the vagina (A. H. N. Lewers) . . 327
—— cast from, having all the characters of the decidual membrane found in connection with ectopic gestation, together with a small ovarian cyst from the same case, with microscopic sections of each (W. R. Dakin) . . . 385
—— cystic myoma of, weighing over fifteen pounds (Alban Doran) 164
—— cystic tumour of neck of (A. H. N. Lewers) . . 106
—— fibroid tumour and cancer of (Amand Routh) . . 99
—— independent cancer of the body and of the cervix (Amand Routh) 100
—— large fibro-cystic myoma growing from the cervix of (C. J. Cullingworth) 8

PAGE

Uterus, microscopic sections of tissue removed from (A. L. Galabin) 121
—— —— —— showing chorionic villi and doubtful sarcoma (Leonard Remfry) 223
—— multiple fibro-myomata of (C. J. Cullingworth) . 6
—— notes of a case of malignant disease of, with numerous deposits in the lungs, and death following an abortion (J. D. Malcolm) 125
—— sarcoma of cervix of (A. L. Galabin) . . . 120
—— tumours of, see *Tumours*.
—— two uteri removed by vaginal hysterectomy for cancer of the cervix, the disease being apparently at the same stage in each (A. H. N. Lewers) 164

Vagina, complete absence of, in a case of double uterus with double hæmatometra (A. H. N. Lewers) . . 327
—— primary epithelioma of (C. Hubert Roberts) . . 381
—— slough from a case of enteric fever, forming a complete cast of (W. S. Playfair) 33

WEBSTER (J. C.), *Remarks* in discussion on J. R. Morison's, Herbert R. Spencer's, and T. W. Eden's papers on deciduoma malignum 173
WISE (Robert), placenta, cord, fœtus, and membranes (shown) 166

OBSTETRICAL SOCIETY.

ADDITIONS TO THE LIBRARY

BY DONATION OR PURCHASE DURING THE YEAR 1896.

Presented by

AMANN (Josef Albert, jun.). Kurzgefasstes Lehrbuch der mikroscopisch-gynäkologischen Diagnostik. *illustrations*, 8vo. Wiesbaden, 1896 — Purchased.

AUDEBERT. See *Chaleix, Vivie, and Audebert.*

BARBOUR (A. H. F.). Supplement to the Atlas of the Anatomy of Labour, containing Plates XIII to XXVI, and completing with those previously published the third edition. *plates*, la. fol. Edinburgh — Dr. Barbour.

BARDELEBEN (Karl von). Handbuch der Anatomie des Menschen, Harn- und Geschlechtsorgane bearbeitet von Prof. Dr. J. Disse, Dr. Wilhelm Nagel, Prof. Dr. Eberth, und Prof. Dr. Holl. Zweiter Teil, Abteilung I. Die weiblichen Geschlectsorgane, von Dr. Med. Wilhelm Nagel. 8vo. Jena, 1896 — Purchased.

BOISLEUX (Ch.). Von der chronischen und akuten Pelviperitonitis und deren Behandlung ('Volkmann's Sammlung,' neue Folge, No. 167). 8vo. Leipzig, 1896 — Ditto.

BOUFFE DE ST. BLAISE (G.). Lésions anatomiques que l'on trouve dans l'éclampsie puerpérale. 8vo. Paris, 1891 — Ditto.

BUMM. See *Veit* (J.), Handbuch der Gynäkologie.

BURMEISTER (Th.). See *Ruge* (Carl), *Festschrift.*

	Presented by
Catalogue of Books added to the Radcliffe Library, Oxford University Museum, during the year 1895 4to. Oxford, 1896	Sir H. W. Acland, K.C.B.
CAZEAUX (P.). Traité théorique et pratique de l'art des accouchements. Dixième édition. Revue et annotée par S. Tarnier. 8vo. Paris	Purchased.
CAZENAVE (W.). Des tumeurs papillaires de l'Ovaire avec métastase péritonéale (considérations anatomo-pathologiques et opératoires). 8vo. Paris, 1895	Ditto.
CHALEIX-VIVIE et AUDEBERT. Traitement de l'Avortement incomplet. 8vo. Paris, 1896	Mr. Doran.
CHOLMOGOROFF (S. S.). Die Einführung von physiologischer Kochsalzlösung in den Organismus bei grossen Blutverlusten während und nach der Geburt. ('Volkmann's Sammlung,' neue Folge, No. 161.) 8vo. Leipzig, 1896	Purchased.
CHROBAK (R.) und A. v. ROSTHORN. Die Erkrankungen der weiblichen Geschlechtsorgane. Specielle Pathologie und Therapie herausgegeben von Hofrath Prof. Dr. Hermann Nothnagel, xx Band, I Theil, I Hälfte. *illustrations*, 8vo. Wien, 1896	Ditto.
CLEVELAND (W. F.). The Prophylactic Clothing of the Body chiefly in relation to Cold. 8vo. Lond., 1896	Author.
DOLÉRIS (J. A.) et R. PICHEVIN. Introduction à la pratique gynécologique. 1ier Fascicule. Inflammation de l'Appareil génital de la Femme. Pathologie et thérapeutique générales. *illustrations*, 8vo. Paris.	Purchased.
DÜHRSSEN (A.). Der vaginale Kaiserschnitt. (Nebst Bericht über eine erfolgreiche vaginale Exstirpation des rupturirten Uterus unmittelbar post-partum) *illustrations*, 8vo. Berlin, 1896	Ditto.
DUMITRESCU (Marie). Contribution à l'étude des absences congénitales du vagin considérées au point de vue chirurgical. 8vo. Paris, 1896	Ditto.
EDEN (T. W.). A Study of the Human Placenta, physiological and pathological. *Reprinted from* 'The Journal of Pathology and Bacteriology.' 8vo. Edin. and Lond., 1896	Author.
FLAISCHLEN (N.). See *Ruge* (Carl), *Festschrift*.	

Presented by

FOTHERGILL (W. E.). Manual of Midwifery. *illustrations*, 8vo. Edin. 1896 Purchased.

FROMMEL (Richard). See *Reports*, Jahresbericht.

GEBHARD (C.). See *Ruge* (Carl), *Festschrift*.

GESSNER (Adolf). See *Ruge* (Carl), *Festschrift*.

GRAEFE (Max). See *Ruge* (Carl), *Festschrift*.

HABERDA (Albin). Die fötalen Kreislaufwege des Neugeborenen und ihre Veränderungen nach der Geburt. In besonderer Rücksicht auf Bedeutung und Verwertung derselben bei gerichtsärztlichen Untersuchungen. *illustrations*, 8vo. Wien, 1895 Purchased.

HAMILTON (H.). *Smith* (L.).

HEUCK (Hans). See *Ruge* (Carl), *Festschrift*.

HUTTON (A. W.). The Vaccination Question, being the second issue of a letter addressed by permission in the autumn of 1894 to the Right Hon. H. H. Asquith, Q.C., M.P., at that time Home Secretary, together with a letter addressed by permission in the autumn of 1895 to the Right Hon. Arthur James Balfour, M.P., First Lord of the Treasury. sm. 8vo. Lond. 1895 Author.

ICARD (S.). La Femme pendant la Période menstruelle. Étude de Psychologie morbide et de Médecine légale. 8vo. Paris, 1890 Purchased.

JENNINGS (Samuel K.). The Married Lady's Companion, or Poor Man's Friend. 2nd edition, revised, corrected, and enlarged (imperfect, pp. 23—304). sm. 4to. New York, 1808 Dr. Allchin.

KLEINWÄCHTER (Ludwig). Zur Frage des Studiums der Medizin des Weibes. 8vo. Leipzig Author.

KLIEN (Rudolf). Die geburtshilfliche Bedeutung der Verengerungen des Beckenausganges insbesondere des Trichterbeckens. ('Volkmann's Sammlung,' neue Folge, No. 169.) 8vo. Leipzig, 1896 Purchased.

KNORR (Richard). See *Ruge* (Carl), *Festschrift*.

KOBLANCK (Alfred). See *Ruge* (Carl), *Festschrift*.

KÜSTNER (Otto). Die operative Behandlung der Retroversio-flexio uteri. ('Volkmann's Sammlung,' neue Folge, No. 171.) 8vo. Leipzig, 1896 Purchased.

Presented by

KÜSTNER (Otto). Ueber Indikationen und Kontraindikationen der Myomotomie. ('Volkmann's Sammlung,' neue Folge, No. 164.) 8vo. Leipzig, 1896 Purchased.

——— See *Veit* (J.). Handbuch der Gynäkologie.

LANDAU (Leopold) und THEODOR LANDAU. Die vaginale Radicaloperation. Technik und Geschichte. *illustrations*, 8vo. Berlin, 1896 Purchased.

——— (Theodor). See *Landau* (Leopold).

LE FORT (Léon). Œuvres publiées par le Dr. Félix Lejars. Tome premier. Hygiène hospitalière, Démographie. Hygiène publique. *illustrations*, la. 8vo. Paris, 1895 Purchased.

LOCKWOOD (C. B.). Traumatic Infection. Hunterian Lectures delivered at the Royal College of Surgeons of England. *illustrations*, 8vo. Edin. and Lond., 1896 Author.

LÖHLEIN. See *Veit* (J.). Handbuch der Gynäkologie.

MACKENRODT (A.). Ueber der hinteren Scheidenbauchschnitt. ('Volkmann's Sammlung,' neue Folge, No. 156). 8vo. Leipzig, 1896 Purchased.

MARTIN (August). Beiträge zur Geburtshülfe und Gynaekologie. Festschrift gewidmet August Martin zur Feier seines 25jährigen Doctorjubiluäm am 15 Juli, 1895 *illustrations*, Berlin, 1895 Ditto.

——— See *Ruge* (Carl), *Festschrift*.

MIRONOW (M. M.). De l'influence du système nerveux sur le fonctionnement des glandes mammaires. 4to. Kharkow, 1895 Mr. Doran.

MOERICKE (R.). See *Ruge* (Carl), *Festschrift*.

MÜLLER (P.). Ueber Behandlung des Abortus. ('Volkmann's Sammlung,' neue Folge, No. 153.) 8vo. Leipzig, 1896 Purchased.

MUNDÉ (Paul F.). *Reports*.

NAGEL (Wilhelm). *Bardeleben* (Karl von).

——— See *Veit* (J.). Handbuch der Gynäkologie.

NEUGEBAUER (F. L.). Zur Lehre von den angeborenen und erworbenen Verwachsungen und Verengerungen der Scheide sowie des angeborenen Scheidenmangels mit Ausschluss der Doppelbildungen. 8vo. Berlin, 1895 Purchased.

Presented by

Oaths (The Book of) and the severall forms thereof, both Antient and Modern. Faithfully collected out of Sundry Authentike Books and Records, not heretofore extant, compiled in one volume. Very useful for all persons whatsoever, especially those that undertake any Office of Magistracie or publique imployment in the Common-wealth. Whereunto is added a perfect Table. 12mo. Lond. 1649 Purchased.

PICHEVIN (R.). See *Doléris* (J. A.).

POZZI (Adrien). Manuel théorique et pratique d'Accouchements. *illustrations*, 8vo. Paris, 1897 Purchased.

POZZI (S.). Traité de Gynécologie clinique et opératoire. Troisième édition. *illustrations*, 8vo. Paris, 1897 Ditto.

RECKLINGHAUSEN (Friedrich von). Die Adenomyome und Cystadenome der Uterus, und Tubenwandung ihre Abkunft von Resten des Wolff'schen Körpers. *illustrations*, 8vo. Berlin, 1896 Ditto.

ROSTHORN (A. von). *Chrobak* (R.).

RUGE (Carl). Arbeiten aus dem Gebiete der Geburtshülfe und Gynäkologie zur Feier, der 25jährigen Thätigkeit als Assistent für mikroskopische und chemische Untersuchungen an der Berliner Universitäts-Frauenklinik von Professor Dr. Carl Ruge. *illustrations*, 4to. Berlin, 1896 Purchased.

SABOIA (Visconde de). Contribuições à Cirurgia contemporanea. 8vo. Paris and Lisbon, 1897 Author.

SARWEY (Otto). Die künstliche Frühgeburt bie Beckenenge. Auf grund von 60 Fällen aus der Kgl. Universitäts-Frauenklinik zu Tübingen. *illustrations*, 8vo. Berlin, 1896 Purchased.

SCHAEFFER (Oskar). Experimentelle Untersuchungen über die Wehenthätigkeit des menschlichen Uterus, ausgeführt mittelst einer neuen Pelotte und eines neuen Kymographion. *charts*, 8vo. Berlin, 1896 Ditto.

SCHAUTA (Freidrich). Lehrbuch der gesammten Gynäkologie, Lief. 7—12. *illustrations*, 8vo. Leipzig u. Wien, 1895 Ditto.

SCHICK (Richard). Die Myomotomie mit retroperitonealer Stielbehandlung ('Volkmann's Sammlung,' neue Folge, No. 158). 8vo. Leipzig, 1896 Ditto.

Presented by

SMITH (L.) and HAMILTON (H.). The International English and French Dictionary. New edition. 8vo. Paris, 1891 Purchased.

SUTTON (J. Bland). Surgical Diseases of the Ovaries and Fallopian Tubes, including Tubal Pregnancy. New and enlarged edition. *illustrations*, 8vo. Lond., 1896 Author.

THORN (W.). See *Ruge* (Carl), *Festschrift*.

VEIT (J.). Handbuch der Gynäkologie, in drei Bänden, herausgegeben von J. Veit. Erster Band. *illustrations*, 8vo. Wiesbaden, 1896 Purchased.

——— See *Ruge* (Carl), *Festschrift*.

VOLKMANN's Sammlung klinische Vorträge, neue Folge:

146. *Wyder*, Ueber Embolie der Lungenarterien in der geburtshilflich-gynäkologischen Praxis.
153. *Müller*, Ueber Behandlung des Abortus.
156. *Mackenrodt*, Ueber den hinteren Scheidenbauchschnitt.
158. *Schick*, Die Myomotomie mit retroperitonealer Stielbehandlung.
161. *Cholmogoroff*, Die Einführung von physiologischer Kochsalzlösung in den Organismus bei grossen Blutverlusten während und nach der Geburt.
164. *Küstner*, Ueber Indikationen und Kontraindikationen der Myomotomie.
167. *Boisleux*, Von der chronischen und akuten Pelviperitonitis und deren Behandlung.
169. *Klien*, Die geburtshilfliche Bedeutung der Verengerungen des Beckenausganges, insbesondere des Trichterbeckens.
171. *Küstner*, Die operative Behandlung der Retroversio-flexio uteri.

WALLICH (Victor). Recherches sur les vaisseaux lymphatiques sous-séreux de l'utérus gravide et non gravide. *illustrations*, 8vo. Paris, 1891 Purchased.

WEBSTER (J. Clarence). Practical and Operative Gynæcology. *illustrations*, 8vo. Edin. and Lond. 1896. Ditto.

WEST (Charles). The Profession of Medicine: its Study and Practice, its Duties and Rewards. sm. 8vo. Lond. 1896 Author.

WINTER (George). Lehrbuch der gynäkologischen Diagnostik. Unter Mitarbeitung von Dr. Carl Ruge. *illustrations*, 8vo. Leipzig, 1896 Purchased.

Presented by

WINTER (G.). See *Ruge* (Carl), *Festschrift.*

WYDER (Theodor). Ueber Embolie der Lungenarterien in der geburtshilflich-gynäkologischen Praxis ('Volkmann's Sammlung,' neue Folge, No. 146). 8vo. Leipzig, 1896 Purchased.

TRANSACTIONS.

AMERICAN ASSOCIATION OF OBSTETRICIANS AND GYNECOLOGISTS—
Transactions, vol. viii, for 1895. 8vo. Phila. 1896 Association.

AMERICAN GYNECOLOGICAL SOCIETY—
Transactions, vol. xx, for 1895. 8vo. Phila. 1895 Society.

BRITISH BALNEOLOGICAL AND CLIMATOLOGICAL SOCIETY—
Transactions for the year 1895-6. 8vo. Lond. 1896 Ditto.

CLINICAL SOCIETY OF LONDON—
Transactions, vol. xxix. 8vo. Lond. 1896 Ditto.

MEDICAL SOCIETY OF LONDON—
Transactions, vol. xix. 8vo. Lond. 1896 Ditto.

OBSTETRICAL SOCIETY (EDINBURGH)—
Transactions, Session 1895-6, with General Index to vols. i to xxi. 8vo. Edin. 1896 Ditto.

SOCIÉTÉ DE MÉDECINE DE ROUEN—
Bulletin. 2e Série, vol. ix. 34e Année, 1895 8vo. Rouen, 1896 Ditto.

SOCIÉTÉ DES SCIENCES MÉDICALES DE LYON—
Mémoires et Comptes-rendus. Tome xxxiv, 1894. 8vo. Lyons, 1895 Ditto.

JOURNALS.

	Presented by
Bristol (The) Medico-Chirurgical Journal. A journal of the medical sciences for the West of England and South Wales, published under the auspices of the Bristol Medico-Chirurgical Society. Vol. xii. 8vo. Bristol, 1894	Society.
Bulletin de l'Académie de Médecine, 3e série, tome xxxi. 8vo. Paris, 1894	Exchange.
Medical (The) Chronicle: a Monthly Record of the Progress of the Medical Sciences. Vols. i—xix. New Series, vols. i— , 1884— . 8vo. Manchester, 1884–96	Dr. Cullingworth.
Monatsschrift für Geburtshülfe und Gynäkologie. Band 1. 8vo. Berlin, 1895	Exchange.
Year-book of Treatment for 1896: a critical review for Practitioners of Medicine and Surgery. 8vo. Lond. 1896	Purchased.

REPORTS.

AMERICA—Johns Hopkins Hospital (The), Reports. Vol. v. 4to. Baltimore, 1895	Hospital Staff.
HOSPITALS — Thirty-fifth Annual Report of the Cincinnati Hospital to the Mayor of Cincinnati for the Fiscal Year ending December 31st, 1895. 8vo. Cincinnati, 1896	Ditto.
——— The Society of the New York Hospital; 125th Annual Report for the year 1895 8vo. New York, 1896	
——— A Report of the Gynecological Service of Mount Sinai Hospital, New York, for the Twelve Years from January 1st, 1883, to December 31st, 1894, by Paul F. Mundé. *illustrations*, 8vo. New York, 1895	Author.
——— King's College Hospital Reports; vol. ii, 1894–5. 8vo. Lond. 1896	Editors.
——— Middlesex Hospital Reports for 1894. 8vo. Lond. 1895	Hospital Staff.